# PREVALENCE OF MEDIAL MENISCAL TEARS WITH ARTHROSCOPIC ASSISTED TIBIAL PLATEAU LEVELING OSTEOTOMY

Stephen Kalff [1] BVSc MACVSc, Sarah Meachem [2] BSc PhD, Christopher Preston [1] BVSc DipACVS FACVSc

[1] *Pet Emergency and Specialist Centre, 1103 Dandenong rd, Malvern East, Victoria, 3145 Australia*

[2] *Department of Anatomy & Developmental Biology, Monash University, Victoria, 3168 Australia*

**Abstract**

**Objective:**

To determine the incidence of medial meniscal tears in dogs with naturally occurring cranial cruciate ligament (CCL) disease treated with arthroscopy and tibial plateau leveling osteotomy (TPLO).

**Study design:**

Retrospective case series

**Sample population:**

Canine Stifles (n=357) with naturally occurring CCL disease treated with arthroscopic assisted TPLO

**Methods:**

Medical records (November 2006 – November 2009) were reviewed for all dogs with CCL disease treated with arthroscopic CCL debridement, meniscal probing and TPLO. We investigated the significance of the preoperative variables; age, weight, tibial plateau angle (TPA), sex and the preoperative condition of the CCL on the incidence of concurrent meniscal tears (CMT) and late onset meniscal tears (LMT).

**Results:**

The prevalence of CMT and LMT was 32.2% and 5.6% respectively. A significant difference between age of those with CMT and those without was demonstrated. There was a significantly lower incidence of CMT and LMT in patients that presented with a partial CCL tear, compared with those that presented with a complete CCL tear. All patients with LMT treated with partial meniscectomy returned to peak postoperative limb function following partial meniscectomy (PMM) based on client assessed outcomes.

**Conclusions:**

The prevalence of LMT reported in this study demonstrates the importance of comprehensive meniscal assessment in stifles with CCL disease, and may add to the evidence against routinely performing meniscal release in TPLO patients. The preoperative condition of the CCL should be considered before operating on grossly normal menisci.

**Introduction:**

The canine medial meniscus is a crescent shaped fibrocartilagenous wedge that contributes to stifle joint congruity, stability and helps distribute femorotibial contact forces during load bearing[1-3].

Medial meniscal injuries are a common concurrent finding in canine stifles with cranial cruciate ligament (CCL) disease,[1,3-5] and have been shown to cause osteoarthritis and lameness.[1,3,6,7] The pathophysiology is thought to be shearing forces on the caudal horn of the medial meniscus caused by cranial subluxation and internal rotation of the tibia during loading of the CCL deficient stifle.[8-10] Though primary meniscal repair has been described in dogs,[11] it is not commonly performed and most tears are treated with partial or complete meniscectomy. Partial meniscectomy (PMM) aims to alleviate the pain associated with a meniscal tear, however it has been shown to reduce and alter meniscal function, and cause osteoarthritis.[12-15]

Medial meniscal tears following surgical treatment of CCL are significant complications, often causing acute deterioration in the operated limb and requiring additional surgery (PMM).[16-21] Reported incidences range up to 10.5% following tibial plateau leveling osteotomy (TPLO),[17,18] 21.7% following tibial tuberosity advancement (TTA),[19] 16.9% following tibial wedge ostectomy,[20] and 16.5% following extracapsular repair.[21]

Altered stifle biomechanics following surgery, such as caudal displacement of the femorotibial contact surface after TPLO,[10,13,22] may contribute to the pathophysiology of late onset meniscal tears (LMT). Additionally persistent instability following TPLO has been proposed as a possible mechanism for LMT.[4,16-18,23] Meniscal release, to free the caudal horn of the meniscus during subluxation of the medial femoral condyle, has been advocated to reduce the incidence of LMT.[24] However, it results in loss of meniscal function, an altered femorotibial contact relationship, [10,13,15,25] and can fail to prevent further meniscal pathology.[18] Failure to diagnose concurrent meniscal tears (CMT) during joint inspection at the initial surgery is also thought to falsely elevate to the incidence of those presenting with LMT.[16,18,23]

Accurate diagnosis of a medial meniscal tear is challenging. Non-invasive diagnostics such as orthopaedic examination, MRI, CT and ultrasound are not as reliable as in humans,[26-28] and the caudal horn of the medial

meniscus can be difficult to visualize during arthroscopy or arthrotomy. Arthroscopy provides illumination and magnification of joint structures and is currently regarded as the reference standard for canine stifle assessment.[4,23,26-29] In a cadaveric study the addition of meniscal probing to arthrotomy and arthroscopy increased the accuracy in diagnosing iatrogenic tears.[23] The effectiveness during arthrotomy was supported clinically by the low incidence of LMT reported by Fitzpatrick et al,[17] however, the effectiveness of meniscal probing during arthroscopy in naturally occurring canine CCL disease has not been reported.

The purpose of this study was to; (1) report the incidence of CMT in dogs with naturally occurring CCL disease during arthroscopic assessment and probing; (2) report the prevalence of LMT in the same dogs following treatment with TPLO; (3) to determine if the prevalence of CMT or LMT are influenced by preoperative factors including sex, age, weight, state the CCL (complete/partial tear) and tibial plateau angle (TPA).

**Materials and Methods:**

*Inclusion criteria:*

The medical records of all dogs (n=389) with naturally occurring CCL disease, excluding dogs that had had prior stifle surgery or concurrent stifle abnormalities, treated with a stifle arthroscopy and TPLO between November 2006 and November 2009 were reviewed. The age, weight, sex, presence of a palpable "meniscal click", TPA, the condition of the CCL and the presence of CMT or LMT were retrieved from the medical records. Partial CCL tears were defined as those with incomplete disruption of the CCL with no palpable stifle instability and complete CCL tears were those with disruption of all functional CCL fibers with palpable stifle instability. Definitive LMT were classified as tears diagnosed during a subsequent arthroscopic procedure, whereas suspected LMT were classified as those diagnosed through a combination of; a history acute deterioration of the operated limb; an orthopaedic examination that included pain on palpation of the medial aspect of the stifle, and/or the presence of a palpable or audible "click" during flexion and extension of the stifle; and the absence of other pathology. Follow-up client phone interviews were conducted in every case involved in the study. In cases with suspected LMT, the referring veterinarian was also interviewed. Only cases with complete data sets were analysed. One investigator performed all data collection.

*Surgical Techniques:*

One board certified surgeon, with extensive stifle arthroscopy experience, conducted all surgeries, preoperative examinations, orthogonal tibial radiographs and TPA measurements. Arthroscopy was performed in a standardized fashion as described by Whitney[30] using a 4.0 mm telescope. Visual examination and probing were used to categorize CCL pathology (complete / partial tear). The CCL remnants were debrided using a motorized arthroscopic shaver in all cases. Following debridement, the tibia was subluxated cranially, using the thumb (caudal aspect of the fibula) and index finger (cranial aspect of the patella) of a seated assistant, to improve visualization of the medial meniscus. Cranial traction was applied to the caudal horn of the medial meniscus after palpating its femoral and tibial surface with a right angle probe. A PMM was performed in all cases diagnosed with CMT, using a combination of a meniscotome, electrocautery and a motorized shaver. No procedures were performed on grossly intact menisci and no meniscal release procedures were performed.

All TPLO surgeries were performed in a standardized manner as described by Slocum et al[24] following stifle arthroscopy. Postoperative management was standardized for all patients. This included clinical examination at 10 days post surgery and orthogonal tibial radiographs at 6-week intervals. Restricted activity was recommended until radiographic evidence of osseous union at the osteotomy interface was evident. Arthroscopy and PMM were performed in all definitively diagnosed LMT.

*Statistical Analysis:*

All statistical analyses were performed using Sigmastat for Windows version 3.1 (Jandel Corporation, CA). Statistical significance was determined at $P<0.5$. Differences in age, weight and TPA were analysed using an unpaired T-test between dogs with CMT vs grossly normal menisci at the time of initial surgery and between CMT and LMT. A Chi Square test was performed to determine differences between sex and conditions of the CCL. All data are expressed as mean ± standard deviation (or coefficient index), unless otherwise stated, where number of dogs per group ranged between 5-357.

**Results:**

Complete data was available for 357 (92%) of cases. Complete CCL tears were recorded in 219 (61.3%) and 51% of the population was male. The mean age was 5.3 years (range: 0.6-14), body weight 32.2kg (range: 5-82), and TPA 27 degrees (range: 17-42). The mean follow up time for all cases was 691 days (range: 198-1302). There were 53 breeds represented in the study including; Golden Retrievers (42), Labradors (39), Rottweilers (32), and Mastiffs (18).

*CMT:*

CMT occurred in 115 (32.2%) cases, and a palpable "meniscal click" was present in 63% of those with CMT. A difference (P< 0.001) was observed between the incidence of CMT in stifles with complete CCL tears 104 (47.4% : C.I. 41-54) compared to those with partial CCL tears 11 (8% : C.I. 4-14). A difference was observed between the ages of the CMT population (mean 6.2 years) and the population with a grossly normal medial meniscus (mean 4.9 years). No differences were demonstrable after assessment of TPA, weight and sex. (Table 1.)

*LMT:*

LMT occurred in 20 (5.6%) of the total cohort, 14 (4%) of which were definitively diagnosed. A suspected LMT occurred in 6 cases, 4 that had complete CCL tears (including 1 that also had had a CMT), and 2 that had partial CCL tears. Median interval between initial surgery and diagnosis with LMT was 191 days (range 88–548) (Table 2.). Analysis of LMT variables excluded cases that had had CMT. No significant differences in sex, age, weight and TPA were demonstrated between the populations that sustained a LMT and those that had no meniscal pathology (CMT or LMT) (Table 3.). A difference (P=0.028) was demonstrated between the incidence of LMT in the partial CCL tear 5 (3.9% : C.I. 1-9) and the complete CCL tear 14 (13.9% : C.I. 7-20). The analysis was repeated after removal of cases with a suspect LMT, and the significance of the preoperative condition of the CCL was reproduced.

All patients with definitive LMT returned to peak postoperative limb function based on client assessed outcome.

**Discussion:**

This study sought to determine the incidences of; and the preoperative factors affecting CMT and LMT using the current reference standard for diagnosis of *in situ* meniscal pathology. The incidence of CMT and LMT were similar to previous reports. Within the preoperative variables assessed, age was found to influence the incidence of CMT, whereas the condition of the CCL influenced both the incidences of CMT and LMT. Complete data was available for 92% (357) of the original sample population of 389 stifles, which despite potential bias is excellent for follow-up in a retrospective study. To our knowledge this is the largest reported case series of arthroscopically assisted TPLO procedures performed by a single surgeon.

The prevalence of CMT and significance of the preoperative condition of the CCL on CMT were similar to that previously reported.[1,4,17,21] The higher incidence of CMT demonstrated in stifles with complete CCL tears, in accord with other reports,[3,17,21] maybe due to protection afforded to the meniscus by remaining functional cruciate fibres. (hulse) However, the 8% of CMT that occurred in palpably stable stifles questions how functional these fibres actually are. The development of a detailed grading system of CCL tears would allow for objective assessment of the functional integrity of partial CCL tears. Micro-instability causing meniscal pathology may be present in palpably stable stifles.

Surprisingly, the preoperative condition of the CCL also significantly influenced the incidence of LMT. A similar finding was reported by Metelman et al,[21] however in our study confounding variables were minimized as one surgeon performed the same procedures on all cases. Hence all stifles had the same meniscal assessment and the same post operative biomechanics. It would be reasonable to assume that if all CMT were diagnosed, the prevalence of LMT following TPLO in both groups would be similar. An explanation for the significant difference maybe the progression of meniscal pathology (not grossly apparent) sustained in an unstable stifle relative to that sustained in stable stifle. Jackson et al suggested that subtle histological lesions may be present in grossly normal menisci in cruciate deficient stifles, however no significant changes were detected between those with partial and complete CCL tears.[2] This is inconsistent with our findings, and the differences may be due the methodologies and limitations described by Jackson.[2] This warrants further investigation.

The rate of LMT following TPLO reported is significant. Though we cannot exclude failure to diagnose all CMT, the authors consider this unlikely. The median time to represent was consistent LMT presented …… current reference standard of diagnosis of gross meniscal pathology was performed in all cases.

Definitive diagnosis of LMT is not always possible due to multiple uncontrollable client variables such as compliance, outcome expectations, financial means and location. This may falsely reduce the reported incidence of LMT. Despite potential for bias, proactive follow-up of every patient and inclusion of suspected LMT (6/20) sought to address this issue. Exclusion of these cases resulted in a 3.9% (C.I. 2.2-6.5) incidence, which compared to other TPLO reports (where no suspected cases were included) was significantly less than arthrotomy with no probing (10.5%),[18] and similar to arthrotomy with probing (2.8%).[17] This demonstrates the importance of comprehensive meniscal examination during initial assessment.

PMM effectively prevented LMT in patients that presented with CMT (0.9%) and, similar to Case et al,[16] apparently resolved the lameness in those with definitive LMT. The rate of LMT and the ability to effectively treat it reported in this study, when compared with the potential limitations of meniscal release,[10,13,15,18,25] may question the justification for routinely performing meniscal release.

Within the variables assessed in this study, older patients were more likely to have CMT. This was not surprising and may be explained by reduced resistance to supra-physiological forces of an aging, and naturally degenerating meniscus.[31] Interestingly it did not appear to be a significant factor regarding the incidence of LMT. The lack of significance in this and other variables may have been due to the low number of LMT (n=20) included in this series.

This study was limited by its retrospective nature and the availability of patient data. The patient's perioperative body condition score and postoperative activity level were not recorded hence the authors cannot comment on these variables. The chronicity of the initial CCL pathology was also not recorded. It is likely that the duration of stifle instability has some influence the incidence and severity of meniscal pathology. Additionally follow-up TPA were not available in our study. This may be an important variable, as neutralization of cranial tibial subluxation may not have been achieved in cases that developed LMT.

However, this study and another[32] demonstrated no relationship between the preoperative TPA and the incidence CMT, thus it is also possible the postoperative TPA may be irrelevant. A well designed prospective study is warranted to determine the significance of these variables.

In conclusion the incidence of LMT reported in this study demonstrates the importance of comprehensive meniscal assessment in stifles with CCL disease, and may add to the evidence against routinely performing meniscal release in TPLO patients. The preoperative condition of the CCL should be considered before operating on grossly normal menisci.

## References


1. Flo GL: Meniscal injuries. Vet Clin North Am Small Anim Pract 23:831-843, 1993.
2. Jackson J, Vasseur PB, Griffey S, et al: Pathologic changes in grossly normal menisci in dogs with rupture of the cranial cruciate ligament. J Am Vet Med Assoc 218:1281-1284, 2001.
3. Bennett D, May C: Meniscal damage associated with cruciate disease in the dog. J Small Anim Pract 32:111-117, 1991.
4. Ralphs SC, Whitney WO: Arthroscopic evaluation of menisci in dogs with cranial cruciate ligament injuries: 100 cases (1999-2000). J Am Vet Med Assoc 221:1601-1604, 2002.
5. Pacchiana PD, Morris E, Gillings SL, et al: Surgical and postoperative complications associated with tibial plateau leveling osteotomy in dogs with cranial cruciate ligament rupture: 397 cases (1998-2001). J Am Vet Med Assoc 222:184-193, 2003.
6. Wyland DJ, Guilak F, Elliott DM, et al: Chondropathy after meniscal tear or partial meniscectomy in a canine model. J Orthop Res 20:996-1002, 2002.
7. Thieman KM, Pozzi A, Ling HY, et al: Contact mechanics of simulated meniscal tears in cadaveric canine stifles. Vet Surg 38:803-810, 2009.
8. Tashman S, Anderst W, Kolowich P, et al: Kinematics of the ACL-deficient canine knee during gait: serial changes over two years. J Orthop Res 22:931-941, 2004.
9. Papageorgiou CD, Gil JE, Kanamori A, et al: The biomechanical interdependence between the anterior cruciate ligament replacement graft and the medial meniscus. Am J Sports Med 29:226-231, 2001.
10. Pozzi A, Kowaleski MP, Apelt D, et al: Effect of medial meniscal release on tibial translation after tibial plateau leveling osteotomy. Vet Surg 35:486-494, 2006.
11. Thieman KM, Pozzi A, Ling HY, et al: Comparison of contact mechanics of three meniscal repair techniques and partial meniscectomy in cadaveric dog stifles. Vet Surg 39:355-362, 2010.
12. LeRoux MA, Arokoski J, Vail TP, et al: Simultaneous changes in the mechanical properties, quantitative collagen organization, and proteoglycan concentration of articular cartilage following canine meniscectomy. J Orthop Res 18:383-392, 2000.
13. Pozzi A, Litsky AS, Field J, et al: Pressure distributions on the medial tibial plateau after medial meniscal surgery and tibial plateau levelling osteotomy in dogs. Vet Comp Orthop Traumatol 21:8-14, 2008.
14. Johnson KA, Francis DJ, Manley PA, et al: Comparison of the effects of caudal pole hemi-meniscectomy and complete medial meniscectomy in the canine stifle joint. Am J Vet Res 65:1053-1060, 2004.
15. Pozzi A, Tonks CA, Ling HY: Femorotibial Contact Mechanics and Meniscal Strain after Serial Meniscectomy. Vet Surg, 2010.
16. Case JB, Hulse D, Kerwin SC, et al: Meniscal injury following initial cranial cruciate ligament stabilization surgery in 26 dogs (29 stifles). Vet Comp Orthop Traumatol 21:365-367, 2008.
17. Fitzpatrick N, Solano MA: Predictive Variables for Complications after TPLO with Stifle Inspection by Arthrotomy in 1000 Consecutive Dogs. Vet Surg, 2010.
18. Thieman KM, Tomlinson JL, Fox DB, et al: Effect of meniscal release on rate of subsequent meniscal tears and owner-assessed outcome in dogs with cruciate disease treated with tibial plateau leveling osteotomy. Vet Surg 35:705-710, 2006.
19. Lafaver S, Miller NA, Stubbs WP, et al: Tibial tuberosity advancement for stabilization of the canine cranial cruciate ligament-deficient stifle joint: surgical technique, early results, and complications in 101 dogs. Vet Surg 36:573-586, 2007.
20. Kuan S, Smith B, Black A: Tibial wedge ostectomy: complications of 300 surgical procedures. Aust Vet J 87:438-444, 2009.
21. Metelman LA, Schwarz PD, Salman M, et al: An Evaluation of three different cranial cruciate Ligament Surgical Stabilization Procedures As They relate to Postoperative Meniscal Injuries. Vet Comp Orthop Traumatol 8:118-123, 1995.
22. Kim SE, Pozzi A, Banks SA, et al: Effect of tibial plateau leveling osteotomy on femorotibial contact mechanics and stifle kinematics. Vet Surg 38:23-32, 2009.
23. Pozzi A, Hildreth BE, 3rd, Rajala-Schultz PJ: Comparison of arthroscopy and arthrotomy for diagnosis of medial meniscal pathology: an ex vivo study. Vet Surg 37:749-755, 2008.
24. Slocum B, Slocum TD: Tibial plateau leveling osteotomy for repair of cranial cruciate ligament rupture in the canine. Vet Clin North Am Small Anim Pract 23:777-795, 1993.
25. Pozzi A, Kim SE, Lewis DD: Effect of Transection of the Caudal Menisco-Tibial Ligament on Medial Femorotibial Contact Mechanics. Vet Surg, 2010.
26. Bottcher P, Bruhschwein A, Winkels P, et al: Value of Low-Field Magnetic Resonance Imaging in Diagnosing Meniscal Tears in the Canine Stifle: A Prospective Study Evaluating Sensitivity and Specificity in Naturally Occurring Cranial Cruciate Ligament Deficiency with Arthroscopy as the Gold Standard. Vet Surg, 2010.
27. Mahn MM, Cook JL, Cook CR, et al: Arthroscopic verification of ultrasonographic diagnosis of meniscal pathology in dogs. Vet Surg 34:318-323, 2005.
28. Tivers MS, Mahoney P, Corr SA: Canine stifle positive contrast computed tomography arthrography for assessment of caudal horn meniscal injury: a cadaver study. Vet Surg 37:269-277, 2008.
29. Hoelzler MG, Millis DL, Francis DA, et al: Results of arthroscopic versus open arthrotomy for surgical management of cranial cruciate ligament deficiency in dogs. Vet Surg 33:146-153, 2004.
30. Whitney WO: Arthroscopically assisted surgery of the stifle joint, in Beal BS, Hulse DA, Schulz KS, et al (eds): Small Animal Arthroscopy, Vol. Philadelphia, PA, Saunders, 2003, pp 120-130.
31. Kulkarni VV, Chand K: Pathological anatomy of the aging meniscus. Acta Orthop Scand 46:135-140, 1975.
32. Guastella DB, Fox DB, Cook JL: Tibial plateau angle in four common canine breeds with cranial cruciate ligament rupture, and its relationship to meniscal tears. Vet Comp Orthop Traumatol 21:125-128, 2008.

Table 1.

| Preoperative Variable | CMT | No CMT | Significance |
|---|---|---|---|
| Cases (n=357) | 115 (32%) | 242 (68%) | N/A |
| Male (n=182) v Female (n=175) | 52 (28.6%) v 63 (36%) | 130 (71.4%) v 112 (64%) | N/S |
| Age (years) [+] | 6.2 +/- 2.7[*] | 4.9 +/- 2.6[*] | P <0.01[*] |
| Weight (Kg) [+] | 32.8 +/- 14.5 | 33.4 +/- 15.9 | N/S |
| TPA (degrees) [+] | 27.4 +/- 4.4 | 28.2 +/- 4.5 | N/S |

Table 1. shows the differences in demographics and preoperative variables between the population with CMT and with a grossly normal meniscus.

[*] Note there was a significant difference between the ages of the two populations.

[+] mean +/- 1 SD

Table 2.

| Time (wks) | Frequency of LMT |
|---|---|
| 0-10 | |
| 10-20 | 5 |
| 20-30 | 7 |
| 30-40 | 2 |
| 40-50 | 3 |
| 50-60 | 1 |
| 60-70 | |
| 70-80 | 2 |

Table 3. shows the frequency of LMT with respect to the time following the initial surgery

Table 3.

| Preoperative Variable | LMT | No Meniscal Pathology | Significance |
|---|---|---|---|
| Cases (n=242) | 19 (7.9%) | 123 (92.1%) | N/A |
| Male (n=130) v Female (n=112) | 8 (6.6%) v 11 (10%) | 122 (93.4%) v 101 (90%) | N/S |
| Age (years) + | 4.9 +/- 2.2 | 4.9 +/- 2.6 | N/S |
| Weight (Kg) + | 36.7 +/- 10 | 33.4 +/- 16.3 | N/S |
| TPA (degrees) + | 28.7 +/- 3.6 | 28.2 +/- 4.6 | N/S |

Table 3. shows the differences in demographics and preoperative variables between the population with LMT and those that had no meniscal pathology (CMT or LMT).
No significant differences were demonstrated
+ mean +/- 1 SD

# Lateral patellar luxation in dogs: a retrospective study of 65 dogs

S. Kalff [1] BVSc MACVSc, S.J. Butterworth [2] MA VetMB CertVR DSAO, A. Miller [3] BVMS DSAO, B. Keeley [4] BVM&S CertSAS DipECVS, S. Baines [1] MA VetMB PhD CertVR CertSAS DipECVS DipClinOnc, W.M. McKee [1] BVMS MVS MACVSc DSAO

[1] *Willows Veterinary Referral Service, Solihull, United Kingdom;* [2] *Weighbridge Referral Centre, Swansea, United Kingdom;* [3] *Andrew Miller and Associates, Stirling, United Kingdom;* [4] *Northwest Surgeons, Cheshire, United Kingdom.*

**Objective:**

To report the signalment and clinical features of dogs with non-traumatic lateral patellar luxation and to report the complications and outcomes following surgery.

**Methods:**

A multicentre retrospective study was performed. Medical were reviewed and the signalment, clinical features and treatment of dogs presenting with lateral patellar luxation were recorded. In dogs treated surgically, outcome and complications were investigated.

**Results:**

Sixty five dogs (95 stifles) were included; 39 were male and median age at presentation was 10 months. Breeds were classified as small (n=6), medium (n=23), large (n=27) and giant (n=9). Lateral patellar luxation was classified as grade I (n=14), II (n=41), III (n=29) and IV (n=11). Conformational abnormalities were noted in 34 stifles; genu valgum was the most common (n=28). Higher-grade luxation was associated with a younger age at presentation (p=0.032) and genu valgum (p=0.01). Surgery was performed on 58 stifles, 22 of which sustained one or more complications; 16 complications were managed conservatively, 4 with implant removal and 6 with revision surgery. Surgeon-assessed outcome was good/excellent in 47 of 51 dogs available for review.

**Conclusions:**

Non-traumatic lateral patellar luxation is a disease of predominantly medium and large breed dogs. It has several similar clinical features and can be surgically treated in a similar manner to medial patellar luxation with similar types of complications and outcomes expected.

## Introduction:

Non-traumatic patellar luxation due to malalignment of the quadriceps mechanism is one of the most common canine orthopaedic conditions.(1-3) The aetiology of patellar luxation is not clear, although, given the reported breed predisposition and the high prevalence of bilateral disease, a heritable component of the pathogenesis is suspected.(4-7) Patellar luxation has been associated with many gross anatomical deformities including abnormal coxofemoral conformation, femoral condyle dysplasia and a shallow trochlear groove, together with angular and torsional deformities of the femur and tibia.(7-12)

Medial patellar luxation is the most commonly reported form of patellar luxation, and its clinical features, concomitant orthopaedic abnormalities and surgical treatments have been extensively described.(4, 6-8, 12) By contrast, lateral patellar luxation is uncommon with a reported incidence of between 5 and 13% of all patellar luxations.(4, 6, 7, 13)

Historically, lateral patellar luxation has been regarded as a disease of large and giant breed dogs.(4, 6, 9) It has also been suggested to be associated with genu valgum, hip dysplasia and patella baja.(9, 10, 14, 15) However, there is little literature specifically describing the clinical features and treatment of this condition.(4, 6, 9, 10)

The purpose of this study was to report the signalment, history and clinical features of dogs that were presented with non-traumatic lateral patellar luxation, and to report the complications and outcomes of those cases that were treated surgically.

## Materials and Methods:

The medical records of dogs that were presented to one of four veterinary referral centers (Willows Referral Service, Weighbridge Referral Centre, NorthWest Surgeons and Andy Miller and Associates) with lateral patellar luxation between November 1998 and April 2011 were reviewed. Dogs with a history of previous pelvic limb trauma or surgery were excluded from the study. Data retrieved included signalment, grade of patellar luxation, presence of unilateral or bilateral disease, duration of clinical signs, presence of concomitant stifle

disease, presence of grossly visible pelvic limb conformational abnormalities and the details and outcome of treatment.

The presence and type of conformational abnormalities were determined from the records of the initial physical examination, because standardised preoperative images were not available. Similar to previous studies,(4, 7) the affected breeds were divided into four categories according to Kennel Club standards (i.e. small, medium, large and giant breed dogs).(16) Patellar luxation was graded in severity on a scale of I-IV as previously described.(17)

In dogs that were treated surgically, the ratio of patellar tendon to patella length (PT:P), concomitant stifle abnormalities, the method of surgical treatment, complications and surgeon-assessed outcome were also evaluated. The PT:P was measured from non-luxated mediolateral stifle radiographs in accordance with a previously reported technique.(14)

Surgical procedures, when performed, were at the surgeon's discretion and with the full and informed consent of the owners. A craniomedial or craniolateral parapatellar arthrotomy was performed in all animals.(18) Surgical techniques included block or wedge recession sulcoplasty, tibial tuberosity transposition, lateral release, medial imbrication and distal femoral osteotomy. In dogs that had bilateral correction, the interval between the surgical procedures was dependent on postoperative limb function, wound healing and level of client perceived disability.

Follow-up data assessed included all re-examinations, treatments and recorded client communications by the attending surgeon. Postoperative complications were defined as those managed surgically or non-surgically. Surgical managed complications were then subcategorised as those cases in which revision surgery was performed or recommended to the owner, and those that had implant removal.

Surgeon-assessed outcomes were graded as excellent (no lameness), good (intermittent mild lameness), fair (moderate lameness) or poor (severe or non-weight bearing lameness) as previously described.(6, 8)

**Statistical analysis:**

All statistical analyses were performed using commercial softwear (Prism Graphpad software, Inc; La Jolla, USA). Data were reported as mean and standard deviation or median and range. Differences between measured variables were tested using Chi-square or Fisher's exact test for categorical variables and the Mann-Whitney U or Kruskal Wallis ANOVA for continuous variables. Statistical significance was set at $p<0.05$. All data were compared and assessed for significant associations.

**Results:**

Sixty five dogs with 95 limbs affected by lateral patellar luxation were included in the study. Thirty nine (60%) dogs were male (11 were neutered) and 26 (40%) were female (10 were neutered). The median age at presentation was 10 months (range 2.5-120 months),(Table 1) and the median weight was 19.9kg (range 1.75-56kg). Thirty two different breeds were identified. The commonly represented breeds included Cocker Spaniel (n=13), Flat Coat Retriever (n=5), Bassett Hound (n=4), Newfoundland (n=4) and Springer Spaniel (n=4). There were 23 other breeds which had three or fewer cases.(Appendix Table 1) The dogs were classified according to breed as small (n=6), medium (n=23), large (n=27) and Giant (n=9).

The median duration of clinical signs prior to presentation was 60 days (range 4-120 days). On examination 35 dogs had unilateral and 30 had bilateral lateral patellar luxation. Lateral patellar luxation was classified as being grade (14/95 stifles), grade II (41/95 stifles), grade III (29/95 stifles) and grade IV (11/95 stifles). Surgical correction was performed in 58/95 stifles with grade I (n=4), grade II (n=26), grade III (n=20) and grade IV (n=8) lateral patellar luxation. Dogs with higher-grade luxations were significantly more likely to be presented at a younger age than dogs with lower grade luxations ($p=0.032$). Of the bilaterally affected dogs, 24 had the same grade bilaterally whilst six had different grades in each limb. Combinations included grades I and II (n=3), grades I and III (n=1) and grades II and III (n=2). Eight bilaterally affected dogs that were presented with the complaint of unilateral lameness included three dogs with different grades in each limb.

Grossly visible pelvic limb conformational abnormalities were recorded in 34/95 stifles. These deformities included genu valgum (n=28), external rotation of the distal limb with a "cow hocked" appearance (n=5) and

hypoflexion of the hocks (n=2). Higher-grade of luxation was associated with the presence of visibly apparent conformational abnormality (P=0.04), particularly with the presence of genu valgum (p=0.01). (Table 1)

Hip dysplasia was diagnosed in 18 cases. The presence or absence of stifle osteoarthritis was recorded in 83/95 stifles. Thirty-nine were recorded to have evidence of osteoarthritis.

Corrective surgery was performed on 58/95 stifles. Fifty one of these stifles had a tibial tuberosity transposition 29 of which were augmented with a tension band wire. Femoral trochlear sulcoplasty was performed in 46/58 stifles by wedge recession (n=42) or block recession techniques (n=4). Medial imbrication was performed in 45/58 stifles and lateral release was performed in 20/58 stifles. Femoral osteotomies were performed to correct distal femoral valgus in 3/58 stifles. There were 15 different combinations of eight different procedures performed. The most commonly combination was tibial tuberosity transposition, wedge recession sulcoplasty and medial imbrication (35/58). Fifteen of these also had a tibial tuberosity tension band wire and 15 had a lateral release. Ten dogs had bilateral staged surgery. The median interval between surgical procedures was eight weeks (range 5-32 weeks).

Concomitant stifle abnormalities at the time of surgery were recorded in 14 of 58 stifles. These included abrasions or avulsion injuries of the origin of the long digital extensor tendon (n=8), dysplastic lateral femoral condyle (n=3), convex trochlear (n=3). No additional procedures were performed to treat the long digital extensor tendon injuries.

Suitable mediolateral stifle radiographs were available for evaluation for 33 dogs. The median PT:P was 1.76; the mean was 1.73 (range: 0.96-2.32, 95% CI 1.61-1.85).

Fifty seven of 58 stifles were available for post operative assessment with one case lost to follow-up. The median duration of clinical follow-up was 16 weeks (range 4-260 weeks). Twenty two of these stifles sustained one or more complication. Ten stifles had a complication that was managed surgically. These included 6 with revision surgery and 4 with implant removal. Multiple complications were recorded in three stifles; no stifle had

more than one surgical complication. There were 16 complications that were managed non-surgically. The types and frequencies of postoperative complications are listed in Table 2.

Recurrent lateral patellar luxation was the most common complication and occurred in six stifles; four of which had a revision surgery. Over correction leading to medial patellar luxation occurred in two stifles; one of which had a revision surgery. Three dogs with postoperative medial or lateral patellar luxation, that were treated conservatively, had subclinical grade 1 luxations and good or excellent outcomes. Tibial tuberosity avulsion fracture occurred in four cases and one had revision surgery. Other complications included wound break down and infection (n=5), implant loosening and failure (n=4), and seroma (n=5). One dog with wound infection and three dogs with implant loosening and failure had minor surgical procedures to remove the implants. Complications were more likely to occur in dogs with unilateral luxations (P=0.03), but were not associated with any other variable.

Surgeon assessed outcome was available for 51/58 stifles; seven stifles had incomplete data sets. Outcome was graded as being excellent (n=14), good (n=33) and fair (n=4). No dog was recorded as having a poor outcome. There were no significant associations between the outcome and any other variable.

**Discussion:**

In this study of a large series of cases suffering from lateral patellar luxation, there were several features that were similar to those reported for medial patellar luxation. This included the mean age at presentation, the ratio of unilateral to bilateral patellar luxation, and the distribution of grades.(4, 6, 7, 13) The male to female ratio was 1.5:1, which is similar to medial patellar luxation in some studies,(8, 13) but is different to others.(4, 6, 12) These similarities may reflect a common aetiopathogenesis.

Dogs with higher-grade luxations were presented at an earlier age, and were more likely to undergo surgical correction. Whilst the reason is unclear, intuitively this is not surprising; higher-grade luxations probably caused more obvious client perceived lameness and hence were more likely to generate a proactive treatment by the surgeon.

Lateral patellar luxation has previously been considered a disease of large and giant breed dogs.(4, 9) However, in the present study it was observed more frequently in medium and large breed dogs. Whilst this may reflect a changing demographic in our patient population, there is a paucity of previous population data on lateral patellar luxation with which to compare. The Cocker Spaniel was the most commonly affected breed in our study. Although our study design prevents a direct comment on breed predispositions, this finding is consistent with a previous report.(13) However, it should be noted that between the years 2000 and 2011 the Cocker Spaniel was consistently reported as the second most popular breed registered with the United Kingdom Kennel Club,(19) and breed popularity may in part explain the number of Cocker Spaniel dogs in the present study.

Genu valgum was present in 29% of affected stifles and was significantly associated with higher-grade luxations. As is the case in some dogs with high grade medial patellar luxation, it would be reasonable to presume that a proportion of these dogs also had femoral and or tibial deformities.(20, 21) Unfortunately, the lack of standardized preoperative imaging of the pelvic limbs prevented determining whether this was the case. It therefore remains uncertain if genu valgum reflects an underlying bone deformity that plays a role in the development of lateral patellar luxation, or if it is simply a posture adopted by the dog to compensate for patellar instability. Whilst future radiographic assessment of femoral deformity may be useful,(22, 23) CT assessment may be superior particularly in cases with multiplanar deformities or femoral condylar dysplasia.

Concomitant hip dysplasia has been associated with patellar luxation(5, 9) and was reported in 28% of our cases. Although patellar luxation and hip dysplasia may occur concurrently, a causative relationship between the two is contentious.(7, 10, 17) In the present study, the presence of hip dysplasia was not associated with any other variable including postoperative complications and outcome.

The PT:P ratio is used in people to assess patellar position and hence diagnose patella alta or baja; in people lateral patellar luxation is associated with patella alta.(24) Previous investigations of PT:P in dogs have demonstrated an association between medial patellar luxation and a high PT:P, which the authors suggested implied patella alta.(14, 25) No significant difference was demonstrated between control dogs (i.e. dogs without patellar luxation) and dogs with lateral patellar luxation. However, numbers of dogs with lateral patellar luxation were small (n=9) leading to possible type 2 error.(14) Whilst there was no control group in our study,

interestingly the mean and median PT:P in our study, 1.73 (95% CI 1.61-1.85), was lower than that of the control group, 2.02 (95% CI 1.97-2.06), reported in another study; this may suggest an association between a low PT:P and lateral patellar luxation.(14)

It should be noted that the PT:P fails to take into account variations in patient anatomy such as the extent of the trochlear groove, the proximity of the patellar tendon insertion to the tibial joint surfaces and the femorotibial standing angle. In our opinion, a low PT:P does not necessarily indicate patella baja but instead may represent normal anatomical variation between affected breeds. Further investigation is warranted.

Long digital extensor tendon abnormality was previously described in a case report in which it was suggested that chronic lateral luxation of the patella may lead to mechanical trauma to the long digital extensor tendon.(26) No treatment was required in our cases, and the presence of this abnormality was not associated with any other variable such as grade of luxation, nor did it appear to affect the incidence of postoperative complications or outcome.

Previous studies have suggested that dogs with lateral patellar luxation may be at higher risk for the development of complications than those with medial patellar luxation.(13) The incidence of postoperative complications in our study was higher than some other reports of medial patellar luxation (15-29%),(6, 8, 13) and similar to others (40-48%).(27, 28) However, given the large differences in study designs of these reports direct comparisons between cannot be made.

The types of postoperative complications in the present study were consistent with previous lateral and medial patellar luxation reports.(6, 8, 13, 28) Also in agreement with other studies, recurrent patellar luxation was the most common complication, occurring in 11% of cases.(6, 8, 13, 28) Though no significant risk factors were identified in our study, recurrent luxation suggests that there was an inadequate appreciation of the underlying pathological changes or that an inadequate corrective procedure had been performed. Uncorrected distal femoral varus has been reported to be associated with recurrent medial patellar luxation in dogs.(20) Therefore it seems reasonable to assume that distal femoral valgus may be associated with lateral patellar luxation.(15) Previous studies have also demonstrated a lower frequency of reluxation when a tibial tuberosity transposition and

sulcoplasty were performed.(8, 13) Whereas radiographic and CT assessment of distal femoral angular deformities have been described with reference angles suggested for preoperative planning of corrective femoral osteotomies,(20, 21, 23, 29) there is little in the veterinary literature to aid planning for tibial tuberosity transpositions or sulcoplasties. In people tibial tuberosity transpositions can be planned by measuring the quadriceps angle using standardised radiographs or by using CT overlay of the tibial tuberosity and the femoral condyles.(30) Though these techniques may be useful in dogs,(11) the variation in conformation and standing angle between dog breeds would make interpretation challenging. Additionally, although it has been suggested that sulcoplasties are performed to ensure that half of the patella is within the trochlear groove, there is little supportive evidence for this recommendation.(31)

Interestingly, the dogs with unilateral patellar luxations were more likely to sustain a complication. Given the absence of any other associations between unilateral patellar luxations and other studied variables, we suspect this is a type 1 error. No other significant risk factors for the development of any complication were identified. This is in contrast to previous studies that have reported significant associations between weight, grade of patellar luxation and surgical technique on the incidence of complications after patellar luxation surgery.(8, 13)

A good to excellent surgeon-assessed postoperative outcome was found in 92% of dogs. Though this is a subjective outcome measurement and therefore limits the conclusions that can be made, the result is similar to that reported following medial patellar luxation surgery (6, 8) and suggests that lateral patellar luxation surgery carries a similar prognosis.

The study was limited by its retrospective design. The use of recorded data relied on the accuracy and completeness of medical records. Variations between surgeons, such as patient assessment, choice of treatment, and management of complications, were unavoidable given the multicentre nature of the study. Though outcome measurements were subjective, given the absence of standardization of perioperative treatment, this limited information was considered sufficient for the purpose of this study. Future prospective cohort studies with standardized patient assessment and surgical treatments, postoperative management and objective outcome measurements may be helpful in describing treatment and outcome of lateral patellar luxation more accurately.

In conclusion, non-traumatic lateral patellar luxation was observed in all breed categories, but predominantly in medium and large breed dogs. It has several similar clinical features and can be surgically managed in a similar manner to medial patellar luxation with similar types of complications and outcomes expected.

1. Johnson JA, Austin C, Breur GJ. Incidence of canine appendicular musculoskeletal disorders in 16 veterinary teaching hospitals from 1980 through 1989. Vet Comp Orthop Traumatol. 1994;7:56-69.

2. Ness MG, Abercromby RH, May C, et al. A survey of orthopaedic conditions in small animal veterinary practice in Britain. Vet Comp Orthop Traumatol. 1996;9(2):43-52.

3. Ruble RP, Hird DW. Congenital abnormalities in immature dogs from a pet store: 253 cases (1987-1988). J Am Vet Med Assoc. 1993 Feb 15;202(4):633-6.

4. Hayes AG, Boudrieau RJ, Hungerford LL. Frequency and distribution of medial and lateral patellar luxation in dogs: 124 cases (1982-1992). J Am Vet Med Assoc. 1994 Sep 1;205(5):716-20.

5. LaFond E, Breur GJ, Austin CC. Breed susceptibility for developmental orthopedic diseases in dogs. J Am Anim Hosp Assoc. 2002 Sep-Oct;38(5):467-77.

6. Alam MR, Lee JI, Kang HS, et al. Frequency and distribution of patellar luxation in dogs. 134 cases (2000 to 2005). Vet Comp Orthop Traumatol. 2007;20(1):59-64.

7. Bound N, Zakai D, Butterworth SJ, et al. The prevalence of canine patellar luxation in three centres. Clinical features and radiographic evidence of limb deviation. Vet Comp Orthop Traumatol. 2009;22(1):32-7.

8. Gibbons SE, Macias C, Tonzing MA, et al. Patellar luxation in 70 large breed dogs. J Small Anim Pract. 2006 Jan;47(1):3-9.

9. Bojrab MJ. Pathophysiology in small animal surgery. Philadelphia: Lea & Febiger; 1981. p. 638-40.

10. Piermattei DL, Flo GL, DeCamp CE, Brinker WO. Brinker, Piermattei and Flo's handbook of small animal orthopedics and fracture repair. 4th ed. Edinburgh: Elsevier Saunders; 2006. p. 562-630.

11. Towle HA, Griffon DJ, Thomas MW, et al. Pre- and postoperative radiographic and computed tomographic evaluation of dogs with medial patellar luxation. Vet Surg. 2005 May-Jun;34(3):265-72.

12. Hulse DA. Pathophysiology and management of medial patellar luxation in the dog. Vet Med Small Anim Clin. 1981 Jan;76(1):43-51.

13. Arthurs GI, Langley-Hobbs SJ. Complications associated with corrective surgery for patellar luxation in 109 dogs. Vet Surg. 2006 Aug;35(6):559-66.

14. Mostafa AA, Griffon DJ, Thomas MW, et al. Proximodistal alignment of the canine patella: radiographic evaluation and association with medial and lateral patellar luxation. Vet Surg. 2008 Apr;37(3):201-11.

15. Witte PG, Scott HW. Treatment of lateral patellar luxation in a dog by femoral opening wedge osteotomy using an interlocking nail. Vet Rec. 2011 Mar 5;168(9):243.

16. http://www.the-kennel-club.org.uk/services/public/breed/Default.aspx.

17. Roush JK. Canine patellar luxation. Vet Clin North Am Small Anim Pract. 1993 Jul;23(4):855-68.

18. Piermattei DL, Johnson KA. An Atlas of Surgical Approaches to the Bones and Joints of Dogs and Cats. 4th ed. Philadelphia, Pa: Saunders; 2004.

19. http://www.thekennelclub.org.uk/item/887.

20. Roch SP, Gemmill TJ. Treatment of medial patellar luxation by femoral closing wedge ostectomy using a distal femoral plate in four dogs. J Small Anim Pract. 2008 Mar;49(3):152-8.

21. Swiderski JK, Palmer RH. Long-term outcome of distal femoral osteotomy for treatment of combined distal femoral varus and medial patellar luxation: 12 cases (1999-2004). J Am Vet Med Assoc. 2007 Oct 1;231(7):1070-5.

22. Dudley RM, Kowaleski MP, Drost WT, et al. Radiographic and computed tomographic determination of femoral varus and torsion in the dog. Vet Radiol Ultrasound. 2006 Oct-Nov;47(6):546-52.

23. Palmer RH, Ikuta CL, Cadmus JM. Comparison of femoral angulation measurement between radiographs and anatomic specimens across a broad range of varus conformations. Vet Surg. 2011 Dec;40(8):1023-8.

24. Insall J, Goldberg V, Salvati E. Recurrent dislocation and the high-riding patella. Clin Orthop Relat Res. 1972;88:67-9.

25. Johnson AL, Broaddus KD, Hauptman JG, et al. Vertical patellar position in large-breed dogs with clinically normal stifles and large-breed dogs with medial patellar luxation. Vet Surg. 2006 Jan;35(1):78-81.

26. Bardet JF, D.L. P. Long digital extensor and popliteal tenond avulsion associated with patellar luxation in a dog. J Am Vet Med Assoc. 1983;183(4):465-66.

27. Willauer CC, Vasseur PB. Clinical results of surgical correction of medial luxation of the patella in dogs. Vet Surg. 1987 Jan-Feb;16(1):31-6.

28. Linney WR, Hammer DL, Shott S. Surgical treatment of medial patellar luxation without femoral trochlear groove deepening procedures in dogs: 91 cases (1998-2009). J Am Vet Med Assoc. 2011 May 1;238(9):1168-72.

29. Swiderski JK, Radecki SV, Park RD, et al. Comparison of radiographic and anatomic femoral varus angle measurements in normal dogs. Vet Surg. 2008 Jan;37(1):43-8.

30. Beaconsfield T, Pintore E, Maffulli N, et al. Radiological measurements in patellofemoral disorders. A review. Clin Orthop Relat Res. 1994 Nov(308):18-28.

31. Slocum B, Devine T. Trochlear recession for correction of luxating patella in the dog. J Am Vet Med Assoc. 1985 Feb 15;186(4):365-9.

Table 1. Distribution of significant variables associated with grade of lateral patellar luxation

Dogs with higher grade luxations were more likely to present at a younger age (P=0.032), have a visual conformational abnormality (P=0.04) and have genu valgum (P=0.001).

| Grade of luxation | Stifles (n=) | Median Age (months) | Stifles with genu valgum (n=) |
|---|---|---|---|
| **I** | 14 | 16.5 | 3 |
| **II** | 41 | 12 | 3 |
| **III** | 29 | 7 | 17 |
| **IV** | 11 | 6 | 5 |
| **All** | 95 | 10 | 28 |

Table 2. Types and frequency of postoperative complications following LPL surgery.

| Complications | Frequency (n=) | Managed conservatively (n=) | Managed surgically (n=) |
|---|---|---|---|
| **MPL** | 2 | 1 | 1 |
| **LPL** | 6 | 2 | 4 |
| **Seroma** | 5 | 5 | 0 |
| **Wound problems** | 5 | 4 | 1 |
| **Implant failure** | 4 | 1 | 3 |
| **Tuberosity avulsion** | 4 | 3 | 1 |
| | | | |
| **Total** | 26 | 16 | 10 |

Appendix table 1. Breeds of dogs affected with lateral patellar luxation

| | **Frequency** |
|---|---|
| **Small Breed** | **6** |
| Lhasa Apso | 1 |
| Poodle Cross | 1 |
| Toy Poodle | 3 |
| Yorkshire Terrier | 1 |
| **Medium Breed** | **23** |
| Border Collie | 1 |
| Bulldog | 1 |
| Cocker spaniel | 13 |
| Scottish Terrier | 1 |
| Sheltie | 1 |
| Springer Spaniel | 4 |
| Whippet | 1 |
| Wire Haired Terrier | 1 |
| **Large Breed** | **27** |
| Clumber spaniel | 1 |
| Bassett Hound | 4 |
| cross breed | 2 |
| English Bull terrier | 1 |
| Flat Coated Retriever | 5 |
| Golden Retriever | 2 |
| Greyhound | 1 |
| Hungarian Vizsla | 1 |
| Irish setter | 1 |
| Labradoodle | 1 |
| Labrador Retriever | 2 |

| | |
|---|---|
| Northern Inuit | 2 |
| Sharpei | 1 |
| Siberian Husky | 2 |
| Standard Poodle | 1 |
| **Giant Breed** | **9** |
| Bernese Mountain Dog | 2 |
| Irish Wolf hound | 1 |
| Neapolitan Mastiff | 1 |
| Newfoundland | 4 |
| Scottish Deerhound | 1 |

# PROXIMAL FOCAL HUMERAL DEFICIENCY IN A LARGE BREED DOG

Stephen Kalff [1] BVSc MACVSc, Toby Gemmill [1] BVSc MVM DECVS DSAS(Orth)

[1] *Willows Veterinary Referral Service, Solihull, United Kingdom*

**Summary:**

A 26 week old female Boerboel was referred for evaluation of progressive left thoracic limb lameness. Computed tomography and radiographic evaluation revealed radiolucency of the caudal proximal humeral metaphysis, absence of the humeral head and gross distortion of the glenoid. Given the severe glenohumeral deformation, arthrodesis of the left shoulder was performed using biaxial plate and lag screw fixation. Despite late implant failure, arthrodesis was successful in this case, and satisfactory limb function was restored. To the author's knowledge, this is the first case of a focal developmental deficiency of the proximal humerus reported in the veterinary literature.

## Introduction

Defects of pre- or postnatal limb development can manifest as bone agenesis or dysplasia, and can be generalized or localized to individual bones or limbs. The aetiology is commonly hereditary, although teratogens, trauma, sporadic mutations and neoplasia are also possible. Individual bone agenesis, a form of meromelia, has been well documented in dogs and humans.(1-4) However, there is limited literature relating to agenesis or failure of development of segments of bone in the absence of other bone or systemic pathology.

Complete absence of the femoral head and neck has been reported as a form of proximal femoral focal deficiency (PFFD) in humans.(5) Although often localized to the affected limb, associated concurrent skeletal and systemic disorders have been reported.(6) A suspected case of PFFD has been reported in a young Doberman Pinscher.(7)To the authors' knowledge a similar disorder of the thoracic limb has not been reported in dogs, although focal agenesis of the carpus was reported in a cat.(1)

A case of marked humeral head deformity and apparent cranial bowing of the proximal humerus, described as shoulder dysplasia, was reported as part of a case series.(8) However, few details on the

case were available for review. Other failures of humeral head development have been reported in humans and dogs with multiple epiphyseal dysplasia (MED).(9-12) A form of osteochondral dysplasia, MED is a rare hereditary condition of people and dogs which is characterized by defective ossification of multiple long bone and occasionally vertebral epiphyses. To the authors' knowledge, focal proximal humeral epiphyseal aplasia has not been previously reported.

This report documents the clinical course and successful treatment of a dog with proximal focal humeral deficiency.

**Case Report**

A 26 week old female Boerboel was referred for evaluation of left thoracic limb lameness of 10 weeks' duration. The lameness had reportedly been acute in onset with no history of trauma, and had progressed despite restriction of activity to 10 minute lead walks and treatment with oral meloxicam[a] (0.1mg/kg PO SID). On examination, the dog exhibited a 3/10 left thoracic limb lameness. There was palpable distortion of the bony landmarks of the left shoulder. Mild discomfort and reduction in range of motion were also apparent. Clinical examination was otherwise unremarkable. Review of submitted radiographs (Fig. 1), obtained six weeks earlier, revealed radiolucency of the caudal proximal humeral metaphysis and apparent absence of the humeral head. The greater tubercle was misshapen and the proximal humeral physis grossly distorted. There was mild cranial bowing of the proximal humerus and the glenoid appeared flattened and dysplastic. Given the age of the patient and the relatively mild clinical signs, an additional period of continued conservative management was recommended.

On presentation 10 weeks later, the dog demonstrated a 4/10 left thoracic limb lameness. At rest she was unable to extend the shoulder and elbow sufficiently to fully bear weight on the limb. Mild proximal left thoracic limb muscle atrophy was noted. Although the range of motion of the left shoulder had decreased, no obvious discomfort was elicited during examination.

[a] Metacam: Boehringer Ingelheim UK Ltd, Bracknell, UK

Right and left thoracic limb computed tomography scans (CT)[b] were performed (Fig. 2). Marked derangement of the left glenohumeral joint was observed. The humeral head was absent and was replaced with a radiolucent defect extending across the caudal aspects of the physis, metaphysis and proximal diaphysis. Multiple mineralized bodies were evident throughout the radiolucent metaphyseal region. The cranial segment of the proximal humeral physis appeared normal. The greater tubercle was misshapen and there was marked cranial bowing of the proximal humerus. Marked remodeling of the glenoid was also apparent. The left radius and ulna were longer than their contralateral counterparts. Asymmetry of the thoracic limb muscles was noted with moderate atrophy on the left side. No obvious abnormalities were detected in the right thoracic limb. A fine needle aspirate of the left shoulder demonstrated no evidence of malignancy or infection.

Exploratory arthrotomy and salvage surgery by glenohumeral arthrodesis was performed four weeks later. A lateral approach was made to the left glenohumeral joint, incorporating acromial and **greater** tubercle osteotomies, and tenotomies of the teres minor and infraspinatus insertions.**(13)** The glenohumeral joint was luxated. Exuberant fibrous tissue was resected from the caudal aspect of the joint and samples were submitted for histopathology. Care was taken to identify and preserve the suprascapular nerve. Using an oscillating saw, ostectomies of the glenoid and the proximal humerus were performed to remove dysplastic tissue and to improve reduction and contact of the bone segments. The humerus was translated caudally to maximise bone contact. Autogenous cancellous bone graft, harvested from the ostectomised glenoid, and 3cc demineralised bone matrix (DBM)[c] were packed in and around the arthrodesis site. Interfragmentary compression was achieved with a 3.5mm self tapping screw directed craniodistal to caudoproximal placed in lag fashion. A cranial 3.5mm narrow locking compression plate[d] (LCP) was contoured and placed on the cranial aspect of the scapula and humerus, and secured with two cortical and three locking screws in the scapula, and six cortical screws in the humerus. A six hole 3.5mm String of Pearls locking plate[e] (SOP), secured with two proximal and two distal screws, was contoured and applied to the caudolateral scapula and humerus. The greater tubercle and acromial osteotomies were both reduced and stabilized with two

---

[b] Brightspeed: GE Healthcare, Little Chalfont, UK
[c] DBM, Veterinary Tissue Bank Ltd, Wrexham, UK
[d] Locking Compression Plate (LCP): Synthes Ltd, Hertfordshire, UK
[e] String of Pearls (SOP): Orthomed UK Ltd, Halifax, UK

pins and tension band wires. Soft tissues were closed routinely. Post operative craniocaudal and mediolateral radiographs (Fig. 3) demonstrated satisfactory limb alignment and implant position. The dog recovered from anaesthesia without complication and was discharged from hospital 24 hours following surgery. Meloxicam (0.1mg/kg PO SID) and cephalexin[f] (20mg/kg PO BID) were administered for five days. Additional analgesia was provided with a transdermal 100µg fentanyl[g] patch applied for 96 hours. The owners were instructed to restrict the dog's exercise to lead walks for toileting purposes only. Skin sutures were removed by the referring veterinarian without reported complications two weeks following surgery.

Histopathology of submitted samples revealed disorganized, poorly cellular fibrocartilagenous tissue in which plump spindle cells of uniform size were scattered throughout an abundant collagenous to myxoid matrix with multifocal chondroid metaplasia. Multifocal necrosis of the fibrous tissue with hyalinization of collagen fibers and areas of haemorrhage were also observed. These findings were consistent with dysplastic proliferative fibrocartilaginous tissue. There was no evidence of neoplasia or infection.

At the eight week postoperative recheck, moderate left thoracic limb lameness was evident, but limb function appeared improved compared with preoperatively. The shoulder was stable on manipulation and no discomfort was elicited. Due to financial constraints, sedation and radiographs were postponed.

Two weeks later the referring veterinarian reported an acute exacerbation of lameness following a fall. However, aside from moderate left thoracic limb lameness clinical examination was reportedly unremarkable. Radiographs performed by the referring veterinarian demonstrated progression of arthrodesis and no evidence of implant failure. Rapid clinical improvement was reported following restriction of activity and treatment with meloxicam (0.1mg/kg PO SID) and tramadol[h] (4mg/kg PO TID).

---

[f] Rilexine: Virbac Ltd, Burley St Edmunds, UK

[g] Durogesic: Janssen-Cilag, High Wicombe, Buckinghamshire, UK

[h] Tramadol: Bristol Laboratories Ltd, Berkhampsted, UK

At re-examination 24 weeks postoperatively subtle left thoracic limb lameness was evident. The left shoulder was palpably stable and discomfort was not apparent on manipulation. Radiographs demonstrated progression of arthrodesis (Fig. 4). The cranial LCP was broken, however, there was no other evidence of implant loosening or failure. A gradual return to normal activity over four weeks was recommended.

**Discussion:**

Although the aetiology and pathogenesis are unknown, the pathology described in this case represents a manifestation of a focal developmental failure of bone formation.

The thoracic and pelvic limbs develop from limb buds, which arise from cervicothoracic and lumbosacral regions of the embryo respectively. The limb buds consist of a mesenchymal core covered by cuboidal ectoderm. The thoracic limbs appear before the pelvic limbs. As the limb bud grows it becomes divided by constrictions into the manus, antebrachium and brachium, and the mesenchymal core differentiates and condenses to hyaline cartilage models of future bone. Skeletal elements form in a proximal to distal sequence within each limb; ie the scapula forms, then the humerus, and so forth. Towards the end of the embryonic period primary ossification centers appear in the middle of long bones and endochondral ossification progresses towards the proximal and distal ends of the cartilage models. The ends of each developing long bone (epiphyses) are separated from the ossifying diaphysis by cartilage plates (physes). Later, ossification centers arise at the epiphysis and endochondral ossification proceeds on both sides of the physis. Longitudinal bone growth is primarily due to endochondral ossification at the physes. When the bone has acquired its full length, the physes close and the epiphyses fuse with the diaphysis.(14)

The proximal, focal and unilateral nature of the pathology in this case is similar to that described for PFFD, albeit in the thoracic limb. In humans, PFFD is thought to result from either a neural crest injury or a defect in proliferation and maturation of chondrocytes in the proximal growth plate.(5) Although maternal use of thalidomide has been demonstrated to cause PFFD, other aetiologies including trauma, infection irradiation and ischaemia have also been implicated.(15) Concurrent abnormalities in other limbs are reported in up to 50% of people with PFFD.(6). No hereditary cause has been identified.

Failures of normal development of the humeral head are reported in MED and shoulder dysplasia.(8-11) MED is a heterogenous disease characterized by a delay or failure of epiphyseal endochondral ossification leading to an inability of articular cartilage to withstand normal cyclical loading. The severity of signs is variable and can also involve the metaphysis. Whilst the aetiology and pathogenesis of shoulder dysplasia have not been described, its phenotype is similar to MED. The case reported by Pucheu and others(8) may represent a focal failure of normal epiphyseal endochondral ossification, or could be a dog with MED where other epiphyses are subclinically affected.

As well as a deficiency of the epiphysis, this case also appeared to have failure of ossification of the caudal proximal metaphysis. This may have similarities to retained cartilaginous cores which have been reported in giant breed dogs affecting the distal ulna metaphysis.(16) Retained cartilaginous cores are thought to occur secondary to a failure of endochondral ossification and can be associated premature closure of the affected physis and subsequent antebrachial deformities.(16)

The lesion in this case appears to share some characteristics with PFFD, shoulder dysplasia, MED and retained cartilaginous core. Unfortunately the precise pathogenesis could not be determined; further studies of larger numbers of cases would be required to establish this.

The antebrachium of the affected limb was longer than the unaffected limb in this case. Compensatory overgrowth of the humerus and tibia have previously been described in dogs with antebrachial and femoral pathology respectively.(17-19) Though not previously reported in the ulna and radius, it would be reasonable to attribute the overgrowth seen in this case to a similar mechanism.

The severity of anatomical derangement in this case precluded reconstructive surgery. Due to the progression of clinical signs despite conservative management, salvage surgery was recommended. Total joint replacement using custom implants was considered. Hemiarthropasty of the shoulder has been previously reported in research dogs(20), but the long term success rates of shoulder replacements are unreported. Shoulder arthrodesis has previously been described with generally favourable clinical outcomes,(8, 21, 22) and this procedure was performed in this case. Given the size of the dog and her

boisterous nature, a second lateral SOP plate was applied to increase the construct's strength, stiffness and fatigue life. The mechanical failure of the cranial LCP noted at 24 weeks post operatively probably occurred secondary to fatigue. It is interesting to note that failure occurred at a point where the plate had been heavily contoured, presumably causing a focal weakness of the implant. It is possible that plate failure could have been avoided by the use of a 3.5mm broad implant; however this would have made contouring more challenging. The failure likely occurred late in the recovery period and did not affect outcome.

Harvesting the autogenous cancellous bone graft from the ostectomised glenoid removed any risk of donor site complications, and combining the autograft with DBM allowed expansion of the graft to fill a relatively large defect. Autogenous cancellous bone graft combined with DBM has been reported to be effective in aiding healing of arthrodesis and appears to be at least as efficacious as autogenous graft alone.(23, 24)

In conclusion, an unusual case of proximal focal humeral deficiency is reported. Stabilisation using biaxial plate and lag screw fixation was successful in providing stability to achieve shoulder arthrodesis. Despite late implant failure, arthrodesis was successful in this case, and satisfactory limb function was restored.

1. Gemmill TJ, Clarke SP, Carmichael S. Carpal agenesis in a domestic short haired cat. Vet Comp Orthop Traumatol. 2004;17(3):163-6.
2. James MA, McCarroll HR, Jr., Manske PR. The spectrum of radial longitudinal deficiency: a modified classification. J Hand Surg Am. 1999 Nov;24(6):1145-55.
3. O'Brien CR, Malik R, Nicoll RG. What is your diagnosis? Bilateral forelimb deformity and abnormal gait in a young Devon Rex. J Feline Med Surg. 2002 Jun;4(2):111-3.
4. Winterbottom EJ, Johnson KA, Francis DJ. Radial agenesis in a cat. J Small Anim Pract. 1985;26:393-8.
5. Boden SD, Fallon MD, Davidson R, et al. Proximal femoral focal deficiency. Evidence for a defect in proliferation and maturation of chondrocytes. J Bone Joint Surg Am. 1989 Sep;71(8):1119-29.
6. Grogan DP, Holt GR, Ogden JA. Talocalcaneal coalition in patients who have fibular hemimelia or proximal femoral focal deficiency. A comparison of the radiographic and pathological findings. J Bone Joint Surg Am. 1994 Sep;76(9):1363-70.
7. Salavati M. Proximal femoral focal deficiency (PFFD) in a young Doberman pinscher. J Small Anim Pract. 2008 Sep;49(9):486.
8. Pucheu B, Duhautois B. Surgical treatment of shoulder instability. A retrospective study on 76 cases (1993-2007). Vet Comp Orthop Traumatol. 2008;21(4):368-74.
9. Rasmussen PG. Multiple epiphyseal dysplasia in a litter of Beagle puppies. J Small Anim Pract. 1971 Feb;12(2):91-6.
10. Rorvik AM, Teige J, Ottesen N, et al. Clinical, radiographic, and pathologic abnormalities in dogs with multiple epiphyseal dysplasia: 19 cases (1991-2005). J Am Vet Med Assoc. 2008 Aug 15;233(4):600-6.
11. Ingram RR. The shoulder in multiple epiphyseal dysplasia. J Bone Joint Surg Br. 1991 Mar;73(2):277-9.
12. Briggs MD, Chapman KL. Pseudoachondroplasia and multiple epiphyseal dysplasia: mutation review, molecular interactions, and genotype to phenotype correlations. Hum Mutat. 2002 May;19(5):465-78.
**13. Piermattei DL, Johnson KA. An Atlas of Surgical Approaches to the Bones and Joints of Dogs and Cats. 4th ed. Philadelphia, Pa: Saunders; 2004. p.112-6**
14. Sadler TW, Langman J. Langman's Medical Embryology. 9th ed. Philadelphia, Pa.: Lippincott Williams & Wilkins; 2004. p. 181-92.
15. Epps CH, Jr. Proximal femoral focal deficiency. J Bone Joint Surg Am. 1983 Jul;65(6):867-70.
16. Johnson KA. Retardation of endochondral ossification at the distal ulnar growth plate in dogs. Aust Vet J. 1981 Oct;57(10):474-8.
17. Clements DN, Gemmill TJ, Clarke SP, et al. Compensatory humeral overgrowth associated with antebrachial shortening in six dogs. Vet Rec. 2004 Apr 24;154(17):531-2.
18. Schultz KS, Davidson E. Compensatory humeral overgrowth in a dog. Vet Comp Orthop Traumatol. 1999;12(2):92-6.
19. Schaefer SL, Johnson KA, O'Brien RT. Compensatory tibial overgrowth following healing of closed femoral fractures in young dogs. Vet Comp Orthop Traumatol. 1995;8:159-62.
20. Matsen FA, 3rd, Clark JM, Titelman RM, et al. Healing of reamed glenoid bone articulating with a metal humeral hemiarthroplasty: a canine model. J Orthop Res. 2005 Jan;23(1):18-26.
21. Edinger DT, Manley PA. Arthrodesis of the shoulder for synovial osteochondromatosis. J Small Anim Pract. 1998 Aug;39(8):397-400.
22. Vasseur PB. Arthrodesis for congenital luxation of the shoulder in a dog. J Am Vet Med Assoc. 1990 Aug 15;197(4):501-3.
23. Hoffer MJ, Griffon DJ, Schaeffer DJ, et al. Clinical applications of demineralized bone matrix: a retrospective and case-matched study of seventy-five dogs. Vet Surg. 2008 Oct;37(7):639-47.
24. Frenkel SR, Moskovich R, Spivak J, et al. Demineralized bone matrix. Enhancement of spinal fusion. Spine (Phila Pa 1976). 1993 Sep 15;18(12):1634-9.

Fig. 1
Mediolateral radiograph of the left shoulder obtained at the referring veterinary practice six weeks prior referral. Note the apparent absence of the humeral head distortion of the caudal aspect of the proximal humeral physis, radiolucency of the caudal proximal humeral metaphysis, and remodelling of the glenoid.

Fig. 2 Computed tomography scan (CT) of the left shoulder

A) Sagittal plane reconstruction of proximal left humerus showing absence of the humeral head and a radiolucent defect extending across physis into the caudal metaphysis. Note the multiple mineralised bodies within the defect.

B) 3d reconstructed image of the left proximal thoracic limb demonstrating the severe derangement of the glenohumeral joint and cranial bowing of the proximal humerus.

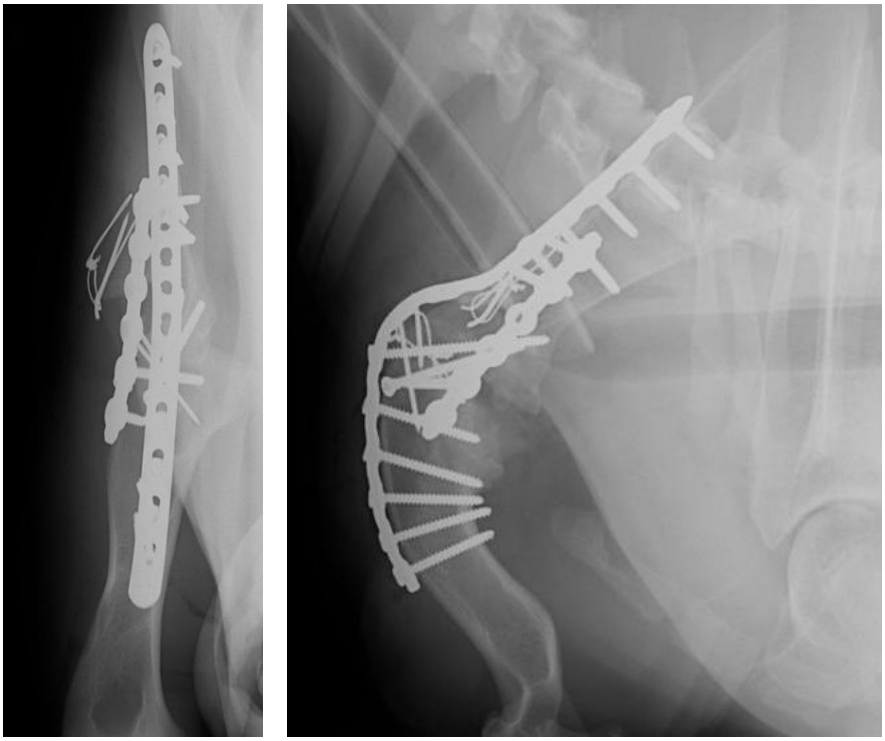

Fig. 3
Caudocranial (A) and Mediolateral (B) left shoulder radiographs demonstrating immediate postoperative implant position.

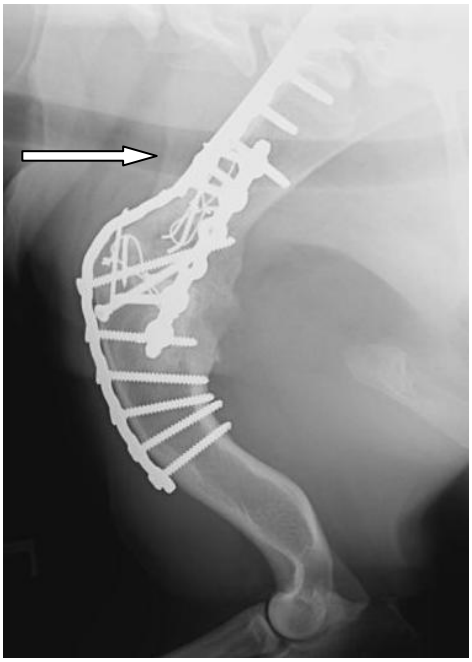

Fig. 4
Mediolateral radiograph of the left shoulder obtained 24 weeks postoperatively demonstrating good progression of arthodesis and failure of the LCP (white arrow)

# Incidence of Medial Meniscal Tears after Arthroscopic Assisted Tibial Plateau Leveling Osteotomy

Stephen Kalff[1], BVSc, MACVSc, Sarah Meachem[2], BSc, PhD, and Christopher Preston[1], BVSc Diplomate ACVS, FACVSc

[1]Pet Emergency and Specialist Centre, Malvern East, Australia and [2]Department of Anatomy & Developmental Biology, Monash University, Melbourne, Australia

**Corresponding Author**
Stephen Kalff, BVSc, MACVSc, Pet Emergency and Specialist Centre, 1103 Dandenong Rd, Malvern East, Victoria 3145 Australia.
E-mail: skalff@hotmail.com

Submitted July 2010
Accepted December 2010

DOI:10.1111/j.1532-950X.2011.00910.x

**Objective:** To determine the incidence of medial meniscal tears in dogs with naturally occurring cranial cruciate ligament (CCL) disease treated with arthroscopy and tibial plateau leveling osteotomy (TPLO).
**Study design:** Retrospective case series.
**Sample population:** Canine Stifles (n = 357) with naturally occurring CCL disease.
**Methods:** Medical records (November 2006–November 2009) were reviewed for all dogs with CCL disease treated with arthroscopic CCL debridement, meniscal probing, and TPLO. We investigated the significance of the preoperative variables; age, weight, tibial plateau angle (TPA), sex, and the preoperative condition of the CCL on the prevalence of concurrent meniscal tears (CMT) and incidence of late onset meniscal tears (LMT).
**Results:** Prevalence of CMT and incidence of LMT was 32.2% and 5.6%, respectively. A significant difference between age of dogs with and without CMT was identified. There was a significantly lower prevalence of CMT and incidence of LMT in dogs that had a partial CCL tear compared with those that had a complete CCL tear. All dogs with LMT treated by partial meniscectomy (PMM) returned to peak postoperative limb function after (PMM) based on client-assessed outcomes.
**Conclusions:** This study demonstrates the importance of LMT as a complication, the importance of comprehensive meniscal assessment, and may add to the evidence against routinely performing meniscal release in TPLO. The preoperative condition of the CCL should be considered before operating on grossly normal menisci.

The canine medial meniscus is a crescent shaped fibrocartilaginous wedge that contributes to stifle joint congruity, stability, and helps distribute femorotibial contact forces during load bearing.[1–3]

Medial meniscal injuries are a common concurrent finding in canine stifles with cranial cruciate ligament (CCL) disease[1,3–5] and have been shown to cause osteoarthritis and lameness.[1,3,6,7] Shearing forces on the caudal horn of the medial meniscus caused by cranial subluxation and internal rotation of the tibia during loading of the CCL deficient stifle are believed to contribute to tears.[8–10] Though primary meniscal repair has been described in dogs,[11] it is not commonly performed and most tears are treated with partial or complete meniscectomy. Partial meniscectomy (PMM) aims to alleviate the pain associated with a meniscal tear, however it has been shown to reduce and alter meniscal function, and cause osteoarthritis.[12–15]

Medial meniscal tears after surgical treatment of CCL are substantial complications, often causing acute deterioration in the operated limb and requiring additional surgery.[16–21] Reported incidences range up to 10.5% after tibial plateau leveling osteotomy (TPLO),[17,18] 21.7% after tibial tuberosity advancement (TTA),[19] 16.9% after tibial wedge ostectomy,[20] and 16.5% after extracapsular repair.[21]

Altered stifle biomechanics after surgery, such as caudal displacement of the femorotibial contact surface after TPLO,[10,13,22] may contribute to the pathophysiology of late onset meniscal tears (LMT). Additionally, persistent instability after TPLO has been proposed as a possible mechanism for LMT.[4,16–18,23] Meniscal release, to free the caudal horn of the meniscus during subluxation of the medial femoral condyle, has been recommended to reduce the incidence of LMT;[24] however it results in loss of meniscal function, an altered femorotibial contact relationship,[10,13,15,25] and can fail to prevent further meniscal pathology.[18]

The incidence of LMT may be falsely elevated by a failure to identify concurrent meniscal tears (CMT) during the original surgery.[16,18,23] Accurate diagnosis of a medial meniscal tear is challenging. Noninvasive diagnostics such as orthopedic examination, MRI, CT, and ultrasound are not as reliable as in people[26–28] and the caudal horn of the medial meniscus can be difficult to see during

arthroscopy or arthrotomy. Arthroscopy provides illumination and magnification of joint structures and is currently regarded as the reference standard for canine stifle assessment.[4,23,26–29] In a cadaveric study, the addition of meniscal probing to arthrotomy and arthroscopy increased the accuracy in diagnosing iatrogenic tears.[23] The effectiveness during arthrotomy was supported clinically by the low incidence of LMT reported by Fitzpatrick et al;[17] however, the effectiveness of meniscal probing during arthroscopy in naturally occurring canine CCL disease has not been reported.

Our purpose was to (1) report the prevalence of CMT in dogs with naturally occurring CCL disease during arthroscopic assessment and probing; (2) report the incidence of LMT in the same dogs after treatment with TPLO; and (3) determine if CMT or LMT are influenced by preoperative factors including sex, age, weight, state the CCL (complete/partial tear), and tibial plateau angle (TPA).

## MATERIALS AND METHODS

### *Inclusion Criteria*

Medical records of all dogs (n = 389) with naturally occurring CCL disease, excluding dogs that had had prior stifle surgery or concurrent stifle abnormalities, treated with a stifle arthroscopy and TPLO between November 2006 and November 2009 were reviewed. Age, weight, sex, presence of a palpable "meniscal click," TPA, the condition of the CCL, and the presence of CMT or LMT were retrieved from the medical records. Partial CCL tears were defined as those with incomplete disruption of the CCL with no palpable stifle instability and complete CCL tears were those with disruption of all functional CCL fibers with palpable stifle instability. Definitive LMT were classified as tears diagnosed during a subsequent arthroscopic procedure, whereas suspected LMT were classified as those diagnosed through a combination of: (1) a history of acute deterioration of the operated limb; (2) an orthopedic examination that included pain on palpation of the medial aspect of the stifle, and/or the presence of a palpable or audible "click" during flexion and extension of the stifle; and (3) the absence of other pathology. Follow-up client phone interviews were conducted in every case involved in the study. In cases with suspected LMT, the referring veterinarian was also interviewed. Only cases with complete data sets were analyzed. One investigator performed all data collection.

### *Surgical Techniques*

One board-certified surgeon, with extensive stifle arthroscopy experience, conducted all surgeries, preoperative examinations, orthogonal tibial radiographs, and TPA measurements. Arthroscopy was performed in a standardized fashion as described by Whitney[30] using a 4.0 mm telescope. Visual examination and probing were used to categorize CCL pathology (complete/partial tear). CCL remnants were debrided using a motorized arthroscopic shaver. After debridement, the tibia was subluxated cranially, using the thumb (caudal aspect of the fibula) and index finger (cranial aspect of the patella) of a seated assistant, to improve observation of the medial meniscus. Cranial traction was applied to the caudal horn of the medial meniscus after palpating its femoral and tibial surface with a right angle probe. A PMM was performed in all cases diagnosed with CMT, using a combination of a meniscotome, electrocautery, and a motorized shaver. No procedures were performed on grossly intact menisci and no meniscal release procedures were performed.

All TPLO surgeries were performed in a standardized manner as described by Slocum et al[24] after stifle arthroscopy. Postoperative management was standardized for all dogs. This included clinical examination 10 days after surgery and orthogonal tibial radiographs at 6-week intervals. Restricted activity was recommended until radiographic evidence of osseous union at the osteotomy interface was evident. Arthroscopy and PMM were performed in all definitively diagnosed LMT.

### *Statistical Analysis*

All statistical analyses were performed with software (Sigmastat for Windows version 3.1, Jandel Corporation, San Jose, CA). Statistical significance was determined at $P < .05$. Differences in age, weight, and TPA were analyzed using an unpaired t-test between dogs with CMT versus grossly normal menisci at initial surgery and between CMT and LMT. A $\chi^2$ test was performed to determine differences between sex and conditions of the CCL. All data are expressed as mean ± SD (or coefficient index), unless otherwise stated, where number of dogs per group ranged between 5 and 357.

## RESULTS

Complete data were available for 357 (92%) of dogs. Complete CCL tears were recorded in 219 (61.3%) dogs and 51% of the population was male. Mean age was 5.3 years (range, 0.6–14 years); body weight, 32.2kg (range, 5–82 kg), and TPA 27° (range,17–42°). Mean follow-up time was 691 days (range, 198–1302 days). There were 53 breeds represented including; Golden Retrievers (42), Labradors (39), Rottweilers (32), and Mastiffs (18).

### *CMT*

CMT occurred in 115 (32.2%) dogs, and a palpable "meniscal click" was present in 63% of those with CMT. A significant difference ($P < .001$) was observed between the prevalence of CMT in stifles with complete CCL tears 104 (47.4%, 95% CI: 41–54) compared to those with partial CCL tears 11 (8%, 95% CI: 4–14). A difference was observed between the ages of the CMT population (mean, 6.2 years) and the population with a grossly normal medial

**Table 1** Demographics and Preoperative Variables for Dogs with and without Concurrent Meniscal Tears (CMT)

| Preoperative Variable | CMT | No CMT | Significance |
|---|---|---|---|
| Cases (n = 357) | 115 (32%) | 242 (68%) | NA |
| Male (n = 182) | 52 (28.6%) | 130 (71.4%) | NS |
| Female (n = 175) | 63 (36%) | 112 (64%) | |
| Mean ± SD age (years) | 6.2 ± 2.7* | 4.9 ± 2.6* | $P < .01$ |
| Mean ± SD weight (kg) | 32.8 ± 14.5 | 33.4 ± 15.9 | NS |
| Mean ± SD TPA (°) | 27.4 ± 4.4 | 28.2 ± 4.5 | NS |

NS, not significantly different; NA, not applicable.

**Table 2** Frequency of Late Onset Meniscal Tears (LMT) with Respect to Time after Initial Surgery injury.

| | LMT | |
|---|---|---|
| Time (weeks) | Frequency | Percentage (%) |
| 0–9 | NA | NA |
| 10–19 | 5 | 25 |
| 20–29 | 7 | 35 |
| 30–39 | 2 | 10 |
| 40–49 | 3 | 15 |
| 50–59 | 1 | 5 |
| 60–69 | NA | NA |
| 70–79 | 2 | 10 |

Mean time to readmission was 231 days (Median, 191 days); NA, not applicable.

meniscus (mean, 4.9 years). No differences were demonstrable after assessment of TPA, weight, and sex (Table 1).

### *LMT*

LMT occurred in 20 (5.6%) of the total cohort, 14 (4%) of which were definitively diagnosed. Suspected LMT occurred in 6 dogs, 4 that had complete CCL tears (including 1 that also had had a CMT), and 2 that had partial CCL tears. Median interval between initial surgery and diagnosis with LMT was 191 days (range, 88–548 days; Table 2). Analysis of LMT variables excluded cases that had had CMT. No significant differences in sex, age, weight, and TPA were demonstrated between the populations that had LMT and those that had no meniscal pathology (CMT or LMT; Table 3). A difference ($P = .028$) was demonstrated between the incidence of LMT in the partial CCL tear 5 (3.9%, 95% CI: 1–9) and complete CCL tear 14 (13.9%, 95% CI: 7–20). The analysis was repeated after removal of cases with a suspect LMT, and the significance of the preoperative condition of the CCL was reproduced. All dogs with definitive LMT returned to peak postoperative limb function based on client assessed outcome.

## DISCUSSION

We sought to determine the prevalence of CMT and incidence of LMT, and the preoperative factors affecting them using the current reference standard for diagnosis of *in situ*

**Table 3** Demographics and Preoperative Variables of Dogs with Late Onset Meniscal Tears (LMT) and Those with No Meniscal Pathology (concurrent meniscal tears [CMT] or LMT)

| Preoperative Variable | LMT | No Meniscal Pathology | Significance |
|---|---|---|---|
| Cases (n = 242) | 19 (7.9%) | 123 (92.1%) | NA |
| Male (n = 130) vs. | 8 (6.6%) vs. | 122 (93.4%) vs. | NS |
| Female (n = 112) | 11 (10%) | 101 (90%) | |
| Mean ± SD age (years) | 4.9 ± 2.2 | 4.9 ± 2.6 | NS |
| Mean ± SD weight (kg) | 36.7 ± 10 | 33.4 ± 16.3 | NS |
| Mean ± SD TPA (°) | 28.7 ± 3.6 | 28.2 ± 4.6 | NS |

NS, not significantly different; NA, not applicable.

meniscal pathology. The rates of CMT and LMT were similar to previous reports. Within the preoperative variables assessed, age was found to influence the rate of CMT, whereas the condition of the CCL influenced both the prevalence of CMT and incidence of LMT. Complete data were available for 92% (357) of the original sample population of 389 stifles, which despite potential bias is excellent for follow-up in a retrospective study. To our knowledge, this is the largest reported case series of arthroscopically assisted TPLO procedures performed by a single surgeon.

The prevalence of CMT and significance of the preoperative condition of the CCL on CMT were similar to that previously reported.[1,4,17,21] The higher prevalence of CMT demonstrated in stifles with complete CCL tears, in accord with other reports,[3,17,21] maybe because of protection afforded to the meniscus by remaining functional cruciate fibers.[31] However, the 8% of CMT that occurred in palpably stable stifles questions how functional these fibers actually are. Development of a detailed grading system of canine CCL tears would allow for objective assessment of the functional integrity of partial CCL tears. Microinstability causing meniscal pathology may be present in palpably stable stifles.

Definitive diagnosis of LMT is not always possible because of multiple uncontrollable client variables such as compliance, outcome expectations, financial means, and location. This may falsely reduce the reported incidence of LMT. Despite potential for bias, proactive follow-up of every dog and inclusion of suspected LMT (6/20) sought to address this issue. Exclusion of these cases resulted in a 3.9% (95% CI: 2.2–6.5) incidence, which compared to other TPLO reports (where no suspected cases were included) was significantly less than arthrotomy with no probing (10.5%),[18] and similar to arthrotomy and meniscal release (5.3%)[18] and arthrotomy with probing (2.8%).[17] This demonstrates the importance of comprehensive meniscal examination during initial assessment.

Even with exclusion of the suspected cases, the rate of LMT after TPLO reported represents a substantial complication. Though we cannot exclude failure to diagnose all CMT, we consider this unlikely. The current reference standard for meniscal assessment was performed on every stifle and all dogs with LMT represented after an acute deterioration in the operated limb. Additionally, as

proposed by Case et al,[16] we contend that dogs with LMT would present earlier than the median time reported in our study (191 days). Alternative explanations may include, altered stifle biomechanics,[10,13,22] persistent stifle instability,[4,16–18,23] and/or progression of meniscal pathology not grossly or palpably apparent at time of the initial procedure.

Interestingly, the preoperative condition of the CCL also significantly influenced the incidence of LMT. A similar finding was reported by Metelman et al,[21] however, in our study confounding variables were minimized as one surgeon performed the same procedures on all dogs. Hence, all stifles had the same meniscal assessment and the same postoperative biomechanics. It would be reasonable to assume that if all CMT were diagnosed, the incidence of LMT after TPLO in both groups would be similar. An explanation for the significant difference maybe the progression of meniscal pathology (not grossly apparent) sustained in an unstable stifle relative to that sustained in a stable stifle. Jackson et al suggested that subtle histologic lesions may be present in grossly normal menisci in cruciate deficient stifles; however, no significant changes were detected between those with partial and complete CCL tears.[2] This is inconsistent with our findings, and the differences may be because of the methodologies and limitations described by Jackson et al.[2] This warrants further investigation.

PMM effectively prevented LMT in dogs that had CMT (0.9%) and, similar to Case et al,[16] apparently resolved the lameness in those with definitive LMT. The rate of LMT and the ability to effectively treat it reported in this study, when compared with the potential limitations of meniscal release,[10,13,15,25] may question the justification for routinely performing meniscal release.

Within the variables assessed in our study, older dogs were more likely to have CMT. This was not surprising and may be explained by reduced resistance to supraphysiological forces of an aging, and naturally degenerating meniscus.[32] Interestingly, it did not appear to be a significant factor regarding the incidence of LMT. The lack of significance in this and other variables may have been because of the low number of LMT (n = 20) included in this series.

This study was limited by its retrospective nature and several confounding variables. The dog's perioperative body condition score and postoperative activity level were not recorded, hence we cannot comment on these variables. The chronicity of the initial CCL pathology was also not recorded. It is likely that the duration of stifle instability has some influence on the incidence and severity of meniscal pathology. Additionally, follow-up TPA was not available. This may be an important variable, as neutralization of cranial tibial subluxation may not have been achieved in dogs that developed LMT. However, this study and another[33] demonstrated no relationship between the preoperative TPA and the prevalence CMT, thus it is also possible the postoperative TPA may be irrelevant. A well-designed prospective study is warranted to determine the significance of these variables.

Summarily, this study demonstrates the significance of LMT as a complication after TPLO, the importance of comprehensive meniscal assessment in stifles with CCL disease, and may add to the evidence against routinely performing meniscal release in TPLO dogs. The preoperative condition of the CCL should be considered before operating on grossly normal menisci.

## REFERENCES


1. Flo GL: Meniscal injuries. *Vet Clin North Am Small Anim Pract* 1993;23:831–843
2. Jackson J, Vasseur PB, Griffey S, et al: Pathologic changes in grossly normal menisci in dogs with rupture of the cranial cruciate ligament. *J Am Vet Med Assoc* 2001;218:1281–1284
3. Bennett D, May C: Meniscal damage associated with cruciate disease in the dog. *J Small Anim Pract* 1991;32:111–117
4. Ralphs SC, Whitney WO: Arthroscopic evaluation of menisci in dogs with cranial cruciate ligament injuries: 100 cases (1999-2000). *J Am Vet Med Assoc* 2002;221:1601–1604
5. Pacchiana PD, Morris E, Gillings SL, et al: Surgical and postoperative complications associated with tibial plateau leveling osteotomy in dogs with cranial cruciate ligament rupture: 397 cases (1998–2001). *J Am Vet Med Assoc* 2003;222:184–193
6. Wyland DJ, Guilak F, Elliott DM, et al: Chondropathy after meniscal tear or partial meniscectomy in a canine model. *J Orthop Res* 2002;20:996–1002
7. Thieman KM, Pozzi A, Ling HY, et al: Contact mechanics of simulated meniscal tears in cadaveric canine stifles. *Vet Surg* 2009;38:803–810
8. Tashman S, Anderst W, Kolowich P, et al: Kinematics of the ACL-deficient canine knee during gait: serial changes over two years. *J Orthop Res* 2004;22:931–941
9. Papageorgiou CD, Gil JE, Kanamori A, et al: The biomechanical interdependence between the anterior cruciate ligament replacement graft and the medial meniscus. *Am J Sports Med* 2001;29:226–231
10. Pozzi A, Kowaleski MP, Apelt D, et al: Effect of medial meniscal release on tibial translation after tibial plateau leveling osteotomy. *Vet Surg* 2006;35:486–494
11. Thieman KM, Pozzi A, Ling HY, et al: Comparison of contact mechanics of three meniscal repair techniques and partial meniscectomy in cadaveric dog stifles. *Vet Surg* 2010;39:355–362
12. LeRoux MA, Arokoski J, Vail TP, et al: Simultaneous changes in the mechanical properties, quantitative collagen organization, and proteoglycan concentration of articular cartilage following canine meniscectomy. *J Orthop Res* 2000;18:383–392
13. Pozzi A, Litsky AS, Field J, et al: Pressure distributions on the medial tibial plateau after medial meniscal surgery and tibial plateau levelling osteotomy in dogs. *Vet Comp Orthop Traumatol* 2008;21:8–14
14. Johnson KA, Francis DJ, Manley PA, et al: Comparison of the effects of caudal pole hemi-meniscectomy and complete

medial meniscectomy in the canine stifle joint. *Am J Vet Res* 2004;65:1053–1060

15. Pozzi A, Tonks CA, Ling HY: Femorotibial contact mechanics and meniscal strain after serial meniscectomy. *Vet Surg* 2010;39:482–488
16. Case JB, Hulse D, Kerwin SC, et al: Meniscal injury following initial cranial cruciate ligament stabilization surgery in 26 dogs (29 stifles). *Vet Comp Orthop Traumatol* 2008;21:365–367
17. Fitzpatrick N, Solano MA: Predictive variables for complications after TPLO with stifle inspection by arthrotomy in 1000 consecutive dogs. *Vet Surg* 2010;39:460–74
18. Thieman KM, Tomlinson JL, Fox DB, et al: Effect of meniscal release on rate of subsequent meniscal tears and owner-assessed outcome in dogs with cruciate disease treated with tibial plateau leveling osteotomy. *Vet Surg* 2006;35:705–710
19. Lafaver S, Miller NA, Stubbs WP, et al: Tibial tuberosity advancement for stabilization of the canine cranial cruciate ligament-deficient stifle joint: surgical technique, early results, and complications in 101 dogs. *Vet Surg* 2007;36:573–586
20. Kuan S, Smith B, Black A: Tibial wedge ostectomy: complications of 300 surgical procedures. *Aust Vet J* 2009;87:438–444
21. Metelman LA, Schwarz PD, Salman M, et al: An evaluation of three different cranial cruciate ligament surgical stabilization procedures as they relate to postoperative meniscal injuries. *Vet Comp Orthop Traumatol* 1995;8:118–123
22. Kim SE, Pozzi A, Banks SA, et al: Effect of tibial plateau leveling osteotomy on femorotibial contact mechanics and stifle kinematics. *Vet Surg* 2009;38:23–32
23. Pozzi A, Hildreth BE, , Rajala-Schultz PJ: Comparison of arthroscopy and arthrotomy for diagnosis of medial meniscal pathology: an ex vivo study. *Vet Surg* 2008;37:749–755
24. Slocum B, Slocum TD: Tibial plateau leveling osteotomy for repair of cranial cruciate ligament rupture in the canine. *Vet Clin North Am Small Anim Pract* 1993;23:777–795
25. Pozzi A, Kim SE, Lewis DD: Effect of transection of the Caudal Menisco-Tibial ligament on medial femorotibial contact mechanics. *Vet Surg* 2010;39:489–495
26. Bottcher P, Bruhschwein A, Winkels P, et al: Value of low-field magnetic resonance imaging in diagnosing meniscal tears in the canine stifle: a prospective study evaluating sensitivity and specificity in naturally occurring cranial cruciate ligament deficiency with arthroscopy as the gold standard. *Vet Surg* 2010;39:296–305
27. Mahn MM, Cook JL, Cook CR, et al: Arthroscopic verification of ultrasonographic diagnosis of meniscal pathology in dogs. *Vet Surg* 2005;34:318–323
28. Tivers MS, Mahoney P, Corr SA: Canine stifle positive contrast computed tomography arthrography for assessment of caudal horn meniscal injury: a cadaver study. *Vet Surg* 2008;37:269–277
29. Hoelzler MG, Millis DL, Francis DA, et al: Results of arthroscopic versus open arthrotomy for surgical management of cranial cruciate ligament deficiency in dogs. *Vet Surg* 2004;33:146–153
30. Whitney WO: Arthroscopically assisted surgery of the stifle joint, in Beal BS, Hulse DA, Schulz KS, et al (eds): *Small Animal Arthroscopy*, Philadelphia, PA, Saunders, 2003, pp 120–130.
31. Hulse D, Beale B, Kerwin S: Second look arthroscopic findings after tibial plateau leveling osteotomy, *Vet Surg* 2010;39:350–354
32. Kulkarni VV, Chand K: Pathological anatomy of the aging meniscus. *Acta Orthop Scand* 1975;46:135–140
33. Guastella DB, Fox DB, Cook JL: Tibial plateau angle in four common canine breeds with cranial cruciate ligament rupture, and its relationship to meniscal tears. *Vet Comp Orthop Traumatol* 2008;21:125–128

# Lateral patellar luxation in dogs: a retrospective study of 65 dogs

**S. Kalff[1]; S. J. Butterworth[2]; A. Miller[3]; B. Keeley[4]; S. Baines[1]; W. M. McKee[1]**

[1]Willows Veterinary Referral Service, Solihull, United Kingdom; [2]Weighbridge Referral Centre, Swansea, United Kingdom; [3]Andrew Miller and Associates, Stirling, United Kingdom; [4]Northwest Surgeons, Cheshire, United Kingdom

**Keywords**
Patellar, luxation, dog, lateral

**Summary**

**Objective:** To report the signalment and clinical features of dogs with non-traumatic lateral patellar luxation and to report the complications and outcomes following surgery.

**Methods:** A multicentre retrospective study was performed. Medical records were reviewed and the signalment, clinical features, and treatment of dogs presenting with lateral patellar luxation were recorded. In dogs treated surgically, the outcome and complications were investigated.

**Results:** Sixty-five dogs (95 stifles) were included; 39 were male and median age at presentation was 10 months. Breeds were classified as small (n = 6), medium (n = 23), large (n = 27), and giant (n = 9). Lateral patellar luxation was classified as grade I (n = 14), II (n = 41), III (n = 29), and IV (n = 11). Conformational abnormalities were noted in 34 stifles; genu valgum was the most common (n = 28). Higher-grade luxation was associated with a younger age at presentation (p = 0.032) and genu valgum (p = 0.01). Surgery was performed on 58 stifles, 22 of which sustained one or more complications; 16 complications were managed conservatively, four with implant removal and six with revision surgery. Surgeon-assessed outcome was good or excellent in 47 of the 51 dogs available for review.

**Conclusions:** Non-traumatic lateral patellar luxation is a disease of predominantly medium and large breed dogs. It has several similar clinical features and can be surgically treated in a similar manner to medial patellar luxation with similar types of complications and outcomes expected.

**Correspondence to:**
Stephen Kalff, BVSc MACVSc MRCVS
Willows Referral Service
Highlands Road
Shirley, Solihull B90 4NH
United Kingdom
Phone: +44 121 712 7070
Fax: +44 121 712 7077
E-mail: skalff@hotmail.com

**Vet Comp Orthop Traumatol 2014; 27: ••–••**
**doi:10.3415/VCOT-13-05-0064**
Received: May 18, 2013
Accepted: November 20, 2013
Pre-published online: January 20, 2014

## Introduction

Non-traumatic patellar luxation due to malalignment of the quadriceps mechanism is one of the most common canine orthopaedic conditions (1–3). The aetiology of patellar luxation is not clear, although, given the reported breed predisposition and the high prevalence of bilateral disease, a heritable component of the pathogenesis is suspected (4–7). Patellar luxation has been associated with many gross anatomical deformities including abnormal coxofemoral conformation, femoral condyle dysplasia and a shallow trochlear groove, together with angular and torsional deformities of the femur and tibia (7–12).

Medial patellar luxation is the most commonly reported form of patellar luxation, and its clinical features, concomitant orthopaedic abnormalities, and surgical treatments have been extensively described (4, 6–8, 12). By contrast, lateral patellar luxation is uncommon with a reported incidence of between five and 13% of all patellar luxations (4, 6, 7, 13).

Historically, lateral patellar luxation has been regarded as a disease of large and giant breed dogs (4, 6, 9). It has also been suggested to be associated with genu valgum, hip dysplasia, and patella baja (9, 10, 14, 15). However, to the best of our knowledge, there is little literature available that specifically describes the clinical features and treatment of this condition (4, 6, 9, 10).

The purpose of this study was to report the signalment, history and clinical features of dogs that were presented with non-traumatic lateral patellar luxation, and to report the complications and outcomes of those cases that were treated surgically.

## Materials and methods

The medical records of dogs that were presented to one of four veterinary referral centres (Willows Referral Service, Weighbridge Referral Centre, NorthWest Surgeons and Andy Miller and Associates) with lateral patellar luxation between November 1998 and April 2011 were reviewed. Dogs with a history of previous pelvic limb trauma or surgery were excluded from the study. Data retrieved included signalment, grade of patellar luxation, presence of unilateral or bilateral disease, duration of clinical signs, presence of concomitant stifle disease, presence of grossly visible pelvic limb conformational abnormalities and the details and outcome of treatment.

The presence and type of conformational abnormalities were determined from the records of the initial physical examination because standardised preoperative images were not available. Similar to pre-

vious studies, the affected breeds were divided into four categories according to Kennel Club standards (i.e. small, medium, large and giant breed dogs) (4, 7, 16). Patellar luxation was graded in severity on a scale of I-IV as previously described (17).

In dogs that were treated surgically, the ratio of patellar tendon to patella length (PT:P), concomitant stifle abnormalities, the method of surgical treatment, complications, and surgeon-assessed outcome were also evaluated. The PT:P was measured from non-luxated mediolateral stifle radiographs in accordance with a previously reported technique (14).

Surgical procedures, when performed, were at the surgeon's discretion and with the full and informed consent of the owners. A craniomedial or craniolateral parapatellar arthrotomy was performed in all animals (18). Surgical techniques included block or wedge recession sulcoplasty, tibial tuberosity transposition, lateral release, medial imbrication and distal femoral osteotomy. In dogs that had bilateral correction, the interval between the surgical procedures was dependent on postoperative limb function, wound healing, and level of client perceived disability.

Follow-up data assessed included all reexaminations, treatments, and recorded client communications by the attending surgeon. Postoperative complications were defined as those managed surgically or non-surgically. Surgically managed complications were then subcategorized as those cases in which revision surgery was performed or recommended to the owner, and those that had implant removal.

Surgeon-assessed outcomes were graded as excellent (no lameness), good (intermittent mild lameness), fair (moderate lameness), or poor (severe or non-weight bearing lameness) as previously described (6, 8).

## Statistical analysis

All statistical analyses were performed using commercial software[a]. Data were reported as mean and standard deviation or median and range. Differences between measured variables were tested using Chi-square or Fisher's exact test for categorical variables and the Mann-Whitney U or Kruskal Wallis ANOVA for continuous variables. Statistical significance was set at $p < 0.05$. All data were compared and assessed for significant associations.

## Results

Sixty-five dogs with 95 limbs affected by lateral patellar luxation were included in the study. Thirty-nine (60%) dogs were male (11 were neutered) and 26 (40%) were female (10 were neutered). The median age at presentation was 10 months (range: 2.5–120 months) (▶Table 1), and the median weight was 19.9 kg (range: 1.75–56 kg). Thirty-two different breeds were identified. The commonly represented breeds included Cocker Spaniel (n = 13), Flat Coat Retriever (n = 5), Bassett Hound (n = 4), Newfoundland (n = 4), and Springer Spaniel (n = 4). There were 23 other breeds which had three or fewer cases (▶Appendix Table 1 – available online at www.vcot-online.com). The dogs were classified according to breed as small (n = 6), medium (n = 23), large (n = 27), and giant (n = 9).

The median duration of clinical signs prior to presentation was 60 days (range: 4–120 days). On examination 35 dogs had unilateral and 30 had bilateral lateral patellar luxation. Lateral patellar luxation was classified as being grade I (14/95 stifles), grade II (41/95 stifles), grade III (29/95 stifles), and grade IV (11/95 stifles). Surgical correction was performed in 58/95 stifles with grade I (n = 4), grade II (n = 26), grade III (n = 20), and grade IV (n = 8) lateral patellar luxation. Dogs with higher-grade luxations were significantly more likely to be presented at a younger age than dogs with lower grade luxations ($p = 0.032$). Of the bilaterally affected dogs, 24 had the same grade bilaterally whilst six had different grades in each limb. Combinations included grades I and II (n = 3), grades I and III (n = 1), and grades II and III (n = 2). Of the eight bilaterally affected dogs that were presented with the complaint of unilateral lameness, there were three dogs with different grades in each limb.

Grossly visible pelvic limb conformational abnormalities were recorded in 34/95 stifles. These deformities included genu valgum (n = 28), external rotation of the distal limb with a 'cow hocked' appearance (n = 5), and hypoflexion of the hocks (n = 2). A higher-grade of luxation was associated with the presence of visibly apparent conformational abnormality ($p = 0.04$), particularly with the presence of genu valgum ($p = 0.01$) (▶Table 1).

Hip dysplasia was diagnosed in 18 cases. The presence or absence of stifle osteoarthritis was recorded in 83/95 stifles. Thirty-nine stifles were recorded to have evidence of osteoarthritis.

Corrective surgery was performed on 58/95 stifles. Fifty-one of these stifles had a tibial tuberosity transposition, 29 of which were augmented with a tension band wire. Femoral trochlear sulcoplasty was performed in 46/58 stifles by wedge recession (n = 42) or block recession techniques (n = 4). Medial imbrication was performed in 45/58 stifles and lateral release was performed in 20/58 stifles. Femoral osteotomies were performed to correct distal femoral valgus in three of 58 stifles. There were 15 different combinations of eight different procedures performed. The most common combination was tibial tuberosity transposition, wedge recession sulcoplasty, and medial imbrication (35/58). Fifteen of these also had a tibial tuberosity tension band wire and 15 had a lateral release. Ten

**Table 1** Distribution of significant variables associated with eacg grade of lateral patellar luxation. Dogs with higher grade luxations were more likely to present at a younger age ($p = 0.032$), have a visible conformational abnormality ($p = 0.04$), and have genu valgum ($p = 0.001$).

| Grade of luxation | Total stifles | Median age (months) | Stifles with genu valgum |
|---|---|---|---|
| I | 14 | 16.5 | 3 |
| II | 41 | 12 | 3 |
| III | 29 | 7 | 17 |
| IV | 11 | 6 | 5 |
| **Total** | **95** | **10** | **28** |

a Prism Graphpad software, Inc, La Jolla, USA

dogs had bilateral staged surgery. The median interval between surgical procedures was eight weeks (range 5–32 weeks).

Concomitant stifle abnormalities at the time of surgery were recorded in 14 of 58 stifles. These included abrasions or avulsion injuries of the origin of the long digital extensor tendon (n = 8), dysplastic lateral femoral condyle (n = 3), and convex trochlear (n = 3). No additional procedures were performed to treat the long digital extensor tendon injuries.

Suitable mediolateral stifle radiographs were available for evaluation for 33 dogs. The median PT:P was 1.76; the mean was 1.73 (range: 0.96–2.32; 95% CI: 1.61–1.85).

Fifty-seven of 58 stifles were available for postoperative assessment with one case lost to follow-up. The median duration of clinical follow-up was 16 weeks (range: 4–260 weeks). Twenty-two of these stifles sustained one or more complications. Ten stifles had a complication that was managed surgically. These included six with revision surgery and four with implant removal. Multiple complications were recorded in three stifles; no stifle had more than one surgical complication. There were 16 complications that were managed nonsurgically. The types and frequencies of postoperative complications are listed in ►Table 2.

Recurrent lateral patellar luxation was the most common complication and occurred in six stifles, four of which had a revision surgery. Over correction leading to medial patellar luxation occurred in two stifles, one of which had a revision surgery. Three dogs with postoperative medial or lateral patellar luxation that were treated conservatively had subclinical grade 1 luxations and good or excellent outcomes. Tibial tuberosity avulsion fracture occurred in four cases and one had revision surgery. Other complications included wound breakdown and infection (n = 5), implant loosening and failure (n = 4), and seroma (n = 5). One dog with wound infection and three dogs with implant loosening and failure had minor surgical procedures to remove the implants. Complications were more likely to occur in dogs with unilateral luxations (p = 0.03), but were not associated with any other variable.

**Table 2**
Types and frequency of postoperative complications following lateral patellar luxation surgery.

| Complications | Frequency | Managed conservatively | Managed surgically |
|---|---|---|---|
| MPL | 2 | 1 | 1 |
| LPL | 6 | 2 | 4 |
| Seroma | 5 | 5 | 0 |
| Wound problems | 5 | 4 | 1 |
| Implant failure | 4 | 1 | 3 |
| Tuberosity avulsion | 4 | 3 | 1 |
| **Total** | **26** | **16** | **10** |

MPL = medial patellar luxation; LPL = lateral patellar luxation.

Surgeon assessed outcome was available for 51/58 stifles; seven stifles had incomplete data sets. Outcome was graded as being excellent (n = 14), good (n = 33), and fair (n = 4). No dog was recorded as having a poor outcome. There were no significant associations between the outcome and any other variable.

## Discussion

In this study of a large series of cases suffering from lateral patellar luxation, there were several features that were similar to those reported for medial patellar luxation. These included the mean age at presentation, the ratio of unilateral to bilateral patellar luxation, and the distribution of grades (4, 6, 7, 13). The male to female ratio was 1.5:1, which is similar to medial patellar luxation in some studies, but is different to others (4, 6, 8, 12, 13). These similarities may reflect a common aetiopathogenesis.

Dogs with higher-grade luxations were presented at an earlier age, and were more likely to undergo surgical correction. Whilst the reason is unclear, intuitively this is not surprising; higher-grade luxations probably caused more obvious client perceived lameness and hence were more likely to generate a proactive treatment by the surgeon.

Lateral patellar luxation has previously been considered a disease of large and giant breed dogs (4, 9). However, in the present study it was observed more frequently in medium and large breed dogs. Whilst this may reflect a changing demographic in our patient population, there is a paucity of previous population data on lateral patellar luxation with which to compare. The Cocker Spaniel was the most commonly affected breed in our study. Although our study design prevents a direct comment on breed predispositions, this finding is consistent with a previous report (13). However, it should be noted that between the years 2000 and 2011, the Cocker Spaniel was consistently reported as the second most popular breed registered with the United Kingdom Kennel Club, and breed popularity may in part explain the number of Cocker Spaniel dogs in the present study (19).

Genu valgum was present in 29% of affected stifles and was significantly associated with higher-grade luxations. As is the case in some dogs with high grade medial patellar luxation, it would be reasonable to presume that a proportion of these dogs also had femoral and or tibial deformities (20, 21). Unfortunately, the lack of standardized preoperative imaging of the pelvic limbs prevented us from determining whether this was the case. It therefore remains uncertain if genu valgum reflects an underlying bone deformity that plays a role in the development of lateral patellar luxation, or if it is simply a posture adopted by the dog to compensate for patellar instability. Whilst future radiographic assessment of femoral deformity may be useful, CT assessment may be superior particularly in cases with multiplanar deformities or femoral condylar dysplasia (22, 23).

Concomitant hip dysplasia has been associated with patellar luxation and was reported in 28% of our cases (5, 9). Although

patellar luxation and hip dysplasia may occur concurrently, a causative relationship between the two is contentious (7, 10, 17). In the present study, the presence of hip dysplasia was not associated with any other variable, including postoperative complications and outcome.

The PT:P ratio is used in people to assess patellar position and hence diagnose patella alta or baja; in people lateral patellar luxation is associated with patella alta (24). Previous investigations of PT:P in dogs have demonstrated an association between medial patellar luxation and a high PT:P, which the authors suggested implied patella alta (14, 25). No significant difference was demonstrated between control dogs (i.e. dogs without patellar luxation) and dogs with lateral patellar luxation. However, the numbers of dogs with lateral patellar luxation were small (n = 9) leading to possible type 2 error (14). Whilst there was no control group in our study, interestingly the mean and median PT:P in our study (1.73; 95% CI: 1.61–1.85) was lower than that of the control group (2.02; 95% CI: 1.97–2.06) reported in another study; this may suggest an association between a low PT:P and lateral patellar luxation (14).

It should be noted that the PT:P fails to take into account variations in patient anatomy such as the extent of the trochlear groove, the proximity of the patellar tendon insertion to the tibial joint surfaces, and the femorotibial standing angle. In our opinion, a low PT:P does not necessarily indicate patella baja but instead may represent normal anatomical variation between affected breeds. Further investigation is warranted.

Long digital extensor tendon abnormality was previously described in a case report in which it was suggested that chronic lateral luxation of the patella may lead to mechanical trauma to the long digital extensor tendon (26). No treatment was required in our cases, and the presence of this abnormality was not associated with any other variable such as grade of luxation, nor did it appear to affect the incidence of postoperative complications or outcome.

Previous studies have suggested that dogs with lateral patellar luxation may be at a higher risk for the development of complications than those with medial patellar luxation (13). The incidence of postoperative complications in our study was higher than some other reports of medial patellar luxation (15–29%), and similar to others (40–48%) (6, 8, 13, 27, 28). However, given the large differences in study designs of these reports, direct comparisons between cannot be made.

The types of postoperative complications in the present study were consistent with previous lateral and medial patellar luxation reports (6, 8, 13, 28). Also in agreement with other studies, recurrent patellar luxation was the most common complication, occurring in 11% of cases (6, 8, 13, 28). Though no significant risk factors were identified in our study, recurrent luxation suggests that there was an inadequate appreciation of the underlying pathological changes or that an inadequate corrective procedure had been performed. Uncorrected distal femoral varus has been reported to be associated with recurrent medial patellar luxation in dogs (20). Therefore it seems reasonable to assume that distal femoral valgus may be associated with lateral patellar luxation (15). Previous studies have also demonstrated a lower frequency of reluxation when a tibial tuberosity transposition and sulcoplasty were performed (8, 13). Whereas radiographic and CT assessment of distal femoral angular deformities have been described with reference angles suggested for preoperative planning of corrective femoral osteotomies, there is little in the veterinary literature to aid planning for tibial tuberosity transpositions or sulcoplasties (20, 21, 23, 29). In people, tibial tuberosity transpositions can be planned by measuring the quadriceps angle using standardised radiographs or by using CT overlay of the tibial tuberosity and the femoral condyles (30). Though these techniques may be useful in dogs, the variation in conformation and standing angle between dog breeds would make interpretation challenging (11). Additionally, although it has been suggested that sulcoplasties are performed to ensure that half of the patella is within the trochlear groove, there is little supportive evidence for this recommendation (31).

Interestingly, the dogs with unilateral patellar luxations were more likely to sustain a complication. Given the absence of any other associations between unilateral patellar luxations and other studied variables, we suspect this is a type 1 error. No other significant risk factors for the development of any complication were identified. This is in contrast to previous studies that have reported significant associations between weight, grade of patellar luxation and surgical technique on the incidence of complications after patellar luxation surgery (8, 13).

A good to excellent surgeon-assessed postoperative outcome was found in 92% of dogs. Though this is a subjective outcome measurement and therefore limits the conclusions that can be made, the result is similar to that reported following medial patellar luxation surgery and suggests that lateral patellar luxation surgery carries a similar prognosis (6, 8).

The study was limited by its retrospective design. The use of recorded data relied on the accuracy and completeness of medical records. Variations between surgeons, such as patient assessment, choice of treatment, and management of complications, were unavoidable given the multicentre nature of the study. Though outcome measurements were subjective, given the absence of standardization of perioperative treatment, this limited information was considered sufficient for the purpose of this study. Future prospective cohort studies with standardized patient assessment and surgical treatments, postoperative management and objective outcome measurements may be helpful in describing treatment and outcome of lateral patellar luxation more accurately.

In conclusion, non-traumatic lateral patellar luxation was observed in all breed categories, but predominantly in medium and large breed dogs. It has several similar clinical features and can be surgically managed in a similar manner to medial patellar luxation with similar types of complications and outcomes expected.

## Conflict of interest

None declared.

## References


1. Johnson JA, Austin C, Breur GJ. Incidence of canine appendicular musculoskeletal disorders in 16 veterinary teaching hospitals from 1980 through 1989. Vet Comp Orthop Traumatol 1994; 7: 56–69.
2. Ness MG, Abercromby RH, May C, et al. A survey of orthopaedic conditions in small animal veterinary practice in Britain. Vet Comp Orthop Traumatol 1996; 9: 43–52.
3. Ruble RP, Hird DW. Congenital abnormalities in immature dogs from a pet store: 253 cases (1987–1988). J Am Vet Med Assoc 1993; 202: 633-636.
4. Hayes AG, Boudrieau RJ, Hungerford LL. Frequency and distribution of medial and lateral patellar luxation in dogs: 124 cases (1982–1992). J Am Vet Med Assoc 1994; 205: 716-720.
5. LaFond E, Breur GJ, Austin CC. Breed susceptibility for developmental orthopedic diseases in dogs. J Am Anim Hosp Assoc 2002; 38: 467-477.
6. Alam MR, Lee JI, Kang HS, et al. Frequency and distribution of patellar luxation in dogs. 134 cases (2000 to 2005). Vet Comp Orthop Traumatol 2007; 20: 59–64.
7. Bound N, Zakai D, Butterworth SJ, et al. The prevalence of canine patellar luxation in three centres. Clinical features and radiographic evidence of limb deviation. Vet Comp Orthop Traumatol 2009; 22: 32-37.
8. Gibbons SE, Macias C, Tonzing MA, et al. Patellar luxation in 70 large breed dogs. J Small Anim Pract 2006; 47: 3–9.
9. Bojrab MJ. Pathophysiology in Small Animal Surgery. Philadelphia: Lea & Febiger; 1981. p. 638-640.
10. Piermattei DL, Flo GL, DeCamp CE, et al. Brinker, Piermattei and Flo's Handbook of Small Animal Orthopedics and Fracture Repair. 4th ed. Edinburgh: Elsevier Saunders; 2006. p. 562–630.
11. Towle HA, Griffon DJ, Thomas MW, et al. Pre- and postoperative radiographic and computed tomographic evaluation of dogs with medial patellar luxation. Vet Surg 2005; 34: 265-272.
12. Hulse DA. Pathophysiology and management of medial patellar luxation in the dog. Vet Med Small Anim Clin 1981; 76: 43–51.
13. Arthurs GI, Langley-Hobbs SJ. Complications associated with corrective surgery for patellar luxation in 109 dogs. Vet Surg 2006; 35: 559-566.
14. Mostafa AA, Griffon DJ, Thomas MW, et al. Proximodistal alignment of the canine patella: radiographic evaluation and association with medial and lateral patellar luxation. Vet Surg 2008; 37: 201-211.
15. Witte PG, Scott HW. Treatment of lateral patellar luxation in a dog by femoral opening wedge osteotomy using an interlocking nail. Vet Rec 2011; 168: 243.
16. The Kennel Club. Breed Information Centre [page on website]. The Kennel Club; 2014 [cited on 2013 Janiary 1]. Available from: http://www.the-kennel-club.org.uk/services/public/breed/Default.aspx.
17. Roush JK. Canine patellar luxation. Vet Clin North Am Small Anim Pract 1993; 23: 855-868.
18. Piermattei DL, Johnson KA. An Atlas of Surgical Approaches to the Bones and Joints of Dogs and Cats. 4th ed. Philadelphia, Pa: Saunders; 2004.
19. The Kennel Club. Media Centre [page on website]. The Kennel Club; 2014 [cited on 2013 Janiary 1]. Available from: http://www.thekennelclub.org.uk/our-resources/media-centre/.
20. Roch SP, Gemmill TJ. Treatment of medial patellar luxation by femoral closing wedge ostectomy using a distal femoral plate in four dogs. J Small Anim Pract 2008; 49: 152-158.
21. Swiderski JK, Palmer RH. Long-term outcome of distal femoral osteotomy for treatment of combined distal femoral varus and medial patellar luxation: 12 cases (1999–2004). J Am Vet Med Assoc 2007; 231: 1070-1075.
22. Dudley RM, Kowaleski MP, Drost WT, et al. Radiographic and computed tomographic determination of femoral varus and torsion in the dog. Vet Radiol Ultrasound 2006; 47: 546-552.
23. Palmer RH, Ikuta CL, Cadmus JM. Comparison of femoral angulation measurement between radiographs and anatomic specimens across a broad range of varus conformations. Vet Surg 2011; 40: 1023-1028.
24. Insall J, Goldberg V, Salvati E. Recurrent dislocation and the high-riding patella. Clin Orthop Relat Res 1972; 88: 67-69.
25. Johnson AL, Broaddus KD, Hauptman JG, et al. Vertical patellar position in large-breed dogs with clinically normal stifles and large-breed dogs with medial patellar luxation. Vet Surg 2006; 35: 78–81.
26. Bardet JF, Piermattei DL. Long digital extensor and popliteal tendon avulsion associated with patellar luxation in a dog. J Am Vet Med Assoc 1983; 183: 465-466.
27. Willauer CC, Vasseur PB. Clinical results of surgical correction of medial luxation of the patella in dogs. Vet Surg 1987; 16: 31-36.
28. Linney WR, Hammer DL, Shott S. Surgical treatment of medial patellar luxation without femoral trochlear groove deepening procedures in dogs: 91 cases (1998–2009). J Am Vet Med Assoc 2011; 238: 1168-1172.
29. Swiderski JK, Radecki SV, Park RD, et al. Comparison of radiographic and anatomic femoral varus angle measurements in normal dogs. Vet Surg 2008; 37: 43-48.
30. Beaconsfield T, Pintore E, Maffulli N, et al. Radiological measurements in patellofemoral disorders. A review. Clin Orthop Relat Res 1994:18–28.
31. Slocum B, Devine T. Trochlear recession for correction of luxating patella in the dog. J Am Vet Med Assoc 1985; 186: 365-369.

# Proximal focal humeral deficiency in a large breed dog

**S. Kalff; T. Gemmill**
Willows Veterinary Referral Service, Solihull, United Kingdom

**Keywords**
Humerus, dog, athrodesis, shoulder, developmental

**Summary**
A 26-week-old female Boerboel was referred for evaluation of progressive left thoracic limb lameness. Computed tomography and radiographic evaluation revealed radiolucency of the caudal region of the proximal humeral metaphysis, absence of the humeral head, and gross distortion of the glenoid. Given the severe glenohumeral deformation, arthrodesis of the left shoulder was performed using orthogonal locking bone plates, lag screw fixation, and bone grafting. Despite late implant failure, arthrodesis was successful in this case, and satisfactory limb function was restored. To the author's knowledge, this is the first report of a case of a focal developmental deficiency of the proximal humerus reported in a dog.

**Correspondence to:**
Stephen Kalff, BVSc, MACVSc, MRCVS
Willows Referral Service
Highlands Road
Shirley, Solihull B90 4NH
United Kingdom
Phone: +44 121 712 7070
Fax: +44 121 712 7077
E-mail: skalff@hotmail.com

**Vet Comp Orthop Traumatol 2012; 25: 532–536**
**doi:10.3415/VCOT-12-01-0006**
Received: January 11, 2012
Accepted: June 27, 2012
Pre-published online: July 25, 2012

## Introduction

Defects of pre- or postnatal limb development can manifest as bone agenesis or dysplasia, and can be generalized or localized to individual bones or limbs. The aetiology is commonly hereditary, although teratogens, trauma, sporadic mutations and neoplasia are also possible. Individual bone agenesis, a form of meromelia, has been well documented in dogs and humans (1–4). However, there are only a few reports relating to agenesis or failure of development of segments of bone in the absence of other bone or systemic pathology.

Complete absence of the femoral head and neck has been reported as a form of proximal femoral focal deficiency in humans (5). Although often localized to the affected limb, associated concurrent skeletal and systemic disorders have been reported (6). A suspected case of proximal femoral focal deficiency has been reported in a young Dobermann Pinscher (7). To the authors' knowledge a similar disorder of the thoracic limb has not been reported in dogs, although focal agenesis of the carpus in a cat was reported (1).

A case of marked humeral head deformity and apparent cranial bowing of the proximal humerus, described as shoulder dysplasia, was reported as part of a case series (8). However, few details of the case were available for review. Other failures of humeral head development have been reported in humans and dogs with multiple epiphyseal dysplasia (9–12). A form of osteochondral dysplasia, multiple epiphyseal dysplasia is a rare hereditary condition of people and dogs which is characterized by defective ossification of multiple long bones and occasionally vertebral epiphyses. To the authors' knowledge, focal proximal humeral epiphyseal aplasia has not been previously reported.

This report documents the clinical course and successful treatment of a dog with proximal focal humeral deficiency.

## Case report

A 26-week-old female Boerboel dog was referred for evaluation of left thoracic limb lameness of 10 weeks duration. The lameness had reportedly been acute in onset with no history of trauma, and had progressed despite restriction of activity to 10 minute lead walks and treatment with oral meloxicam[a] (0.1 mg/kg PO SID). On examination, the dog exhibited a grade 3/10 left thoracic limb lameness. There was palpable distortion of the bone landmarks of the left shoulder. Sings of mild discomfort and a reduction in range-of-motion were also apparent. Clinical examination was otherwise unremarkable. Review of submitted radiographs (▶Fig. 1), obtained six weeks earlier, revealed radiolucency of the caudal region of the proximal humeral metaphysis and apparent absence of the humeral head. The greater tubercle was misshapen and the proximal humeral physis grossly distorted. There was mild procurvatum of the proximal humerus and the glenoid appeared flattened and dysplastic. Given the age of the patient and the relatively mild clinical signs, an additional period of continued conservative management was recommended.

On examination 10 weeks later, the dog demonstrated a grade 4/10 left thoracic limb lameness. At rest the dog was unable to extend the shoulder and elbow sufficiently to fully bear weight on the limb. A mild degree of muscle atrophy of the proximal region of the left thoracic limb was noted. Although the range-of-motion of the left shoulder had decreased, no obvious signs of discomfort were elicited during examination.

Computed tomography[b] imaging of the right and left thoracic limb was performed (▶Fig. 2). Marked derangement of the left glenohumeral joint was observed. The humeral head was absent and was replaced with a radiolucent defect extending across the caudal aspects of the physis, metaphysis and proximal diaphysis. Multiple mineral-

[a] Metacam: Boehringer Ingelheim UK Ltd, Bracknell, UK
[b] Brightspeed: GE Healthcare, Little Chalfont, UK

ized bodies were evident throughout the radiolucent metaphyseal region. The cranial segment of the proximal humeral physis appeared normal. The greater tubercle was misshapen and there was marked procurvatum of the proximal humerus. Marked remodelling of the glenoid was also apparent. The left radius and ulna were longer than their contralateral counterparts. Asymmetry of the thoracic limb muscles was noted with moderate atrophy on the left side. No obvious abnormalities were detected in the right thoracic limb. A fine needle aspirate of the left shoulder did not demonstrate any evidence of malignancy or infection.

Arthrotomy and salvage surgery by glenohumeral arthrodesis were performed four weeks later. A lateral approach was made to the left glenohumeral joint, incorporating the acromial and greater tubercle osteotomies, and tenotomies of the teres minor and infraspinatus insertions (13). The glenohumeral joint was luxated. Exuberant fibrous tissue was resected from the caudal aspect of the joint and samples were submitted for histopathology. Care was taken to identify and preserve the suprascapular nerve. Using an oscillating saw, ostectomies of the glenoid and the proximal humerus were performed to remove dysplastic tissue and to improve reduction and contact of the bone segments. The humerus was translated caudally to maximise bone contact. Autogenous cancellous bone graft, harvested from the ostectomised glenoid, and 3 cc demineralised bone matrix[c] were packed in and around the arthrodesis site. Interfragmentary compression was achieved with a 3.5 mm self-tapping cortex screw directed craniodistal to caudoproximal placed in lag fashion. A 3.5 mm narrow locking compression plate[d] was contoured and placed on the cranial aspect of the scapula and humerus, and secured with two cortical and three locking screws in the scapula, and six cortical screws in the humerus. A 6-hole 3.5 mm String of Pearls locking plate[e], secured with two proximal and two distal screws, was contoured and applied to the caudolateral region of the scapula and humerus. The greater tubercle and acromial osteotomies were both reduced and stabilized with two pins and tension band wires. Soft tissues were closed routinely. Postoperative craniocaudal and mediolateral radiographs (▶Fig. 3) demonstrated satisfactory limb alignment and implant position. The dog recovered from anaesthesia without complication and was discharged from the hospital 24 hours following surgery. Meloxicam (0.1 mg/kg PO SID) and cephalexin[f] (20 mg/kg PO BID) were administered for five days. Additional analgesia was provided with a transdermal 100 µg fentanyl[g] patch applied for 96 hours. The owners were instructed to restrict the dog's exercise to leash walks only. Skin sutures were removed by the referring veterinarian two weeks postopertively and there were no complications reported.

Histopathology of the submitted samples revealed disorganized, poorly cellular fibrocartilagenous tissue in which plump spindle cells of uniform size were scattered throughout an abundant collagenous to myxoid matrix with multifocal chondroid metaplasia. Multifocal necrosis of the fibrous tissue with hyalinization of collagen fibres and areas of haemorrhage were also observed. These findings were consistent with dysplastic proliferative fi-

**Fig. 1** Mediolateral radiograph of the left shoulder obtained at the referring veterinary practice six weeks prior to referral. Note the apparent absence of the humeral head, distortion of the caudal aspect of the proximal humeral physis, radiolucency of the caudal proximal humeral metaphysis, and remodelling of the glenoid.


**Fig. 2** Computed tomography image of the left shoulder. **A)** Sagittal plane reconstruction of proximal left humerus showing absence of the humeral head and a radiolucent defect extending across the physis and into the caudal metaphysis. Note the multiple mineralised bodies within the defect. **B)** Reconstructed three-dimensional image of the left proximal thoracic limb demonstrating the severe derangement of the glenohumeral joint and procurvatum of the proximal humerus.

[c] DBM, Veterinary Tissue Bank Ltd, Wrexham, UK
[d] Locking Compression Plate (LCP): Synthes Ltd, Hertfordshire, UK
[e] String of Pearls (SOP): Orthomed UK Ltd, Halifax, UK

[f] Rilexine: Virbac Ltd, Burley St Edmunds, UK
[g] Durogesic: Janssen-Cilag, High Wicombe, Buckinghamshire, UK


**Fig. 3** Caudocranial **(A)** and mediolateral **(B)** left shoulder radiographs demonstrating immediate postoperative implant position.

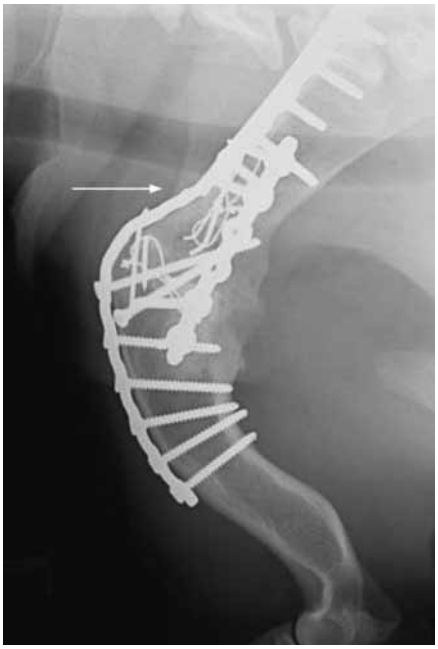

**Fig. 4** Mediolateral radiograph of the left shoulder obtained 24 weeks postoperatively demonstrating good progression of arthodesis and failure of the locking compression plate (white arrow).

brocartilaginous tissue. There was not any evidence of neoplasia or infection present.

At the eight week postoperative re-examination, moderate left thoracic limb lameness was evident, but limb function appeared improved compared to preoperatively. The shoulder was stable on manipulation and no signs of discomfort were elicited. Due to financial constraints, sedation and radiographs were postponed.

Two weeks later the referring veterinarian reported that the dog had an acute exacerbation of lameness following a fall. However, aside from moderate left thoracic limb lameness, the findings of a clinical examination were unremarkable. Radiographs performed by the referring veterinarian demonstrated progression of arthrodesis and no evidence of implant failure. Rapid clinical improvement was reported following restriction of activity and treatment with meloxicam (0.1 mg/kg PO SID) and tramadol[h] (4 mg/kg PO TID).

At re-examination performed 24 weeks postoperatively, signs of subtle left thoracic limb lameness were evident. The left shoulder was palpably stable and there were not any signs of discomfort on manipulation. Radiographs demonstrated progression of arthrodesis (►Fig. 4). The cranial locking compression plate was broken, however, there was no other evidence of implant loosening or failure. A gradual return to normal activity over four weeks was recommended.

[h] Tramadol: Bristol Laboratories Ltd, Berkhampsted, UK

## Discussion

Although the aetiology and pathogenesis are unknown, the pathology described in this case represents a manifestation of a focal developmental failure of bone formation.

The thoracic and pelvic limbs develop from limb buds, which arise from cervicothoracic and lumbosacral regions of the embryo respectively. The limb buds consist of a mesenchymal core covered by cuboidal ectoderm. The thoracic limbs appear before the pelvic limbs. As the limb bud grows it becomes divided by constrictions into the manus, antebrachium and brachium, and the mesenchymal core differentiates and condenses to hyaline cartilage models of future bone. Skeletal elements form in a proximal to distal sequence within each limb; firstly the scapula forms, then the humerus, and so forth. Towards the end of the embryonic period, primary ossification centres appear in the middle of long bones and endochondral ossification progresses towards the proximal and distal ends of the cartilage models. The ends of each developing long bone (epiphyses) are separated from the ossifying diaphysis by cartilage plates (physes). Later, ossification centres arise at the epiphysis and endochondral ossification proceeds on both sides of the physis. Longitudinal bone growth is primarily due to endochondral ossification at the physes. When the bone has acquired its full length, the physes close and the epiphyses fuse with the diaphysis (14).

The proximal, focal and unilateral nature of the pathology in this case is similar to that described for proximal femoral focal deficiency, albeit in the thoracic limb. In humans, proximal femoral focal deficiency is thought to result from either a neural

crest injury or a defect in proliferation and maturation of chondrocytes in the proximal growth plate (5). Although maternal use of thalidomide has been demonstrated to cause proximal femoral focal deficiency, other aetiologies including trauma, infection, irradiation, and ischaemia have also been implicated (15). Concurrent abnormalities in other limbs are reported in up to 50% of people with proximal femoral focal deficiency (6). No hereditary cause has been identified.

Failures of normal development of the humeral head are reported in multiple epiphyseal dysplasia and shoulder dysplasia (8–11). Multiple epiphyseal dysplasia is a heterogenous disease characterized by a delay or failure of epiphyseal endochondral ossification leading to an inability of articular cartilage to withstand normal cyclical loading. The severity of signs is variable and can also involve the metaphysis. Whilst the aetiology and pathogenesis of shoulder dysplasia have not been described, its phenotype is similar to multiple epiphyseal dysplasia. The case reported by Pucheu and others may represent a focal failure of normal epiphyseal endochondral ossification, or could be a dog with multiple epiphyseal dysplasia where other epiphyses are subclinically affected (8).

As well as a deficiency of the epiphysis, this case also appeared to have failure of ossification of the caudal proximal metaphysis. This may have similarities to retained cartilaginous cores which have been reported in giant breed dogs affecting the distal ulna metaphysis (16). Retained cartilaginous cores are thought to occur secondary to a failure of endochondral ossification and can be associated with premature closure of the affected physis and subsequent antebrachial deformities (16).

The lesion in this case appears to share some characteristics with proximal femoral focal deficiency, shoulder dysplasia, multiple epiphyseal dysplasia and a retained cartilaginous core. Unfortunately the precise pathogenesis could not be determined; further studies of additional cases would be required to establish this.

The antebrachium of the affected limb was longer than the unaffected limb in this case. Compensatory overgrowth of the humerus and tibia have previously been described in dogs with antebrachial and femoral pathology respectively (17–19). Though not previously reported in the ulna and radius, it would be reasonable to attribute the overgrowth seen in this case to a similar mechanism.

The severity of anatomical derangement in this case precluded reconstructive surgery. Due to the progression of clinical signs despite conservative management, salvage surgery was recommended. Total joint replacement using custom implants was considered. Hemiarthropasty of the shoulder has been previously reported in research dogs, but long-term success rates of shoulder replacements are unreported (20). Shoulder arthrodesis has previously been described with generally favourable clinical outcomes, and this procedure was performed in this case (8, 21, 22). Given the size of the dog and its boisterous nature, a second lateral String-of-Pearls plate was applied to increase the construct's strength, stiffness and fatigue life. The mechanical failure of the cranial locking compression plate noted at 24 weeks postoperatively probably occurred secondary to fatigue. It is interesting to note that failure occurred at a point where the plate had been heavily contoured, presumably causing a focal weakness of the implant. It is possible that plate failure could have been avoided by the use of a 3.5 mm broad implant; however this would have made contouring more challenging. The failure probably occurred late in the recovery period and did not affect outcome.

Harvesting the autogenous cancellous bone graft from the ostectomised glenoid avoided any risk of donor site complications, and combining the autograft with demineralised bone matrix allowed expansion of the graft to fill a relatively large defect. Autogenous cancellous bone graft combined with demineralised bone matrix has been reported to be effective in aiding healing of arthrodesis and appears to be at least as efficacious as autogenous graft alone (23).

In conclusion, an unusual case of proximal focal humeral deficiency is reported. Stabilisation using orthogonal locking plates and lag screw fixation was successful in providing stability to achieve shoulder arthrodesis. Despite late implant failure, arthrodesis was successful in this case, and satisfactory limb function was restored.

### Conflict of interest

None declared.

## References


1. Gemmill TJ, Clarke SP, Carmichael S. Carpal agenesis in a domestic short haired cat. Vet Comp Orthop Traumatol 2004; 17: 163–166.
2. James MA, McCarroll HR Jr., Manske PR. The spectrum of radial longitudinal deficiency: a modified classification. J Hand Surg Am 1999; 24: 1145–1155.
3. O'Brien CR, Malik R, Nicoll RG. What is your diagnosis? Bilateral forelimb deformity and abnormal gait in a young Devon Rex. J Feline Med Surg 2002; 4: 111–113.
4. Winterbottom EJ, Johnson KA, Francis DJ. Radial agenesis in a cat. J Small Anim Pract 1985; 26: 393–398.
5. Boden SD, Fallon MD, Davidson R, et al. Proximal femoral focal deficiency. Evidence for a defect in proliferation and maturation of chondrocytes. J Bone Joint Surg Am 1989; 71: 1119–1129.
6. Grogan DP, Holt GR, Ogden JA. Talocalcaneal coalition in patients who have fibular hemimelia or proximal femoral focal deficiency. A comparison of the radiographic and pathological findings. J Bone Joint Surg Am 1994; 76: 1363–1370.
7. Salavati M. Proximal femoral focal deficiency (PFFD) in a young Doberman pinscher. J Small Anim Pract 2008; 49: 486.
8. Pucheu B, Duhautois B. Surgical treatment of shoulder instability. A retrospective study on 76 cases (1993–2007). Vet Comp Orthop Traumatol 2008; 21: 368–374.
9. Rasmussen PG. Multiple epiphyseal dysplasia in a litter of Beagle puppies. J Small Anim Pract 1971; 12: 91–96.
10. Rorvik AM, Teige J, Ottesen N, et al. Clinical, radiographic, and pathologic abnormalities in dogs with multiple epiphyseal dysplasia: 19 cases (1991–2005). J Am Vet Med Assoc 2008; 233: 600–606.
11. Ingram RR. The shoulder in multiple epiphyseal dysplasia. J Bone Joint Surg Br 1991; 73: 277–279.
12. Briggs MD, Chapman KL. Pseudoachondroplasia and multiple epiphyseal dysplasia: mutation review, molecular interactions, and genotype to phenotype correlations. Hum Mutat 2002; 19: 465–478.
13. Piermattei DL, Johnson KA. An Atlas of Surgical Approaches to the Bones and Joints of Dogs and Cats. 4th ed. Philadelphia, Pa: Saunders; 2004. pg.112–116.
14. Sadler TW, Langman J. Langman's Medical Embryology. 9th ed. Philadelphia, Pa: Lippincott Williams & Wilkins; 2004. pg. 181–192.
15. Epps CH Jr. Proximal femoral focal deficiency. J Bone Joint Surg Am 1983; 65: 867–870.
16. Johnson KA. Retardation of endochondral ossification at the distal ulnar growth plate in dogs. Aust Vet J 1981; 57: 474–478.
17. Clements DN, Gemmill TJ, Clarke SP, et al. Compensatory humeral overgrowth associated with antebrachial shortening in six dogs. Vet Rec 2004; 154: 531–532.

18. Schultz KS, Davidson E. Compensatory humeral overgrowth in a dog. Vet Comp Orthop Traumatol 1999; 12: 92–96.
19. Schaefer SL, Johnson KA, O'Brien RT. Compensatory tibial overgrowth following healing of closed femoral fractures in young dogs. Vet Comp Orthop Traumatol 1995; 8: 159–162.
20. Matsen FA 3rd, Clark JM, Titelman RM, et al. Healing of reamed glenoid bone articulating with a metal humeral hemiarthroplasty: a canine model. J Orthop Res 2005; 23: 18–26.
21. Edinger DT, Manley PA. Arthrodesis of the shoulder for synovial osteochondromatosis. J Small Anim Pract 1998; 39: 397–400.
22. Vasseur PB. Arthrodesis for congenital luxation of the shoulder in a dog. J Am Vet Med Assoc 1990; 197: 501–503.
23. Hoffer MJ, Griffon DJ, Schaeffer DJ, et al. Clinical applications of demineralized bone matrix: a retrospective and case-matched study of seventy-five dogs. Vet Surg 2008; 37: 639–647.

 