Veterinary Surgery
38:285–300, 2009

INVITED REVIEW

Working Algorithm for Treatment Decision Making for Developmental Disease of the Medial Compartment of the Elbow in Dogs

NOEL FITZPATRICK, MVB CertSAO CertVR and RUSSELL YEADON, MA VetMB

INTRODUCTION

THERE IS disagreement about the manifestations of elbow pathology that should be included under the umbrella of elbow dysplasia. This is highlighted by variable inclusion or exclusion of diseases like ununited medial epicondyle[1] and elbow incongruity[2] with the more commonly recognized and historically grouped triad of (1) disease of the medial aspect of the coronoid process (medial coronoid disease; MCD); (2) osteochondrosis (OC) or osteochondritis dissecans (OCD) of the medial humeral condyle; and (3) ununited anconeal process (UAP). Variations in grouping syndromes within elbow dysplasia contributes to confusion among veterinarians and dog owners about the precise nature of disease involved.

Whereas several diseases may coexist within the same joint,[3–5] it has become increasingly apparent from histomorphometric,[6] biomechanical,[2,7,8] and genetic or heritability[9,10] data that there is considerable independence in development of these multifactorial disease processes. This is further complicated by the spectrum of clinical signs and macroscopic pathology associated with any single disease process,[11] which has important implications for treatment and prognosis. Clearly, there is no single treatment for all recognized manifestations of elbow dysplasia, so seemingly, the initial step in developing a clinically useful decision-making algorithm is to deconstruct this oversimplified nomenclature.

A working understanding of the etiopathogenesis of these disease processes is needed to define and optimize treatments for a corresponding spectrum of pathologic change. Failure to understand and address underlying processes when treating overt pathology will almost inevitably lead to suboptimal outcome. Despite this lack of understanding, there is increasing recognition that joint incongruency is an important factor in the development of canine elbow disease, albeit in a more complex manner than initially proposed.[2,11] Concurrently, it is important to understand the utility and limitations of diagnostic methods (e.g. historical, clinical, imaging) for identification of pertinent disease characteristics. To the extent that these diagnostic approaches define appreciation of disease and thus direct treatment approaches, their precision has potentially profound implications for treatment outcomes. Finally, relevant outcome measures are critical to evaluate the efficacy of treatment approaches for individuals and across patient groups. Outcome measures provide a framework for accumulation of clinical evidence and application in the context of "evidence-based practice,"[12,13] and allow continued refinement of assumptions leading to progressive improvements in therapeutic strategies.

Thus, in considering this larger challenge—deconstructing currently used terminology, defining the etiopathogenesis of disease processes included in elbow dysplasia, improving diagnostic tests, and developing therapeutic strategies and outcome measures—we report the decision-making algorithms currently in use in our practice for disorders involving the medial compartment of the canine elbow. These algorithms have been developed from synthesis of current scientific foundations for

From Fitzpatrick Referrals, Eashing, UK.
Address reprint requests to Noel Fitzpatrick, MVB CertSAO CertVR, Fitzpatrick Referrals, Halfway Lane, Eashing, Surrey GU7 2QQ, UK. E-mail: noelF@fitzpatrickreferrals.co.uk.
Submitted April 2008; Accepted October 2008

0161-3499/09
doi:10.1111/j.1532-950X.2008.00495.x

this constellation of disorders, and interpreted and modified based on our clinical experience. Our purpose is to stimulate dialog, highlight areas of needed investigation, and provoke continued refinement of our collective understanding through robust clinical trials and focused studies of mechanisms and pathogenesis of elbow disease. We recognize that our efforts in this and our accompanying reports might generate controversy but anticipate that the framework we provide can serve as the foundation for future improvements.

DISEASE OF THE MEDIAL ASPECT OF THE CORONOID PROCESS

Diagnosis

Even when free fragmentation has been subsequently identified by arthroscopy or arthrotomy, identification of disease of the medial aspect of the coronoid process (MCD) has historically proven challenging despite use of diverse imaging modalities including radiography[2,14–17]; computed tomography (CT)[11,18]; scintigraphy[19]; and magnetic resonance imaging (MRI).[20] Typically, diagnosis is based on identification of secondary markers of degenerative joint disease in the absence of other discernable discrete pathologic changes.

We consider thorough clinical evaluation to be as important as subsequent diagnostic imaging techniques. Recognition of thoracic limb lameness can be relatively insensitive because of the high incidence of bilateral disease and because many younger dogs remain surprisingly mobile or behaviorally active despite severe elbow pathology. We find that evaluation of discomfort caused by elbow manipulation is a strong indicator of disease involving the medial compartment of the canine elbow. The most reproducible discomfort can be elicited on maximal flexion, and particularly on firm supination of the antebrachium while the elbow is held in moderate flexion. Response to deep digital pressure in the region of the insertion of the bicep brachii muscle over the medial aspect of the coronoid process is also a valuable indicator of potential disease. Positive responses to these tests alone, in the absence of any other identified source of lameness or pain, creates a high index of suspicion such that diagnostic imaging is directed toward identification of disease of the medial compartment of the elbow and more specifically MCD. If results of noninvasive imaging techniques are equivocal, we consider direct observation by arthroscopy or arthrotomy to be justified.

Detailed radiographic examination of both elbows is essential before any intervention. This allows more detailed classification of the nature of disease (specifically, likely chronicity, radiographic severity of subchondral disease, and presence of OC lesions) that may be valuable for further decision-making, rather than simply to confirm a diagnosis of MCD. This is of particular significance because elbows affected by MCD can be radiographically normal[21] or may be affected by only subtle subtrochlear sclerosis.[22] Furthermore, degree of osteophytosis is considered of minimal benefit in determination of an appropriate treatment protocol as it is poorly correlated with pathology subsequently identified by direct joint inspection[23,24] but has close associations with expression of cartilage genes.[25] Other imaging techniques or diagnostic tests useful for exclusion of potential primary or concomitant pathologies (e.g. shoulder lesions, musculotendinous injuries, neurogenic lameness, or neoplasia) are selected based on clinical findings. In particular, diseases involving the shoulder joint and adjacent structures should be excluded as causes of thoracic limb lameness.[26]

CT and more recently MRI scans are increasingly used to evaluate elbows where changes are equivocal on radiographic assessment[27]; however, arthroscopic evaluation constitutes the most important single interrogation directing our decision-making process for MCD with or without pathology of the medial aspect of the humeral condyle. We have observed equivocal findings on both CT and MRI where subchondral pathology was subsequently proven by histologic examination of coronoid specimens after arthroscopically identified MCD.[28] A spectrum of arthroscopic changes including fragmentation, cartilage fissures, chondromalacia, and cartilage fibrillation affect the medial coronoid process (MCP) and we consider these to be manifestations of a common underlying disease process.[24,29]

Etiopathogenesis

Pathologic changes initially affect subchondral bone with formation of microcracks, characteristic of local fatigue failure.[6] These changes typically occur at one of two anatomic sites, either the craniodistal tip of the medial aspect of the coronoid process, or more axially oriented in the region of the radial incisure. Although the precise nature of this fatigue phenomenon remains elusive, several hypotheses encompass the disparate range of recognized pathologic changes, all of which may be attributable to some form of humeroulnar conflict (HUC).

Static Radioulnar Length Disparity. Characterized by shortening of the radius relative to the ulna. This disparity effectively exposes the coronoid process of the ulna to increased load-bearing forces from the humerus throughout the full range of elbow movement. MCP disease has been identified by CT and arthroscopy in the absence of overt static incongruity,[27] so it seems unlikely that static incongruency plays a major role in some dogs,[11] although where definitively identified, MCD should be

considered a likely sequel. This form of incongruency might be expected to result in pathologic change focused at the tip of the medial aspect of the coronoid process but further biomechanical modeling is needed to validate this hypothesis.

Dynamic Radio-Ulnar Longitudinal Incongruency. Characterized by relative distal displacement of the proximal radial articular surface compared with the proximal aspect of the ulna during weight bearing or in certain positions within the range of motion of the elbow. This may account for the lack of reliable identification of "static" incongruity using conventional imaging techniques, and could result in a similar configuration of pathology to that described for static radioulnar length disparity. From an anatomic perspective, this hypothesis requires relative laxity between the radius and ulna and is thus considered less likely.

Incongruency Associated with the Shape of the Ulnar Trochlear Notch. Characterized relative to either the articular contours of the radial head or humeral condyle, or both, this abnormality could also result in focally increased loading forces. These could be limited to specific angles of joint flexion or extension, and would most likely be focused in the region of the tip of the medial aspect of the coronoid process. Some breed variation in radiographic shape of the ulnar trochlear notch has been reported[30] but association of this observation with clinical disease is unknown/uncertain.[8] Furthermore, techniques to standardize radiographic interpretation of conformational variation in trochlear notch shape have not been reported. It is likely that three-dimensional imaging modalities (CT, MRI) will be more sensitive to subtle conformation variations within the complex structure of the elbow joint. Further imaging and biomechanical investigation is needed to clarify the potential role of ulnar trochlear notch variation in the pathogenesis of MCD.

Primary Rotational Instability of the Radius and Ulna Relative to the Distal Aspect of the Humerus. From a theoretical perspective, osseous conformation discrepancies or perhaps ligamentous insufficiency, could result in instability and incongruence through part, or all, of the range of motion of the elbow joint. Angulation of the humeroulnar joint surface relative to the long axes of the component bones could effectively convert a lateral shear force into a compressive force, causing crushing of the medial aspect of the coronoid process between the radial head and the medial humeral condyle. Another possibility could be mismatch between the contour arc of the radial incisure of the MCP and the radial head. These forms of incongruency would hypothetically most likely result in pathologic changes focused in the region of the radial incisure and could partially account for clinically observed variation in distribution of pathologic changes.

Musculotendinous Mismatch. Rotational instability could occur as a secondary effect of musculotendinous mismatch in relation to the bony anatomy, in particular, disparity between muscle tensions generated during supination and pronation of the antebrachium relative to the humerus.[31–35] The biceps brachii/brachialis muscle complex has a large fan-shaped insertion onto the abaxial portion of the MCP and a smaller but equally robust insertion on the proximal radius. Mismatch in synchronized development of the osseous and/or musculotendinous components of the elbow joint may contribute to supra-physiologic overload of the MCP thorough this fan-shaped insertion. The biceps brachii/brachialis muscle complex has the potential to produce substantial loading forces as a major elbow flexor. In the racing greyhound the estimated combined joint moment of force produced by this muscle complex at the elbow and acting in flexion is 1990 Ncm.[36] Because its distal insertion is eccentrically located medially, a susbstantial component of this force in flexion could be converted into a supination force. As illustrated for the hypothesis on primary rotational instability, such aberrant force between the radial head and the radial incisure of the MCP could give rise to shear planes because of compression of the region of the radial incisure against the radial head and could give rise to the clinically observed pattern of arcuate fragmentation radiating out from the radial surface of the MCP.[34,35]

Disease Development

Progression of subchondral microcrack formation to visible cartilage fissuring or fragmentation by coalescence, appears variable between dogs and between different regions of the coronoid process. This may reflect variable patterns of biomechanical overload as described earlier. Importantly, subchondral microcrack formation extends beyond the area of superficial or macroscopic disease.[6] The pattern of visible pathologic change may be dependent on a balance between rate of microcrack formation and healing by fibrous infilling, and on the focal intensity of supraphysiologic forces, which could theoretically radiate outward from a central focus akin to fissure lines created by movement of tectonic plates. Thus shear planes might occur either at the tip, or at the radial incisure, of the MCP depending on the prevalent loading force.

Fragmentation represents one potential end stage of MCD (Fig 1), whereby the medial aspect of the coronoid process cannot be salvaged to provide a functional, pain-free, load-bearing surface. Age may be an important factor with potential repetitive overload of fissure zones or traumatic disruption of fissure zones leading to fragment formation—so-called "jump-down" lesions.[37] In

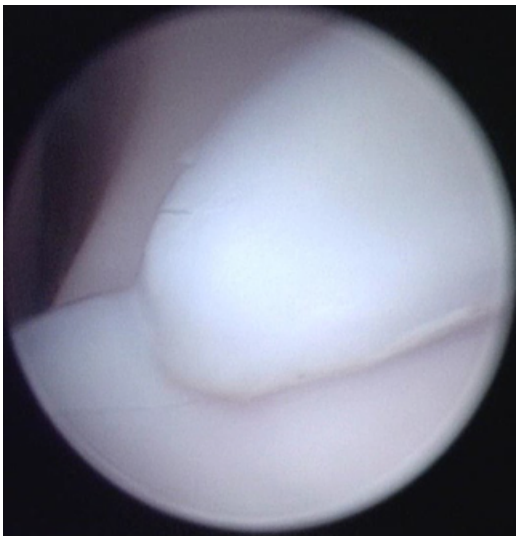

Fig 1. Arthroscopic image showing large fragment at radial incisure of medial aspect of coronoid process (center and right of image).

Danielson's study,[6] medial coronoid specimens from all age groups had diffuse microcrack formation. This finding lends credence to the concept that sudden fragmentation, even in mature dogs is preceded by microcrack formation.

However, we recognize dogs affected by a spectrum of lameness intensity and pain evident on elbow manipulation without visible fissuring or fragmentation, but with altered morphology of cartilage and subchondral bone.[6,28] Seemingly, the MCP in such dogs is affected by a slow progressive cycle of microfracture and cartilage fissuring, healing with fibrocartilage infilling of cartilage clefts, and subsequent repeated microfracture. Eventually, hyaline cartilage is replaced with fibrocartilage or similar fibrous tissue over underlying subchondral bone changes.[29] Lameness and pain may initially resolve with later recurrence when fracture or eburnation of mechanically inferior fibrocartilage occurs concomitant with progressive alteration in canalicular density of subchondral bone.[6]

Also in our experience, some dogs[6,29] have fissuring and fibrocartilage healing at loci across the medial aspect of the coronoid process with apparent sudden propagation of a microcrack to create a fragment (evidenced by a local lack of marginal healing or fibrocartilaginous ingrowth). This observation suggests that abrupt overloading of existing pathologic change created the lesion. Conversely, in some dogs, a cartilage-capped free osteochondral fragment has been identified, typically with substantially hypertrophic hyaline cartilage[6] with the remainder of the medial aspect of the coronoid process and typically the medial humeral condylar articular surface affected by full thickness cartilage eburnation. In this scenario, fragmentation would seemingly be an early component of the disease process occurring at a focal site of increased loading. Once the fragment is detached, its mobility may protect it from further load-bearing and cartilage abrasion, whereas loss of subchondral vascularity contributes to increasing cartilage thickness and even necrosis of the deeper layers of cartilage and/or bone typical of free osteochondral bodies within a joint, perhaps accounting for some reports of OC like lesions.[38] In our experience, it is common for the remaining intact portion of the medial aspect of the coronoid process to be affected by cartilage abrasion or eburnation because of persistent supraphysiologic loading with HUC.[39]

Joint pain and lameness can occur when there is intact cartilage over underlying subchondral pathology. From the preceding discussion, recognition that 2 potentially different end-stage changes, of varying chronology and intensity, can exist within the same joint, argues for treatment targeted at addressing subchondral pathology rather than removal of loose fragments alone or attempted stimulation of fibrocartilaginous infilling of superficial cartilage lesions. Notwithstanding the altered subchondral bone, focused attempts at cartilage repair seem especially challenging within a perceived environment of persistent supraphysiologic loading and abrasion attributable to HUC.

Treatment Options

Considering these proposed pathways, our preference for local treatment of end-stage MCD is subtotal coronoid ostectomy (SCO; Fig 2) whereby a pyramidal portion of the medial aspect of the coronoid process extending to include the entirety of the articular portion distal to the level of the radial incisure is removed. The surgical approach for this procedure includes blunt separation of the flexor carpi radialis/pronator teres and the superficial/deep digital flexor muscles caudal to the medial collateral ligament to allow access to, and sharp incision of, the medial aspect of the joint capsule proximal to the fan-shaped insertion of the biceps brachii/brachialis muscle complex on the medial aspect of the coronoid process. Self-retaining retractors positioned caudal to the medial collateral ligament maximize exposure of the medial joint compartment. We have employed an air-powered oscillating saw for ostectomy[28] but acknowledge that arthroscopically-guided ostectomy may also be achieved using an osteotome or motorized shaver with comparable efficacy.

The caudolateral boundary of the ostectomy is at the junction of the radial incisure and a point 1–2 mm distal to the sagittal ridge of the ulnar notch. Subchondral microfractures have been found extending to the edge of this osteotomy line,[6] but it includes the full extent of visible cartilage pathology and the region of subchondral

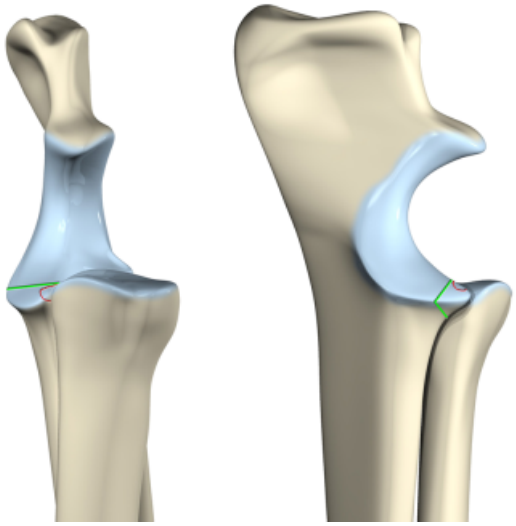

Fig 2. Typical configuration of subtotal coronoid ostectomy (SCO) depicted by green lines. Red line depicts typical location of fragment at radial incisure of medial aspect of coronoid process.

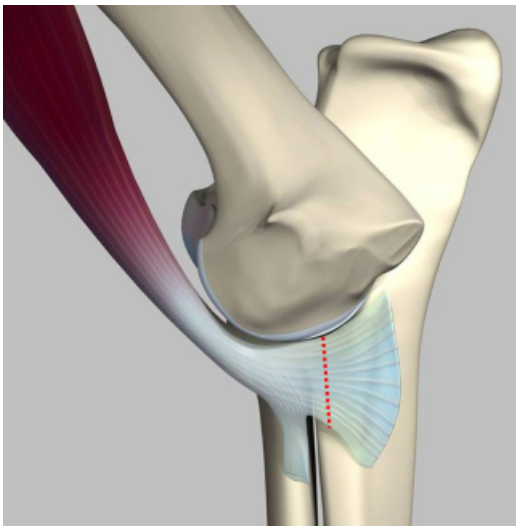

Fig 3. Typical configuration of biceps ulnar release procedure (BURP) depicted by red broken line. Note fan-shaped insertion of the biceps brachii immediately surrounding the medial aspect of the coronoid process.

pathology identified by histomorphometry.[6] Our initial concerns about elbow instability (because of reduced medial articular contact surface or disruption of the ulnar portion of the medial collateral ligament) have not been substantiated. SCO in 263 dogs (437 elbows) with long term follow-up (>5 years in some dogs), resulted in consistent and durable resolution of lameness with low surgical morbidity.[28]

Other surgical techniques for focal management of MCD include removal of free fragments alone, and varying degrees of debridement, abrasion, or excision of the visibly diseased portion of the medial aspect of the coronoid process, either arthroscopically or via arthrotomy.[4,14,17,40–44] Although histologic findings suggest that such approaches would leave a substantial portion of diseased subchondral bone in situ,[6] we are unaware of any clinical studies that clearly demonstrate that more aggressive arthroplasty (e.g. SCO) yields superior outcome to less aggressive approaches. A cohort comparison study is warranted.

If dynamic joint incongruency or abnormal dynamic loading are potential causes of MCD, then arguably, corrective ulnar osteotomy should be considered as a treatment approach; however, without better mechanical understanding, it is unclear what osteotomy configuration might be most beneficial. In our experience, ulnar osteotomy results in lameness of several weeks duration. Further, the severity of lameness is typically more than observed preoperatively or is associated with intraarticular procedures alone. This outcome seemingly counterbalances any potential benefits and at least in our experience, long-term outcome is equivocal in dogs with MCD without substantial humeral condylar pathology. However, when there are frictional abrasion lesions associated with the medial aspect of the humeral condyle or where definitive humeroradial incongruity is evident on CT or arthroscopic assessment, ulnar osteotomy may be justified as we describe later. We do not perceive a need for ulnar ostectomy unless >4 mm humeroradial incongruity is definitively identified.

When rotational instability with excessive supination loading force is suspected, we use a biceps ulnar release procedure (BURP; Fig 3) that involves tenotomy of the distal insertion of the biceps brachii/brachialis complex onto the ridge immediately caudal to the abaxial portion of the MCP.[34,35] Considering our proposed pathogeneses, dogs with focal subchondral pathology in the region of the radial incisure might be potential candidates for this procedure. Clinically, case selection is based either on presence of fissure formation in the region of the radial incisure without overt fragmentation or discernable osseous incongruity, or where there is a high index of suspicion that dynamic incongruity is the underlying cause of MCD. The latter cases are typically juvenile dogs with bilateral elbow pain/lameness and minimal arthroscopic changes bilaterally or with minimal arthroscopic changes affecting the elbow contralateral to an elbow overtly affected by fragmentation (e.g. synovitis, cartilage malacia, fibrillation or radial incisure fissuring). We have used this procedure before development of end-stage disease and although early outcomes have been encouraging with resolution of clinical signs and negligible morbidity,[35]

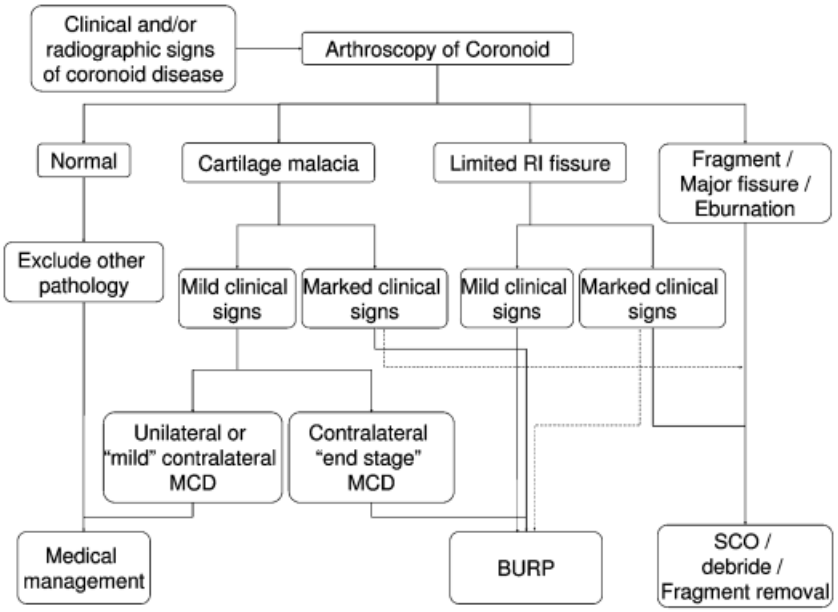

Fig 4. Decision making algorithm chart for treatment of medial coronoid disease (MCD) without significant medial humeral condylar pathology.

further investigation of indications and outcomes is needed before recommendations for clinical use are made. Biomechanical data will be necessary to determine if BURP reduces joint contact pressure associated with HUC. Whether BURP can alter disease progression, preventing cartilage disease or fissures of the MCP becoming fragmented or reducing persistent frictional abrasion of the medial compartment after SCO remains to be determined. Equally, it is unknown at this stage whether BURP may be used for successful palliative treatment of end-stage medial compartment erosion where periarticular fibrosis or profundity of pathology may negate the positive effects of tendon release.

Nonsurgical management remains the major alternative approach when focal surgical treatment is considered inappropriate or has already been performed without resolution of clinical signs. Successful nonsurgical management plans involve simultaneous use of a moderated exercise routine, body weight control, judicious use of nonsteroidal antiinflammatory medication or prescription analgesic agents, and use of nutraceuticals or disease modifying compounds (of which glucosamine and chondroitin sulfate containing preparations, or compounds such as pentosan polysulfate may hold most promise). Other adjunctive therapies should also be considered, including reduced load-bearing exercise (such as hydrotherapy), physical therapies such as massage, transcutaneous electrical nerve stimulation, shock wave therapy and holistic, magnetic and alternative therapies like acupuncture. There is limited scientific evidence to support use of many of these modalities but a wealth of cross-species experience and low morbidity may prompt their use in individual cases.

Decision Algorithm for MCD

Our current decision algorithm for the coronoid process (Fig 4) indicates SCO whenever end stage MCD, manifesting as either fragmentation, major fissuring, or full thickness eburnation of articular cartilage, is identified arthroscopically.

When early or mild MCD is identified arthroscopically, typically manifested as superficial cartilage fibrillation or cartilage malacia, frequently limited to the most craniomedial portion of the medial aspect of the coronoid process, other factors are considered before selecting SCO, BURP, or nonsurgical management. These factors are balanced in an attempt to answer 3 questions:

(1) Is the subchondral pathology a sufficiently important current cause of lameness or pain to justify SCO despite lack of superficial pathology?
(2) Do the arthroscopic findings suggest a rotational component manifested by pathologic changes in the region of the radial incisure, supporting use of BURP in an attempt to reduce supination forces acting on the joint?
(3) Is the current level of pathology likely to progress to end stage MCD with future lameness or pain if left untreated?

The 2 factors considered most important in affirming decision to perform SCO, in light of ambiguous ar-

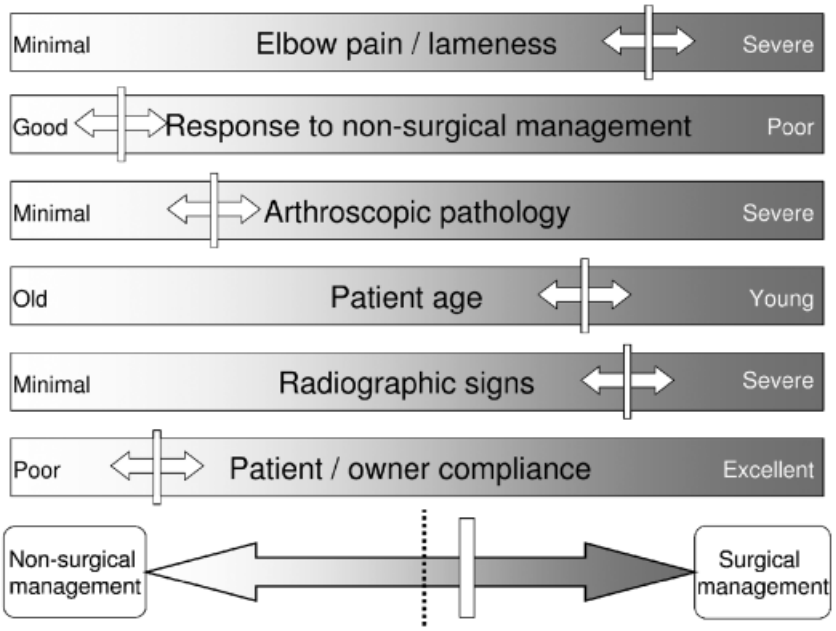

Fig 5. Schematic representation of sliding scale analogy applied to incorporate additional factors into decision-making algorithms for treatment of medial elbow disease.

throscopic findings, are severity of clinical signs (lameness and pain on manipulation) and young age (where skeletal immaturity is considered a strong indicator for subsequent development of end stage MCD). Radiographic findings (including subjective intensity of radiographic subtrochlear sclerosis), anticipated dog and owner compliance with nonsurgical management protocols, and response to previous attempts at nonsurgical management are also considered. As an example, using our algorithm, a 6-year-old dog with subtle clinical lameness or elbow pain, with superficial cartilage fibrillation focally at the tip of MCP would be managed nonsurgically, whereas a 6-month-old dog with moderate lameness associated with low-grade superficial disease of the medial coronoid evident arthroscopically and intense subtrochlear sclerosis evident radiographically would be treated by SCO or BURP depending on the degree of medial coronoid pathology in terms of fibrillation, fissuring, or fragmentation.

A sliding scale analogy may be most appropriate when trying to combine these variables (Fig 5) and therefore, a small degree of subjectivity may occur in selected cases. Ongoing studies to categorize and prioritize bone marrow lesions of the MCP by MRI and CT will undoubtedly help to deracinate this subjectivity. Cross-referencing radiographic and arthroscopic findings with micro-CT and histomorphometric analysis of excised coronoid segments will also help clarify the relationship between incongruity and morphologic changes and may help guide decision making in the future.

DISEASE OF THE MEDIAL HUMERAL CONDYLE

OC (and resultant OCD) is a well-recognized disease of the medial compartment of the elbow, and concomitance with MCD is frequent (30/33 elbows in one of our studies[45]). This may reflect a potential role for incongruity in the etiopathogenesis of both diseases, although numerous developmental factors have been implicated including genetic[46,47]; dietary[48]; growth rate[49]; and endocrine[50] factors. Many reports have grouped treatment of these 2 diseases together, and have not reflected the spectrum of pathology identified in our canine population.

Specifically, we have commonly recognized OCD in conjunction with varying degrees of cartilage erosion (kissing lesions) of the medial humeral condyle, apparently associated with MCD, further supporting the role of incongruity in etiopathogenesis. These kissing lesions are identifiable during arthroscopy or arthrotomy as clusters of axially-orientated, linear abrasion tracts/striations ranging from superficial cartilage fibrillation to full thickness cartilage eburnation with exposure of subchondral bone. There is also substantial variation in the surface area of the medial humeral condyle affected, ranging from focal regions a few millimeters in diameter, to eburnation across almost the entire medial articular surface. These lesions are often centered at or immediately adjacent to the OCD lesion, but remain distinct in both gross appearance and depth of subchondral defect. The medial aspect of the coronoid process inevitably

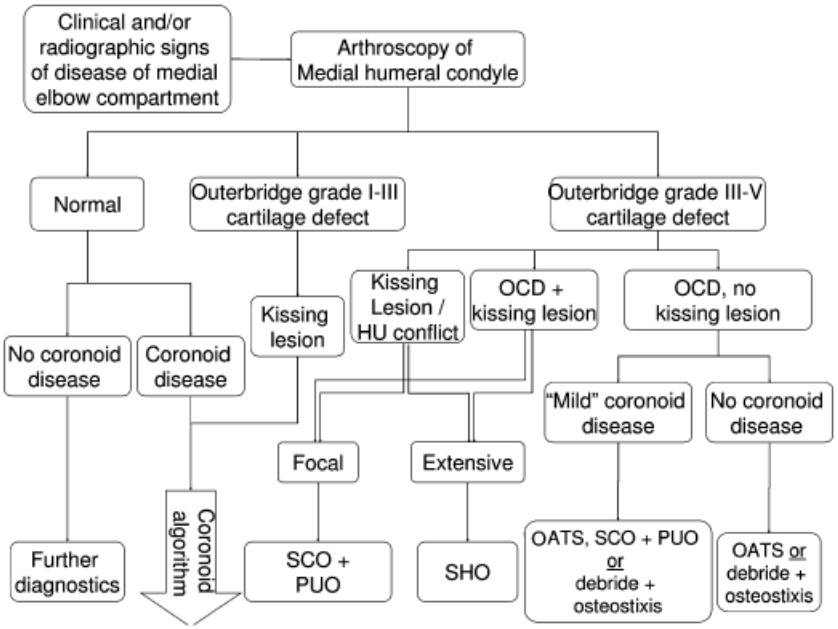

Fig 6. Decision-making algorithm for treatment of commonly identified manifestations of pathology of the medial humeral condyle.

demonstrates a similar degree of cartilage pathology across some portion of its surface (mirror-image), whereas additional presence of macroscopic fragmentation or fissuring, although common, is more variable.

Both surgical and nonsurgical management of OCD of the medial humeral condyle (with or without MCD) result in progression of osteoarthritis,[3] yet variation in prognostic outcome within the spectrum of identified disease and detailed medium- and long-term outcomes have typically not been reported. In our experience, presence of marked cartilage disease of the medial humeral condyle has been associated with relatively poor clinical outcomes and in some cases, even if MCD is simultaneously treated by SCO, may continue to progress with eventual full-thickness eburnation throughout the medial joint compartment.

Approximately equal load sharing between the larger humeroradial contact area and the smaller humeroulnar contact area in normal elbows[51] may account for the severity of some lesions. It is considered unlikely that fibrocartilaginous ingrowth from subchondral bone in this region (e.g. stimulated by local osteostixis) would provide any substantial or durable protection of the subchondral bone plate, particularly considering its load-bearing function, the persistent frictional environment, and any potential dynamic incongruity. This outcome has been supported by second-look arthroscopic observations in a number of cases treated by fragment removal, curettage, microfracture, or osteostixis alone.[24] Therefore, a range of treatments has been proposed to address these challenging lesions of the medial humeral condyle, resulting in a relatively complex decision making algorithm (Fig 6).[34,52]

OCD

When OCD is identified in the absence of MCD or a corresponding medial humeral condylar kissing lesion, treatment choice remains relatively straightforward. MCD is excluded primarily by arthroscopic findings (lack of cartilage malacia, fibrillation, fissuring or fragmentation); however, particularly in immature dogs where these manifestations of end stage MCD may not yet have developed despite substantial subchondral pathology, radiographic findings should also be considered, specifically a lack of subjectively profuse or intense sclerosis in the subtrochlear or subcoronoid region.[22,53] Conventional surgical treatments (including curettage, microfracture, micropick) aimed at stimulation of fibrocartilage ingrowth are still considered justified for treatment of small (typically <5 mm maximal diameter in medium- and large-breed patients), shallow (typically <1 mm subchondral bone depth defect) or abaxial lesions where prognosis is anecdotally considered to be relatively positive.

For treatment of more substantial lesions, either of large diameter or with a deep subchondral defect, regeneration of fibrocartilage has anecdotally been found to be inadequate for appropriate reconstruction of the articular contour. Two aspects are considered potential reasons for

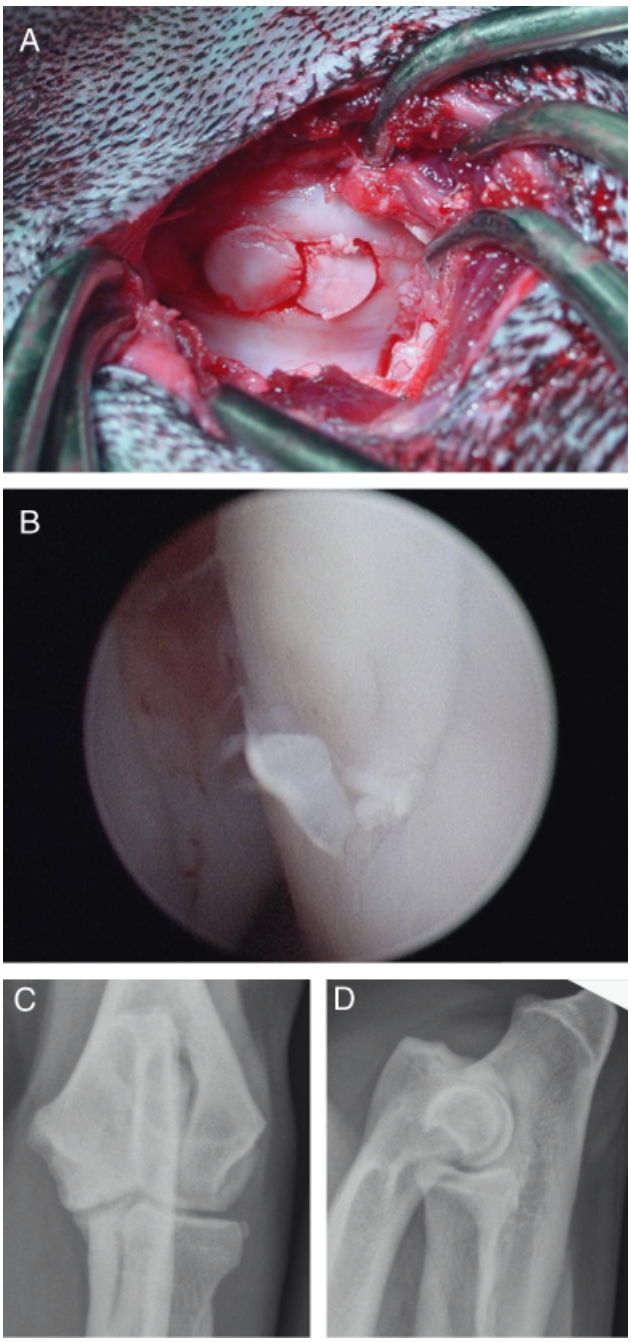

Fig 7. (A) Final appearance of 2 osteochondral cores in situ used to maximally cover elliptical osteochondral defect. Note that 2nd core overlaps position of 1st core to optimize cover of osteochondral defect. (B) 12 week postoperative arthroscopic image showing healthy cartilaginous appearance of OAT graft (right of image) for treatment of OCD lesion of medial humeral condyle without concomitant MCD. (C) Craniocaudal and (D) mediolateral radiographic projections of elbow of 3y 8 m Labrador Retriever treated 3 years earlier with OAT procedure for OCD of medial aspect of humeral condyle showing no progression of periarticular osteophytosis. OAT, osteochondral autograft transfer; OCD, osteochondritis dissecans; MCD, medial coronoid disease.

poor clinical outcomes. Firstly, it has been suggested that compared with hyaline cartilage, the mechanically inferior properties of fibrocartilage may result in a lack of durability in the medium- to long-term with eventual eburnation and reexposure of subchondral bone, and recurrence of lameness. Secondly, and perhaps more importantly, fibrocartilage is unlikely to be able to accurately restore an appropriate load-bearing contour, particularly when there are substantial defects of the subchondral bone plate. This may cause persistent rim stress concentration around the residual defect,[54] with resultant cartilage abrasion, subchondral bone edema, and lesions of the apposing articular surface, and although unproven for canine patients, may be the major cause of poor outcomes, particularly in joints like the elbow where a major portion of the limited load-bearing surface may be affected.

Reconstruction of the articular contour has become a major target for human osteochondral defect repair and a range of materials (autografts, allografts, resorbable and nonresorbable filler matrices) have been investigated. Of the procedures potentially available for clinical application, osteochondral autograft transfer (OAT) procedures are most readily applicable for use in dogs. OAT involves harvesting a cylindrical core of bone with an intact cap of healthy cartilage from a noncontact surface in another one of the dog's joints (typically the medial trochlear region of the stifle) and implanting this core into a socket created at the site of the osteochondral defect (Fig 7A). This procedure can both accurately restore articular and subchondral contour and create a durable hyaline or hyaline-like cartilage articular surface.[45] Using polyurethane "cartilage-substitute" filler-plugs would obviate the requirement for a donor site, decrease surgery time, and reduce challenges associated with topographical surface-mapping. Such procedures are the subject of ongoing evaluation and medium term (6 month) clinical, arthroscopic and MRI outcome measures are encouraging.[55]

Our clinical and arthroscopic outcomes in 3 elbows with OCD without identified MCD, and treated using autograft were excellent (Fig 7B), and radiographic and clinical follow-up to 3 years in 1 dog revealed no progression of osteoarthritis (Fig 7C and D).[45]

OCD and MCD

OCD has been most commonly identified in conjunction with MCD in the same joint. Treatment approach is then based on the severity of cartilage pathology present, affecting both the coronoid process and the medial humeral condyle around or adjacent to the OCD lesion. When MCD is identified in a joint with OCD of the

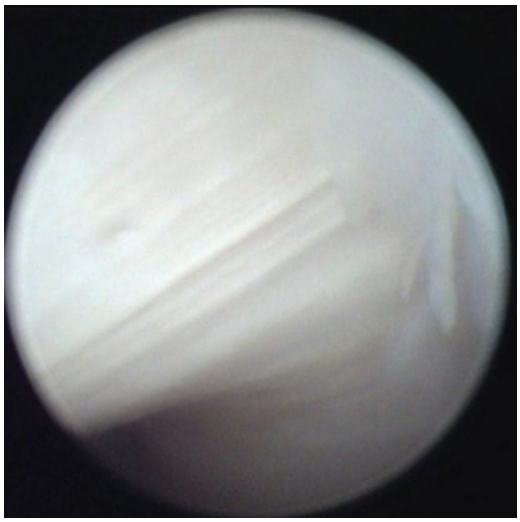

Fig 8. Typical appearance of focal modified Outerbridge grades 3–4 kissing lesion of medial humeral condyle demonstrating linear abrasion tracts.

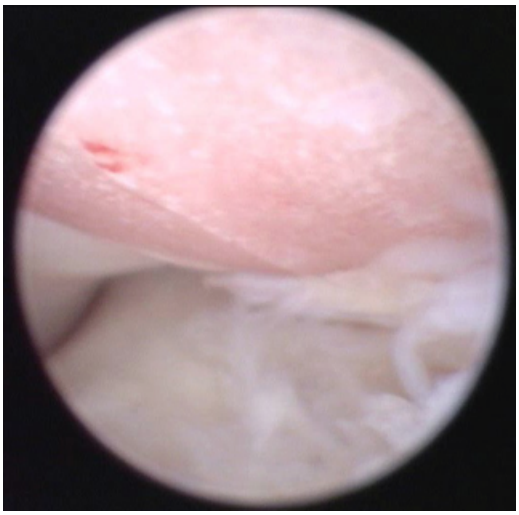

Fig 9. Full thickness (modified Outerbridge grade V) cartilage pathology throughout medial joint compartment with extensive exposure of subchondral bone.

medial humeral condyle, we consider SCO justified, almost without exception, irrespective of the severity of arthroscopic or radiographic pathology. This approach is based on our understanding of the role of incongruity or focally increased loading in the etiopathogenesis of both diseases that might compromise healing after any selected treatment method for the OCD lesion. We have yet to investigate the potential value of BURP in this regard.

These concerns were further supported by suboptimal outcomes in 10 of 24 elbows treated for concomitant MCD and OCD by SCO and OAT procedures.[45] Progression of cartilage pathology of the medial humeral condyle around the OAT graft site (and at the corresponding remaining medial ulnar articular contact region proximal to the SCO site) was observed at 12–18 week second-look arthroscopy. We consider this to be attributable to HUC[39] and on this basis, in a subsequent series of elbows affected by MCD and OCD without additional kissing lesions of the medial humeral condyle, we used a combination of OAT procedures, SCO, and proximal ulnar osteotomy (PUO). Clinical and second-look arthroscopic outcomes appear promising and incorporation of ulnar osteotomy in the treatment approach is currently considered responsible for contributing to this outcome.[45]

PUO. Whereas the optimal configuration, proximodistal orientation, and use of intramedullary stabilization when performing ulnar osteotomy have not been established clinically, we consider a number of features to be important. In an in vitro elbow incongruity model, it was shown that a distal ulnar osteotomy failed to restore articular congruity because of the strong interosseous ligament, whereas a more proximal osteotomy was more effective.[56] A caudoproximal to craniodistal oblique osteotomy has been recommended[2] to prevent extreme tilting of the proximal ulnar segment by the pull of the triceps brachii muscle at the olecranon, to minimize likelihood of delayed union of the osteotomy, and to reduce excessively abundant callus formation attributable to the inevitable instability at transverse osteotomy sites. Such instability can in some cases lead to nonunion in our experience.

In vitro limb loading of a caudoproximal to craniodistal oblique osteotomy without intramedullary fixation results in varus deformity. Whereas the implications of this have been suggested as being clinically insignificant,[57] prevention by intramedullary stabilization has been proposed,[58] but has been associated with some increase in morbidity (e.g. pin breakage).[58,59] We therefore used a PUO configuration, directed obliquely both caudoproximal to craniodistal ($\sim 40^\circ$ to the long axis), and proximolateral to distomedial ($\sim 50^\circ$ to the long axis).[45] Results of application of this osteotomy without an intramedullary pin for treatment of both HUC and conditions like UAP (with an interfragmentary self-compressing screw) have been encouraging, with reliable achievement of bony union without excessive callus formation, and with positive clinical outcomes.[60]

MCD and Focal Medial Humeral Condylar Kissing Lesion

As stated, we recommend that MCD is treated locally by SCO or BURP when identified. Where associated focal, partial thickness (modified Outerbridge grades 1–3) cartilage lesions are observed on the surface of the medial aspect of the humeral condyle, we consider SCO alone to provide adequate reduction in persistent frictional

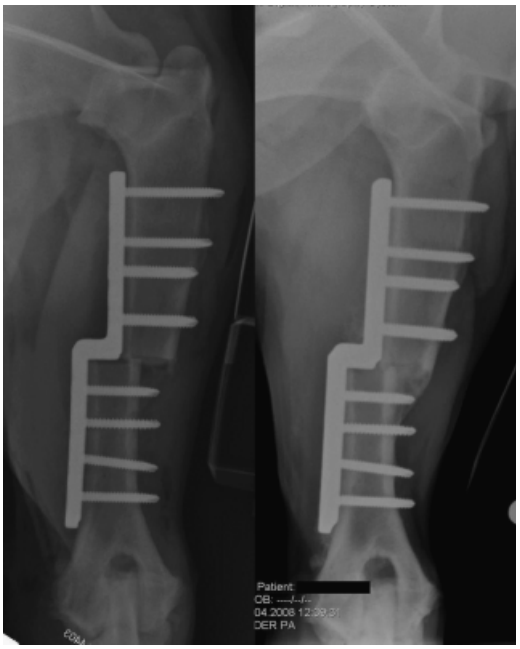

Fig 10. Radiographs of 7-year-old Labrador retriever with medial compartment syndrome treated by Sliding Humeral Osteotomy immediate postoperatively (left image) and 6 months later (right image).

Fig 11. Arthroscopic image of elbow of 2-year-old Rottweiler 12 months after SHO. Medial humeral condyle has complete fibrocartilage cover of previously eburnated subchondral bone. Lateral joint compartment remains visibly undiseased. SHO, sliding humeral osteotomy.

abrasion or HUC to support positive clinical outcomes. Where these lesions are recognized in the same joint as an OCD lesion, treatment of the OCD lesion by OAT procedures can still considered appropriate, but ancillary SCO and PUO are critical to achieving a positive outcome.

Where focal, deeper (modified Outerbridge grades 3–5) cartilage lesions are identified on the surface of the medial aspect of the humeral condyle (Fig 8), we consider that SCO is unlikely to provide adequate reduction in the distomedial ulnar contact surface for appropriate amelioration of persistent HUC. In this relatively uncommon circumstance, adjunctive PUO as described has provided favorable clinical and arthroscopically evaluated outcomes in some dogs. Whereas treatment of concomitant OCD lesions by OAT procedures should be considered, it may be difficult to adequately resurface the affected medial aspect of the humeral condyle as the lesions do not have discrete edge margins, unlike isolated solitary lesions of OCD.

MCD and Extensive Medial Humeral Condylar Kissing Lesion

In some dogs, MCD is associated with severe lesions attributable to HUC. The typical appearance is full thickness (modified Outerbridge grade 4–5) cartilage pathology across the major portion of the medial joint compartment, affecting both the medial humeral condyle and the corresponding distomedial ulnar contact area (Fig 9). These dogs invariably have severe lameness and manifest marked pain on elbow manipulation. Lameness has typically been present for several months, even when occurring in skeletally immature dogs. In this circumstance, long-term prognosis is considered to be severely guarded after medical management or local surgical treatment. Even if any underlying incongruity could be reliably addressed by techniques like PUO or BURP, formation of a durable barrier between synovial fluid and subchondral bone by fibrocartilage infilling, or reconstruction of an appropriate articular contour are considered highly improbable because of the severity of preexisting changes. Therefore such techniques may fail to address pain or lameness in dogs suffering from end-stage disease of the medial compartment.

Such severe unicompartmental arthroses are commonly identified in the human knee, and focal treatments have resulted in poor outcomes. Human unicompartmental gonioarthrosis has been treated using closing wedge osteotomies for over 40 years[61,62] and efficacy by transfer of load bearing forces away from the diseased joint compartment toward a region of more healthy cartilage is well accepted. Unicompartmental joint replacement in the canine elbow may hold promise but has not yet advanced beyond prototype investigation.

Therefore in this scenario, we recommend use of sliding humeral osteotomy (SHO; Fig 10). In vitro studies have demonstrated the efficacy of humeral osteotomies in transferring load bearing forces toward the relatively

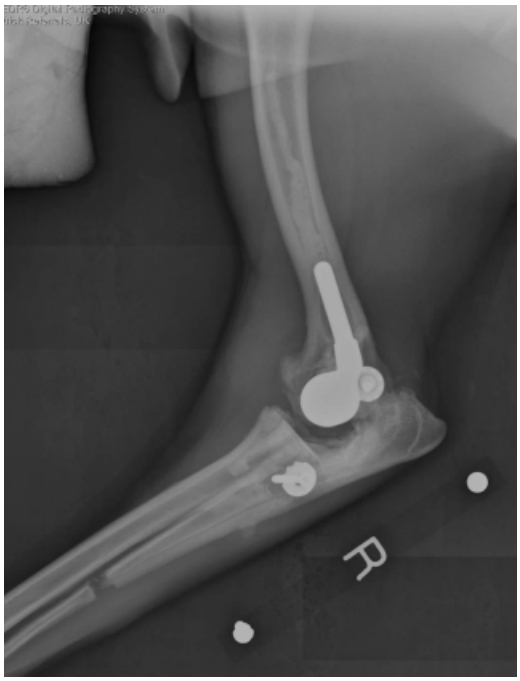

Fig 12. Mediolateral radiograph showing typical postoperative appearance after total elbow arthroplasty using a metal-on-polyethylene prosthesis.

healthy lateral joint compartment,[63,64] with force at the proximal articular surface of the ulna being decreased after SHO of 4 and 8 mm by 25% and 28% respectively.[64] Outcomes of clinical application in 59 elbows have been positive, and arthroscopic (Fig 11) and histologic documentation of novel fibrocartilaginous cover of previously eburnated regions has been achieved.[65,66] This

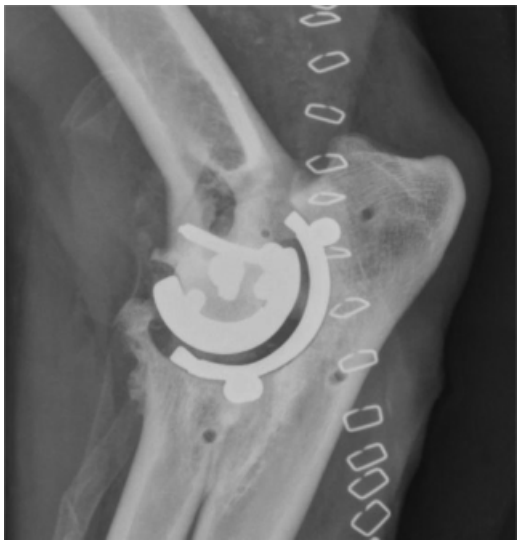

Fig 13. Mediolateral radiograph showing typical postoperative appearance after elbow arthroplasty using the TATE™ prosthesis.

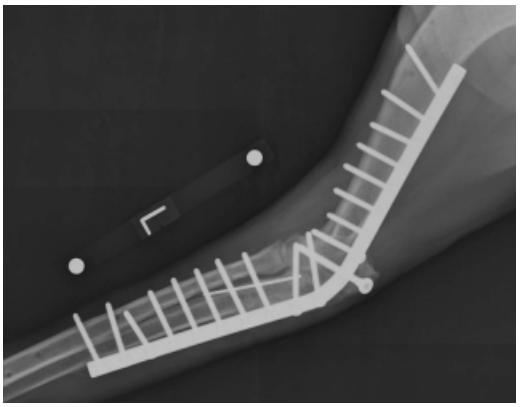

Fig 14. Mediolateral radiograph showing typical postoperative appearance after elbow arthrodesis.

is not functional articular cartilage but does provide some evidence of efficacious unloading of the medial compartment.

Whereas morbidity associated with recent developments in technique and implant design has been minimized, we have thus far used SHO as a salvage procedure, reserved for cases where genuine attempts at nonsurgical or other surgical management have failed. However, in selected very young dogs affected by full-thickness cartilage erosion or osteochondral deficits of the medial compartment and severe clinical debilitation, there is an argument for early intervention with SHO. There is evidence that quality of life of these dogs can be markedly improved and sustained long-term (3 years in our cases to date).[65,66] Proactive preoperative owner counseling and judicious patient selection are strongly advised.[65]

Global Elbow Arthrosis

In some dogs, both medial and lateral joint compartments may be severely diseased, with extensive eburnation of cartilage and subchondral bone of all major articular structures. Chronic lesions associated with MCD and/or elbow incongruity are frequently responsible, although some cases may have previous documentation of concomitant OCD lesions or other pathologies such as articular fractures and erosive arthropathies.

In this circumstance, salvage procedures like total elbow arthroplasty (TEA; Figs 12 and 13) or joint arthrodesis (Fig 14) may represent the only viable options for restoration of comfortable limb function. Whereas elbow arthrodesis may provide marked improvement in comfort for dogs with severe degenerative joint disease, substantial functional lameness inevitably persists with limb circumduction and potential associated disability. TEA is

widely considered to be preferable to arthrodesis; however, the high incidence of morbidity and prolonged convalescence associated with currently available implant and instrumentation systems are of concern.[67] Novel implant systems (several of which are the subject of ongoing research), like the TATE system[68] may lessen these concerns but long term clinical outcome data is not yet available.

Summary

We report our current decision making algorithms for management of diseases of the medial compartment of the canine elbow. These algorithms are based on our understanding of and hypotheses regarding the etiopathogenesis of MCD, have been refined based on our clinical experience and will undoubtedly be further refined and revised with improved understanding of this complex cornucopia of pathologic changes in dysplastic canine elbows. The algorithms do create a framework for further investigative work and optimization of treatment protocols. From our perspective, a number of actions are required to achieve continued improvement:

Veterinary Education is key if advances are to be made. It is vital that we achieve broad agreement on qualitative and descriptive terminology used to refer to commonly identified manifestations of the range of syndromes affecting the canine elbow.

Deconstruct—We propose that the terminology elbow dysplasia be deconstructed and replaced with appropriate descriptive nomenclature for the recognized subcomponents. Such terminology should be cautiously applied to be appropriately inclusive e.g. MCD rather than fragmented coronoid process.

Redefine—Description of individual cases or groups of patients should include objective or quantitative features that are anticipated to be of prognostic value (such as "tip" versus "radial incisure" fragmentation of the medial aspect of the coronoid process, modified Outerbridge scores across the major articular contact surface zones, use of numerical subjective lameness scores) until proven otherwise.

Record—Recording of such information in all clinical cases by using a standardized elbow joint evaluation form that would result in a more consistent and reproducible reporting of these details in the peer-reviewed literature.

Reeducate—education of owners is also of major importance, if only to generate more realistic owner expectations regarding likely prognosis in individual cases, which can be expected to vary widely across the known range of disease manifestations. Owners frequently have no perception of the spectrum of pathology currently categorized as elbow dysplasia. In our experience, owners frequently and erroneously attempt understanding of the elbow disease process as akin to hip dysplasia, which most are aware of. We regularly use written information sheets which are provided to owners preoperatively and describe a simplified list of the possible degrees of "severity" for each disease subtype with possible treatment and prognostic parameters. This has the additional benefits of emphasizing the importance of postoperative care compliance and helping to establish informed consent, which is essential for less traditional procedures where complication incidence or severity might be less well defined.

Ongoing and continuous evaluations of current and future treatments are essential to development of a decision-making algorithm.

Feasibility—Whereas most modalities described here now have sufficient data to establish that they are clinically viable and that morbidity is sufficiently low to consider further development, biomechanical and controlled in-vivo testing will be key to validation and in some cases necessary for the introduction of newer modalities of treatment. For example, there may be an argument to use a technology like cartilage transplantation where outcomes for conventional debridement of OCD lesions may be considered poor, but ethical implications and requirements of the definition of "evidence-based-medicine" must be considered paramount, both when introducing a novel treatment modality and when introducing an existing treatment modality to a novel patient group.

Efficacy—For many treatments, the level of evidence to support their clinical application remains relatively limited and more detailed efficacy studies are needed. Whereas subjective assessments such as clinical lameness evaluation and owner perceptions of function can provide useful data, they may be strongly subject to sources of possible bias, and where available, more objective measures such as force-plate or kinematic analysis may provide more objective outcome measures.

Comparison—Within this framework, the potential exists not only to perform comparison studies between available techniques within clinical patient populations, but also to perform comparisons against more conventional treatment methods and subsequently developed novel therapies. Such cohort studies can then be applied to refine the current treatment algorithm, not only by inclusion or exclusion of certain therapies, but also with more accurate definition of patient selection criteria and prognostic factors.

Review—We must avoid using parameters which we can quantitatively measure as the sole determinant of therapeutic intervention. For example, CT studies comparing medial coronoid apex/base measurements of humeroulnar incongruity may be less important in elucidating etiopathogenesis or directing the treatment of tip/radial incisure fragmentation than observations which may derive from studies on the dynamic model of elbow incongruity associated with musculotendinous/osseous mismatch. As a byproduct of their relative success or failure, clinical and biomechanical studies of the efficacy of a range of treatment methods can be anticipated to yield information regarding the etiopathogenic hypotheses and even the diagnostic imaging modalities around which the respective therapies are directed, furthering our clinical understanding of the complex spectrum of disease.

We anticipate that through these actions, we can improve our understanding and ability to treat this complex and challenging spectrum of elbow diseases, and by doing so, make a contribution to our ultimate goal for achieving optimal outcomes for our canine patients.

REFERENCES

1. Walker TM: A redefined type of elbow dysplasia in the dog—two cases. Can Vet J 39:573–575, 1998
2. Samoy Y, Van Ryssen B, Gielen I, et al: Elbow incongruity in the dog—review of the literature. Vet Comp Orthop Traumatol 19:1–8, 2006
3. Bouck GR, Miller CW, Taves CL: A comparison of surgical and medical treatment of fragmented coronoid process and osteochondritis dissecans of the canine elbow. Vet Comp Orthop Traumatol 8:177–183, 1995
4. Huibregtse BA, Johnson AL, Muhlbauer MC, et al: The effect of treatment of fragmented coronoid process on the development of osteoarthritis of the elbow. J Am Anim Hosp Assoc 30:190–195, 1994
5. Meyer-Lindenberg A, Fehr M, Nolte I: Co-existence of ununited anconeal process and fragmented medial coronoid process of the ulna in the dog. J Small Anim Pract 47:61–65, 2006
6. Danielson KC, Fitzpatrick N, Muir P, et al: Histomorphometry of fragmented medial coronoid process in dogs: a comparison of affected and normal coronoid processes. Vet Surg 35:501–509, 2006
7. Macpherson GC, Lewis DD, Johnson KA, et al: Fragmented coronoid process associated with premature distal radial physeal closure in four dogs. Vet Comp Orthop Traumatol 5:93–99, 1992
8. Wind AP: Elbow incongruity and developmental elbow disease in the dog: part II. J Am Anim Hosp Assoc 22:725–730, 1986
9. Padgett GA, Mostosky UV, Probst CW, et al: The inheritance of osteochondritis dissecans and fragmented coronoid process of the elbow joint in Labrador retrievers. J Am Anim Hosp Assoc 31:327–330, 1995
10. Janutta V, Hamann H, Klein S, et al: Genetic analysis of three different classification protocols for the evaluation of elbow dysplasia in German shepherd dogs. J Small Anim Pract 47:75–82, 2006
11. Gemmill TJ, Clements DN: Fragmented coronoid process in the dog: is there a role for incongruency? J Small Anim Pract 48:361–368, 2007
12. Innes JF: Outcomes-based medicine in veterinary surgery: levels of evidence. Vet Surg 36:610–612, 2007
13. Kapatkin AS: Outcome-based medicine and its application in clinical surgical practice. Vet Surg 36:515–518, 2007
14. Bennett D, Duff SRI, Kene RO, et al: Osteochondritis dissecans and fragmentation of the coronoid process in the elbow joint of the dog. Vet Rec 109:329–336, 1981
15. Olsson SE: The early diagnosis of fragmented coronoid process and osteochondritis dissecans of the canine elbow joint. J Am Anim Hosp Assoc 19:616–626, 1983
16. Haudiquet PR, Marcellin-Little DJ, Stebbins ME: Use of the distomedial-proximolateral oblique radiographic view of the elbow joint for examination of the medial coronoid process in dogs. Am J Vet Res 63:1000–1005, 2002
17. Henry WB: Radiographic diagnosis and surgical management of fragmented medial coronoid process in dogs. J Am Vet Med Assoc 184:799–805, 1984
18. Holsworth IG, Wisner ER, Scherrer WE, et al: Accuracy of computerized tomographic evaluation of canine radioulnar incongruence in vitro. Vet Surg 34:108–113, 2005
19. Schwarz T, Johnson VS, Voute L, et al: Bone scintigraphy in the investigation of occult lameness in the dog. J Small Anim Pract 45:232–237, 2004
20. Snaps FR, Balligand MH, Saunders JH, et al: Comparison of radiography, magnetic resonance imaging, and surgical findings in dogs with elbow dysplasia. Am J Vet Res 58:1367–1370, 1997
21. Punke J, Hulse DA, Budsberg SC: Elbow pathology without radiographic changes in dogs. *Proceedings of ECVS 16th Annual Scientific Meeting*, Dublin, Ireland. June 28–30, pp 377–378, 2007.
22. Smith T, Fitzpatrick N, Evans R, et al: Measurement of ulnar subtrochlear sclerosis using a percentage scale in labrador retrievers with minimal radiographic signs of periarticular osteophytosis. Vet Surg 38:199–208, 2009
23. Meyer-Lindenberg A, Langhann A, Fehr M, et al: Prevalence of fragmented medial coronoid process of the ulna in lame adult dogs. Vet Rec 151:230–234, 2002
24. Fitzpatrick N, Smith T, Evans R, et al: Radiographic and arthroscopic findings in the elbow joints of 263 dogs with medial coronoid disease. Vet Surg 38: 213–223, 2009
25. Clements DN, Fitzpatrick N, Carter SD, et al: Cartilage gene expression correlates with radiographic severity of canine elbow osteoarthritis. Vet J, 2007 Oct 13 [Epub ahead of print]
26. Cogan SM, Cook CR, Curry SL, et al: Prospective evaluation of techniques for differentiating shoulder pathology as a

source of forelimb lameness in medium and large breed dogs. Vet Surg 37:132–141, 2008
27. Moores AP, Benigni L, Lamb CR: Computed tomography versus arthroscopy for detection of canine elbow dysplasia lesions. Vet Surg 37:390–398, 2008
28. Fitzpatrick N, Smith T, Evans R, et al: Subtotal coronoid ostectomy for treatment of medial coronoid disease in 263 dogs. Vet Surg Vet Surg 38: 233–245, 2009
29. Fitzpatrick N, Reuter R: Histopathology of cartilage and subchondral bone following subtotal coronoidectomy (SCO) for the treatment of fragmented medial coronoid process. Proceedings of BSAVA Congress, Clinical Research Abstracts. Birmingham, UK, April 1–4, p 586, 2004
30. Collins K, Cross A, Lewis DD, et al: Comparison of the radius of curvature of the ulnar trochlear notch of Rottweilers and Greyhounds. Am J Vet Res 62:968–673, 2001
31. Fitzpatrick N: Subtotal coronoid ostectomy (SCO) for the treatment of medial coronoid disease: a prospective study of 228 dogs (389 elbows) evaluating short and medium term outcome. BVOA Autumn Scientific Meeting—Enigmas of the Canine Elbow, November 17–19, Chester, UK, pp 22–29, 2006
32. Hulse D: Anthology of observations. *Proceedings of ACVS Symposium*, Chicago IL. October, pp 249–253, 2007
33. Hulse D: Co-contraction of the biceps/brachialis muscle complex produces a rotational moment which may induce fragmentation/microfracture of the medial coronoid. *Proceedings of ACVS Symposium*, San Diego, CA, October 23–25, pp 466, 2008
34. Fitzpatrick N: Elbow dysplasia: new horizons and treatment algorithms. *3rd annual meeting of the Veterinary Arthrology Advancement Association*, Naples FL, 21–22 August, 2008
35. Fitzpatrick N: Biceps ulnar release procedure for treatment of medial coronoid disease in 49 elbows. *Proceedings of 36th Annual Conference*, Veterinary Orthopaedic Society, Steamboat Springs Colorado, February 28–March 7, p 44, 2009
36. Williams SB, Wilson AM, Daynes J, et al: Functional anatomy and muscle moment arms of the thoracic limb of an elite sprinting athlete: the racing greyhound (*Canis familiaris*). J Anatomy 213:373–382, 2008
37. Hulse DA: Disease of the medial coronoid process, *Proceedings of 1st Annual Arthroscopy and Orthopaedics Symposium and Laboratory*, Naples, FL, August 25–26, 2006
38. Wolschrijn CF, Gruys E, Weijs WA: Microcomputed tomography and histology of a fragmented medial coronoid process in a 20-week-old golden retriever. Vet Rec 157:383–6, 2005
39. Olivieri M: Preliminary results of arthroscopic diagnosis and treatment of elbow humero-ulnar conflict (cartilage erosion) through proximal ulnar osteotomy. *Proceedings of 13th European Society of Veterinary Orthopaedics and Traumatology Congress*, Munich, Germany, pp 257–258, September 2006
40. Read RA, Armstrong SJ, O'Keef D, et al: Fragmentation of the medial coronoid process of the ulna in dogs: a study of 109 cases. J Small Anim Pract 31:330–334, 1990
41. Grondalen J: Arthrosis in the elbow joint of young rapidly growing dogs. I. Ununited medial coronoid process of the ulna and osteochondritis dissecans of the humeral condyle. Nord Veterinaermed 31:520–527, 1979
42. Grondalen J: Arthrosis with special reference to the elbow joint of rapidly growing dogs. II. Occurrence, clinical and radiographic findings. Nord Veterinaermed 31:69–75, 1979
43. Boudrieau RJ, Hohn RB, Bardet JF: Osteochondrosis dissecans of the elbow in the dog. J Am Anim Hosp Assoc 19:627–635, 1983
44. Tobias TA, Miyabayashi T, Olmstead ML, et al: Surgical removal of fragmented medial coronoid process in the dog: comparative effects of surgical approach and age at time of surgery. J Am Anim Hosp Assoc 30:360–368, 1994
45. Fitzpatrick N, Yeadon R, Smith T: Early clinical experience with osteochondral autograft transfer (OAT) for treatment of osteochondritis dissecans (OCD) of the medial humeral condyle in dogs. Vet Surg 38:246–260, 2009
46. Guthrie S, Pidduck HG: Heritability of elbow osteochondrosis within a closed population of dogs. J Small Anim Pract 31:93–96, 1990
47. Hedhammar A: Genetic aspects of elbow dysplasia and efficacy of breeding programmes. *Proceedings of 23rd annual meeting of the International Elbow Working Group*, Dublin, 20 August, pp 24–26, 2008
48. Slater MR, Scarlett JM, Donoghue S, et al: Diet and exercise as potential risk factors for osteochondritis dissecans in dogs. Am J Vet Res 53:2119–2124, 1992
49. Hedhammer A, Wu FM, Krook L, et al: Overnutrition and skeletal disease. An experimental study in growing great dane dogs. Cornell Vet 64(Suppl 15): 1–160, 1974
50. Paatsama S, Rokkanen P, Jussila J, et al: Somatotropin, thyrotropin and corticotrophin hormone-induced changes in the cartilages and bones of the shoulder and knee joint in young dogs. An experimental study using histologic OTC bone labeling and microradiographic methods. J Small Anim Pract 12:595–601, 1971
51. Mason DR, Schulz KS, Fujita Y, et al: In vitro force mapping of the normal canine humero-radial and humero-ulnar joints. Am J Vet Res 66:132–135, 2005
52. Fitzpatrick N, Yeadon R: Algorithm for treatment of developmental diseases of the medial elbow in dogs. *Proceedings of 23rd annual meeting of the International Elbow Working Group*, Dublin, 20 August, pp 24–26, 2008
53. Burton NJ, Comerford EJ, Bailey M, et al: Digital analysis of ulnar trochlear notch sclerosis in Labrador retrievers. J Small Anim Pract 48:220–224, 2007
54. Guettler JH, Demetropoulos CK, Yang KH, et al: Osteochondral defects in the human knee: influence of defect size on cartilage rim stress and load redistribution to surrounding cartilage. Am J Sports Med 32:1451–1458, 2004
55. Fitzpatrick N: Synthetic osteochondral transplant for treatment of osteochondritis dissecans of the canine elbow, stifle and shoulder with arthroscopic and MRI outcome measures. *Proceedings of 36th Annual Conference, Veterinary Orthopaedic Society*, Steamboat Springs Colorado, February 28–March 7, p 7, 2009

56. Preston CA, Schulz KS, Taylor KT, et al: In vitro experimental study of the effect of radial shortening and ulnar ostectomy on contact patterns in the elbow joint of dogs. Am J Vet Res 62:1548–1556, 2000
57. Bardet JF, Bureau S: La fragmentation du processus coronoide chez le chien. Prat Med Chir Anim 31:451–463, 1996
58. Ness MG: Treatment of fragmented coronoid process in young dogs by proximal ulnar osteotomy. J Sm Anim Pract 39:15–18, 1998
59. Vezzoni A: Surgical treatment of elbow dysplasia: technique and follow-up. *Proceedings of 13th Annual Meeting IEWG*, Granada, October pp 18–24, 2003
60. Fitzpatrick N, Farrell M, O'Riordan J, et al: Application of a self compressing headless variably pitched cannulated screw for treatment of ununited anconeal process in dogs. *Proceedings of 33rd Annual Veterinary Orthopedic Society meeting and 2nd World Veterinary Orthopaedic Congress*, Keystone, CO, February 25–March 4, p 206, 2006
61. Ackroyd CE: Medial compartment arthroplasty of the knee. J Bone Jt Surgery [Br] 85:937–942, 2003
62. Koshino T, Yoshida T, Ara Y, et al: Fifteen to twenty-eight years' follow-up results of high tibial valgus osteotomy for osteoarthritic knee. Knee 11:439–44, 2004
63. Fujita Y, Schulz KS, Mason DR, et al: Effect of humeral osteotomy on joint surface contact in canine joints. Am J Vet Res 64:506–511, 2003
64. Mason DR, Schulz KS, Fujita Y, et al: Measurement of humeroradial and humeroulnar transarticular joint forces in the canine elbow joint after humeral wedge and humeral slide osteotomies. Vet Surg 37:63–70, 2008
65. Fitzpatrick N: Initial clinical experience with sliding humeral osteotomy for treatment of medial compartment disease of the canine elbow. *Proceedings of ACVS Symposium*, San Diego, CA, October 23–25, pp 249–254, 2008
66. Fitzpatrick N, Yeadon R, Smith T, et al: Techniques of application and initial clinical experience with sliding humeral osteotomy for treatment of medial compartment disease of the canine elbow. Vet Surg 38:261–278, 2009
67. Conzemius MG, Aper RL, Corti LB: Short-term outcome after total elbow arthroplasty in dogs with severe, naturally occurring osteoarthritis. Vet Surg 32:545–552, 2003
68. Acker R: TATE elbow preliminary trials. *Proceedings of 35th Annual Conference, Veterinary Orthopaedic Society*, Big Sky, Montana, March 9–14, p 8, 2008

Predictive Variables for Complications after TPLO with Stifle Inspection by Arthrotomy in 1000 Consecutive Dogs

Noel Fitzpatrick[1] DUniv MVB CertSAO & VR, and Miguel Angel Solano[1] DVM

[1]Fitzpatrick Referrals, Eashing, UK

Corresponding Author
Dr. Noel Fitzpatrick, Fitzpatrick Referrals, Halfway Lane, Eashing, Surrey GU7 2QQ, UK
E-mail: noel@fitzpatrickreferrals.co.uk

Submitted April 2009
Accepted January 2010

DOI:10.1111/j.1532-950X.2010.00663.x

Objective: To evaluate risk factors for complications, including meniscal injury and infection, after tibial plateau leveling osteotomy (TPLO) in dogs.
Study Design: Retrospective case series.
Sample Population: Dogs (n = 1000; 1146 stifles) with cranial cruciate ligament (CCL) rupture that had TPLO.
Methods: Medical records (January 2004–March 2009) were reviewed for dogs operated sequentially by medial arthrotomy with instrumented meniscal inspection (IMI) and TPLO by a single experienced surgeon. Multiple logistic regression models were used to evaluate independent contribution of risk factors to the recorded complications.
Results: Overall complication rate was 14.8%, of which 6.6% were major complications. Incidence of primary meniscal injury (PMI) was 33.2%, and subsequent meniscal injury (SMI) 2.8%. Postoperative infection occurred in 6.6% dogs. Bilateral CCL rupture was diagnosed in 14.6% dogs and no statistically significant complication incidence difference was recorded for simultaneous or staged bilateral surgical procedures. Administration of postoperative antibacterial therapy and being a Labrador reduced infection incidence, whereas increased body-weight and being an intact male increased infection risk. Increased body-weight and complete (versus partial) CCL rupture were significant predictors of overall complications.
Conclusions: Incidence of SMI recorded in this study is similar to that reported previously involving arthroscopic meniscal inspection at time of TPLO. Infection was the single most important complication and antibiotic therapy was protective. Complication rate did not differ between bilateral simultaneous or staged procedures.
Clinical Relevance: Complication rate after TPLO with arthrotomy and IMI is lower than previously reported, bilateral simultaneous TPLO is reasonable, and incidence of major complications compares favorably with general orthopedic procedures.

Rupture of the cranial cruciate ligament (CCL) is one of the most common causes of pelvic limb lameness in dogs.[1,2] The CrCL is an important stabilizer of cranial displacement of the tibia, prevents hyperextension of the joint, and internal rotation of the tibia, and opposes cranial tibial thrust resulting from forces generated by muscle contraction and external ground reaction forces during the weight bearing phase.[3,4] Instability, because of partial or complete CCL rupture, can cause or occur concomitantly with inflammation, cartilage degradation and meniscal injuries, leading to development of osteoarthritis.[5–8] Diverse causal factors have been described, though it is generally accepted that CCL rupture is primarily a degenerative phenomenon in dogs.[3,9–12] Thus, concomitance of biologic and biomechanical factors is acknowledged and both are inextricably contributory to the inexorable deterioration of stifle joint function. Slocum and Slocum[13] proposed that cranial tibial thrust magnitude was a major component of instability and was related to tibial plateau angle (TPA). A tibial plateau leveling osteotomy (TPLO) technique was developed to convert the cranial tibial thrust force into a joint compressive force, addressing this component of instability, with the objective of resolution of pain and lameness without replacing the ligament itself.

Several studies in dogs have evaluated complications after TPLO surgery, the most frequently reported of which include tibial tuberosity fracture or avulsion, patellar tendonitis, implant related problems, postliminary or subsequent meniscal injury (SMI) and infections.[14–19] Bilateral CCL rupture has been reported to occur in as many as 31%

Veterinary Surgery 39 (2010) 460–474

of dogs with CCL injury.[20] Published accounts pertaining to risk of complications when bilateral simultaneous TPLO was performed are not consistent, casting some doubt as to whether this approach should be recommended or cautioned against.[14,21,22] Neoplasia associated with the TPLO surgical site and implants has also been documented.[23]

SMI, a common cause of lameness after TPLO, could be related to failure to effectively neutralize cranial tibial thrust[13] or to recognize and appropriately treat primary meniscal injury (PMI) at the time of TPLO.[24] The caudal pole of the medial meniscus acts as a wedge between the femoral and tibial condyles and may become crushed during cranial tibial translation.[25] Medial meniscal release (MMR) has been recommended based on putative biomechanical advantage to mitigate SMI,[16,26] but is not completely protective[24] and results in exacerbation of medial joint compartment loading.[27,28] Furthermore, efficacy or proficiency of ability to thoroughly examine meniscal structures during arthrotomy has been questioned. In an "ex vivo" study it has been deduced that sensitivity and specificity for detection of meniscal tears by arthroscopic evaluation with probe-inspection of the menisci is superior to arthrotomy with or without probing.[27]

Infections associated with TPLO occur more frequently than for other clean surgical procedures but predicating factors remain elusive.[15–17,29] Treatment protocols and decision making algorithms have not yet been established for infection after TPLO, including whether implant removal is universally or selectively required for resolution.

Our objective was to report complications associated with consecutive TPLO surgeries performed in 1000 dogs by a single surgeon (N.F.) and to elucidate and examine associated predictive variables. All surgeries were performed by medial parapatellar arthrotomy with assiduous IMI and removal of the entire CCL where either complete or partial disruption was grossly apparent. Specific objectives were to determine: (1) if bilateral simultaneous TPLO had a higher complication rate compared with staged bilateral TPLO; (2) if breed was a predictive variable for bilateral CCL rupture; (3) if PMI occurrence was influenced by body weight, breed, TPA, sex, age, whether CCL rupture is partial or complete and duration of lameness preoperatively; (4) if the incidence of SMI after arthrotomy with visual inspection and palpation of the medial meniscus assisted by cranial tibial traction would exceed that reported for arthroscopically assisted TPLO; and (5) if infection rate was influenced by body weight, breed, sex, age, implant type, type of postoperative bandage, body temperature, operative time, anesthesia time or provision of postoperative antibacterial therapy.

MATERIALS AND METHODS

Data Collection

Consecutive medical records (January 2004–March 2009) of 1000 dogs (1146 stifles) that had TPLO for CCL rupture were reviewed. Records were selected chronologically and sequentially starting with March 2009 and working backwards until 1000 dogs were identified. For dogs that had bilateral TPLO, 1 stifle was randomly selected by means of a coin-toss and used for statistical multivariate analysis within the wider population group, to assure the independence and the reliability of the statistical results. However, data from bilateral stifles was included for statistical comparison of single-session and staged bilateral procedures. A minimum of 6 months available follow-up determined the March 2009 cut-off. All TPLO surgeries were performed by a single surgeon (N.F.) who had performed $>$ 1000 TPLO procedures before January 2004 and thus was familiar with technique application on a daily basis with a large caseload over $>$ 5 years, including consistent reproducible use of instrumentation (saw blade and jig) and implants in a timely fashion ($<$ 45 minutes per procedure), an efficient and routine operating practice team, and consistent reproducible patient aftercare.

Diagnosis of CCL rupture was made based on clinical signs (lameness, pain, medial swelling), cranial draw, tibial thrust, stifle joint effusion and secondary degenerative changes on radiographic studies. When bilateral CCL rupture was identified on initial admission, simultaneous TPLO was offered and subsequently performed in 65 dogs. If owners declined bilateral simultaneous surgery, dogs had staged TPLO with the 2nd TPLO occurring 6 weeks after initial TPLO. All consultations were personally handled by NF in both verbal and written format (client education notes) and the decision for simultaneous or staged TPLO was solely the owner(s) based on currently available best evidence provided to them. Decisions tended to be influenced primarily by owners' desire to have a single procedure and their ability to comply with postoperative exercise restriction instruction. Decision was not based on dog-specific factors such as bodyweight, age or athletic ability.

Data Retrieved

Information retrieved included duration of lameness, sex, breed, age, weight, unilateral/bilateral lameness, surgical time (from surgical incision to closure), anesthesia time (including preoperative radiographic evaluation, limb clipping and scrub preparation, postoperative radiography and bandaging), pre- and postsurgical rectal temperature, CCL damage (partial/complete rupture), implants and saw blade used (size, commercial brand), pre- and postoperative TPA, millimeters of rotation of the proximal tibial segment, meniscal damage and treatment, postoperative antibacterial therapy and type of postoperative bandage.

Orthogonal bilateral stifle radiographs were taken preoperatively and for the affected stifle(s) immediately postoperatively and at 6 weeks at our hospital. Effective bony union was defined as progressive trabecular bridging of the osteotomy, blurring of the cut bone edges and bridging new bone at the caudal overlap of the bone segments. TPA was measured using tangential and conventional methods[30] by 1 observer (N.F.). Presence or absence of lameness at 6 weeks was recorded.

Surgical Technique

Using a standard anesthesia protocol, dogs were premedicated with methadone hydrochloride and acepromazine, and anesthesia induced with propofol and maintained with isoflurane in oxygen. Epidural morphine (0.15 mg/kg) was administered immediately preoperatively. Cefalexin (10 mg/kg subcutaneously) was administered before clipping the limb from the greater trochanter to the level of the metatarsus. The foot was covered with an elasticized wrap (Vetrap®, 3M United Kingdom PLC, Bracknell, UK) after initial scrub. Prescrub consisted of chlorhexidine 2% for $\geq$5 minutes until the skin appeared clean. The extremity was then wrapped with a clean nonpermeable incontinence pad and transferred to theater.

The dog was positioned in dorsal recumbency with the pelvic limb hanging. Surgical scrub was performed by a gloved assistant using sterile swabs and chlorhexidine 2%. Then chlorhexidine spray (Vetasept®, Animalcare Ltd., UK) was applied to the surgical area. Cefuroxime (22 mg/kg; Zinacef®, GlaxoSmithKline, Middlesex, UK) was administered intravenously 30 minutes before 1st surgical incision. Additional doses were administered every 2 hours of anesthesia time regardless of operative time. Routine 4-point field draping was used, the pes was draped with an impermeable dressing (Eco-drape® Millpledge Veterinary, Clarborough Retforf Notts, UK) and then coated in a presterilized elasticized wrap (Vetrap®) and an Ioban®2 antibacterial drape (3M United Kingdom PLC) was firmly adhered to the exposed limb before incision.

All dogs had a craniomedial parapatellar arthrotomy[31] for stifle joint exploration. A small Gelpi retractor positioned between the femoral intercondylar fossa and the cranial aspect of the tibial plateau and a Hohmann retractor placed caudal to the tibial intercondylar eminence were used to provide optimal exposure by maximally distending the joint and cranially subluxating the proximal aspect of the tibia. Where any tear or fibrillar fraying of the CrCL was visibly or palpably detected, the entire ligament was excised. The ligament was left in situ only when no grossly evident tear was visible or palpable.

A blunt probe (001409 Meniscus probe, Veterinary Instrumentation® Limited, Sheffield, UK or 2.5 mm tip probe from canine arthroscopy instrument kit VAR-3000S, Arthrex®, Naples, FL) was used to palpate both the ligament and the entire surface of the medial meniscus in all dogs and the tip was hooked under the caudal pole of the medial meniscus abaxial to the menisco-tibial ligament and pulled cranially to assess if any caudal detachment of the meniscus or segment thereof was evident. We considered this IMI. If damage to the medial meniscus was identified, the torn portion was removed by partial meniscal resection (PMR) and MMR was performed by complete transection of the body of the meniscus caudal to the medial collateral ligament. Where damage was limited to peripheral detachment of the caudal pole of the medial meniscus, MMR in isolation was performed.

The surgical procedure was performed as described by Slocum and Slocum.[13] A jig was used and no dissection of the musculature caudal to the proximal segment was performed nor was any padded protection provided for the caudal aspect of the TPLO saw blade. Copious cold irrigation fluid was used to limit saw-induced thermal bone damage. A K-wire "stick-pin" of appropriate size was inserted proximal to the patellar tendon insertion point directed caudally to temporarily secure the proximal segment after rotation. The calcaneo-patellar axis was assessed intraoperatively using visual and palpable landmarks (lateral tip of calcaneus, medial malleolus, central axis of patella and fibular head) after rotation of the proximal segment. When necessary, sagittal realignment was attained by bending the distal jig pin between the jig and the limb using plate-bending pliers. Single-pointed fragment-holding forceps were used to provide craniocaudal compression between the proximal segment and the tibial tuberosity. The cranial arm of the forceps was placed distal to the patellar tendon insertion point to avoid excessive loading of the exposed tibial tuberosity. The K-wire "stick pin" was retracted flush with the caudal border of the proximal segment, cut at the level of the tibial tuberosity, and left in situ. All osteotomies were secured with appropriately contoured nonlocking plates with 6–8 self tapping screws (Orthomed® UK Ltd., Halifax, UK) depending on dog size—2.0 mm plates (212TL2.0, Slocum® Enterprises Inc.); 2.7 or.3.5 mm plates (TPLOS27 and TPLOS35 Veterinary Instrumentation® Limited or 07401004/5 or 8/9, Orthomed® UK Ltd); or 3.5 mm broad plates (107401006/7, Orthomed® UK Ltd).

Postoperative Care

Methadone (0.3 mg/kg every 4 hours) was administered during hospitalization for analgesia. Meloxicam (0.1 mg/kg once daily) or carprofen (2 mg/kg twice daily) was administered for 4 weeks after hospital discharge. Before February 21, 2007, dogs (n = 474) were discharged with an adhesive postoperative dressing alone (Primapore® Smith & Nephew, London, UK) and after that date, 526 dogs were discharged 12–36 hours postoperatively with a protective dressing bandage comprising cotton and elasticized wrap, with the aim of minimizing direct environmental contamination. Dogs treated between January 1, 2004 and March 31, 2008 were administered cefalexin (10 mg/kg twice daily) for 14 days after TPLO. After March 31, 2008 TPLO treated dogs were not administered postoperative antibacterial therapy.

Skin sutures were removed at 14 days. Postoperative care consisted of 6 weeks confinement (cage or small room) when not on leash walking which was allowed up to 6 times daily beginning at 10 minutes duration per walk and gradually increasing to 30 minutes per walk by week 6. After 6 weeks, free run of the owner's home was allowed but leash-only walking was encouraged for all dogs until week 12. Any dog with residual lameness at 6 weeks was re-assessed clinically and radiographically at 12 weeks or until

lameness resolved. Residual lameness was defined as not fully weight-bearing on the affected limb at rest or any visible lameness discerned by 1 observer (N.F.) during yard-walking on a leash.

Complications

Complications were defined as any undesirable outcome associated with the surgical procedure and were classified depending on severity as major (surgical intervention required or lameness for >12 weeks) or minor (managed nonsurgically).

After Weese,[32] definition of surgical site infection (SSI) was a simplified adaptation from the standard criteria developed by the US Center for Disease Control and Prevention.[33] A wound was considered infected when a purulent discharge, or an abscess or fistula, and/or 1 or more of the clinical signs of pain and localized swelling, redness, heat, fever or deep incision spontaneous dehiscence was identified on clinical examination, and/or when an organism was isolated from an aseptically collected sample by culture and/or a positive cytology study (CytoPath® Ltd, Herefordshire, UK).

Statistical Analysis

All statistical analysis were performed using software (SPSS v17, August 2008, SPSS Inc., Chicago, IL, USA, and Minitab® v15, 2007, Minitab Inc., State College, PA, USA). Univariate statistics were obtained for all variables. A χ^2 test of independence for discrete variables (bandage; partial/complete CCL rupture; meniscal injury; postoperative antibiotics; bilateral simultaneous TPLO; bilateral staged TPLO, sex; breed) grouped and compared with or without complications, infections, PMI and SMI were performed. The Mann–Whitney test was used to identify potential co-distributions between a range of continuous independent variables (age; weight; pre- and postoperative TPA; mm rotation; history of lameness; pre- and postoperative temperature) with complications (subdivided as overall complications, infections, PMI and SMI). The Mann–Whitney test results were used to help construct the logistic regression model by selecting variables with P-value $\leq .05$ for inclusion in the model. However, variables with P-value $\leq .07$ were also subsequently included to permit accession of the variables "Partial or complete CCL rupture" and "Newfoundland" into the model for complications, "Postoperative antibiotics" into the infection model and "History of lameness" into the PMI model. It was considered appropriate to include these variables into the respective multivariate models based on subjective clinical experience and existing literature, and based on their P-value being close to that originally selected (.05), which could have been affected by the complex inter-variable interactions or limited case numbers for each variable grouping.

Results are expressed as mean ± SD for normally distributed variables and median for nonnormally distributed variables. A forward stepwise logistic regression model was used to identify the relationship between categorical dependent variables (complication, infection, PMI and SMI) with continuous and/or categorical independent variables. Showing the impact of the predictor variables in terms of odds ratio (OR), OR < 1.0 were considered to indicate a protective benefit whereas OR > 1.0 indicated a detrimental effect. A Hosmer-Lemeshow goodness-of-fit test was performed to assess the overall fit of the logistic regression. Variables with a P-value $\leq .05$ within the log likelihood test were considered significant contributors to the model. No multicollinearity or numerical problems were detected for variables in the equation (model), with Variance Inflation Factor < 1.5 in all dogs. Linearity between the ordinal or interval independent variable and the logit of the dependent variable was tested creating new variables which divided the existing independent variables into categories of equal intervals. A logistic regression with the same dependent but using the newly categorized version of the independent as a categorical variable was performed. The linearity was shown as roughly linear steps in the increases (or decreases) of the coefficient "b"'s. Age, weight, History of lameness, pre- and postoperative TPA, and mm of rotation were successfully assessed. To express the results of the forward stepwise logistic regression as a probability of occurrence of dependent variables, the appropriate mathematical modifications to convert odds to a simple probability were performed (Figs 1 and 2).

RESULTS

Signalment

Of the 1000 dogs, 13.3% (133) were intact and 39% (390) neutered males, 12.7% (127) intact and 35% (350) neutered

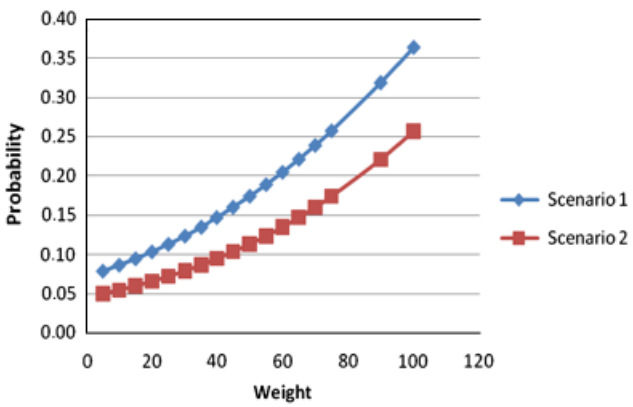

Figure 1 The probability of complication occurrence ("y"-axis) and association with body weight of the dog ("x"-axis). Scenario 1: A dog affected by complete CCL rupture. A dog of the same weight affected by complete CCL rupture has higher probability of complication than a dog with partial CCL rupture. Heavier dogs have higher complication rates. Scenario 2: A dog affected by partial CCL rupture. A dog of the same weight affected by partial CCL rupture has lower probability of complication than a dog with complete CCL rupture.

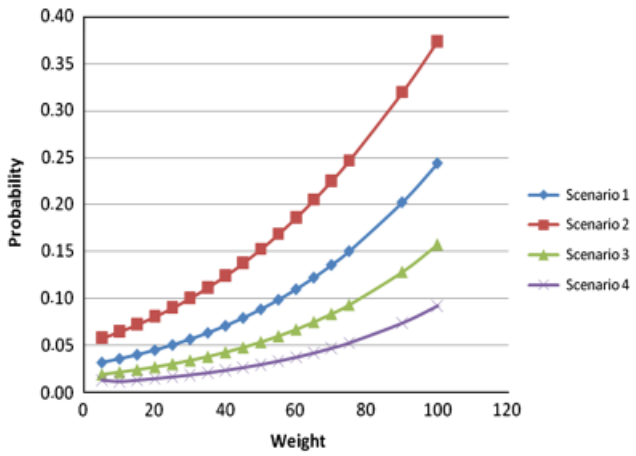

Figure 2 The probability of occurrence of infection (''*y*''-axis) and association with body weight of the dog (''*x*''-axis). Scenario 1: The dog is not an intact male Labrador and was not administered postoperative antibiotics. Scenario 2: The dog is an intact male. The risk of infection occurrence is higher. Scenario 3: The dog is an intact male Labrador. Being a Labrador is a protective factor in our model. Scenario 4: Administration of antibiotics to the same dog as in Scenario 3, had a protective effect in our model.

females. TPLO was performed on 538 left and 462 right stifles. Median age at surgery was 5.6 years (range, 5 months–12.8 years) and median weight was 32 kg (range, 5.4–100 kg). Breeds were mixed (5.3%; 53 dogs) and purebred (94.7%; 947) with 65 different breeds represented. The most common breeds were Labrador Retriever (n = 165), Rottweiler (116), Golden Retriever (102), English Springer Spaniel (58), Boxer (50), West Highland White Terrier (47), German Shepherd Dog (39), Bull Mastiff (34), Jack Russell Terrier (26), Newfoundland (21) and Dogue de Bordeaux (17). Summary surgical and anesthetic data are presented in Table 1.

Instrumentation and Implants

A 12 mm TPLO saw blade was used in 11% (n = 110), 18 mm in 18% (180), 24 mm in 58% (580) and 30 mm in 13% (130) of the dogs. A 3.5 mm plate (107401008/9, Orthomed® [n = 545]; TPLOS35, Veterinary Instrumentation® [n = 158]) was most commonly used. A 3.5 mm broad plate (107401006/7, Orthomed®) was used in heavier dogs (median weight, 60 Kg; range, 42–100 kg; n = 33) and a 2.0 mm plate (212TL2.0, Slocum® Enterprises Inc.) was used in dogs with a median weight of 10 kg (range, 9–12 kg; n = 87). The other dogs had a 2.7 mm plate (TPLOS27, Veterinary Instrumentation® [n = 125]; 107401004/5, Orthomed [n = 52]).

Table 1 Summary of General Surgical Data for 1000 TPLO Dogs

	Median	Range
Preoperative TPA	25°	(12°–46°)
Postoperative TPA	6.5°	(0°–17°)
Rotation of the proximal fragment	7.5 mm	(2–16 mm)
History of lameness	560 days	(1–2920 days)
Surgery time	30 min	(22–48 min)
Surgery time bilateral simultaneous	58 min	(44–75 min)
Anesthesia time	180 min	(120–265 min)
Temperature before surgery	37.1°C	(32.9–39.8°C)
Temperature after surgery	36.5°C	(32.9–39.8°C)

Complications

All intraoperative complications associated with technique were instantly addressed (eg, malposition of the proximal jig pin or misdirection of a screw). Postoperative complications occurred in 148 dogs (14.8%; 66 infections, 28 SMI, and 54 other complications). There were 66 major and 82 minor complications Major complications were SMI (n = 28); plate removal with (20) and without (6) positive microbial culture; tibial tuberosity fracture/avulsion (4); medial patellar luxation (3); cranial migration of the K-wire (2); delayed CCL excision(2); and broken proximal screw (1). The most common minor complications were 46 infections (69% infections) that resolved medically and 8 dogs with incisional seroma (5.4% total complications). Other minor complications were lameness (>40 days, n = 7); reduced range of stifle motion (5), patellar tendon thickening (3), slow bony union (3); pivot shift (3); joint capsule swelling (2); patella osteophyte fracture (1); positive tibial thrust (1); nondisplaced fracture of the tibial tuberosity (1); fracture of the stick pin K wire (1); and fibular fracture (1). Plate removal was performed as part of infection treatment in 20 dogs (31% of infections) and in 6 dogs, plate removal was performed for suspected infection.

Findings of univariate analyses (Mann–Whitney test and χ^2 analysis respectively) used to identify dependent and independent variables in the multivariate model are shown in Tables 2 and 3. For the general multivariate model, weight, preoperative TPA, postoperative partial versus complete CCL rupture, intact male, mm rotation of the proximal segment and the breeds Labrador, West Highland White Terrier and Newfoundland were introduced to assess association with the incidence of complications. Weight ($P = .01$) and partial/complete rupture CCL ($P = .04$) were predictors of complications in our model. Heavier dogs had higher risk of complications (OR = 1.02; 95% CI = 1.01, 1.03) per kg. Dogs affected by partial CCL rupture had lower risk of complication (OR 0.60; 95% CI = 0.36, 0.99). The model fitted the data well (Hosmer–Lemeshow χ^2 $P = .55$; Table 4; Fig 1)

Bilateral Simultaneous versus Staged TPLO

On admission, 14.6% (146 dogs) had bilateral CCL rupture and 65 of these dogs had simultaneous bilateral TPLO. For the 81 staged TPLO, median time between surgeries was 62 days. Univariate analysis (Tables 2 and 3) confirmed no association between postoperative complications (including infection) for bilateral simultaneous or staged TPLO, so these variables were not considered for any multivariate model. A Pearson χ^2 test showed that there was no

Table 2 Univariable Mann–Whitney *T*-Test for Continuous Variables

	P-Value				
Variables	Complications	Infections	Primary Meniscal Injury	Subsequent Meniscal Injury	Bilateral CCL Rupture
Age (months)	.19	.14	.02*	.09	.08
Weight (kg)	.01*	.01*	.29	.69	.02*
TPA preoperative (mm)	.04*	.10	.23	.91	.03*
TPA postoperative (mm)	.45	.80		.85	
Mm of rotation	.06*	.05*		.57	
History of Lameness (days)	.99	.98	.06*	.68	.07
Preoperative Temperature (°C)	.57	.71		.36	

Variables with * were considered for the binary logistic regression.

significant difference for incidence of postoperative complications ($P = .54$; OR 1.2; 95%CI = 0.62, 2.42) or infections ($P = .68$; OR 1.21; 95%CI = 0.47, 3.14) between staged procedures by comparison with those performed simultaneously (Table 5). Median time for contralateral CCL rupture in dogs not diagnosed with bilateral CCL rupture on initial admission was 11 months.

CCL Disease

All CCL affected by complete or partial tear on visual and instrumented palpation inspection were resected. In 2 dogs (both Boxer breed) where the ligament was grossly intact, delayed ligament excision was subsequently performed because of failure of lameness to resolve by week 6. In these dogs there was pain response evident upon attempts to obtain cranial tibial thrust, though instability was not detected. No tissue reaction was noted associated with the implants in these 2 dogs. The excised ligaments were mildly swollen and appeared to lack the well defined reticular pattern of collagen fibrils, but were not clearly discernable from normal. Histopathologic examination (Cytopath®, Ledbury, Herefordshire, UK) was performed on both excised ligaments and revealed inflammatory and metaplastic changes.

Meniscal injury

PMI. The sex distribution of 319 dogs (33.2%) with PMI was 39.7% (132) neutered males, 32.2% (109) neutered females, 13.7% (46) intact males and 13.4% (45) intact females. There was no association between breed and PMI (Tables 2 and 3). For the general multivariable model, age and partial versus complete CCL rupture were introduced to assess association with the incidence of PMI (Table 6). Dogs with complete CCL rupture ($P = .01$) had higher risk of PMI (OR = 1.91; 95% CI = 1.19, 3.07). The model fitted the data well (Hosmer–Lemeshow χ^2 $P = .32$). Types of PMI (Table 7) were classified according to Pozzi et al.[34]

Secondary Meniscal Injury (SMI). Twenty-eight dogs (2.8%) were diagnosed with, and re-operated for subsequent postliminary meniscal injury. Median time for clinical manifestation of SMI was 125 days (range, 14–450 days). Clinical features included pain when pressure was applied to the caudomedial stifle (84%), lameness at 6 weeks (69%; 11.5% with lameness severity $> 2/10$), sudden acute nonweight-bearing lameness (26.9%), postoperative presence of an audible click (19.3%), and thigh muscle wastage (11.5%). Persistent marked synovial effusion was radiographically evident on admission and 7.6% had measurable increase in periarticular osteophytosis. The incidence of SMI in the group which had been treated by PMR and MMR at the initial inspection was 0.1% (n = 3), whereas the incidence of SMI in dogs with intact medial menisci initially was 3.7% (n = 25). The OR for SMI in dogs where the medial meniscus was intact at initial surgery was OR = 4.24 (95% CI = 1.42, 14.20) compared with those affected by SMI that had MMR at initial surgery.

Infection

Of 66 dogs (6.6%) with postoperative infection, 36 were confirmed by positive bacterial culture and 30 were diagnosed based on clinical signs as previously defined. Clinical signs of infection became apparent at 25 days (median; range, 7–60 days) in dogs administered antibiotics postoperatively and the median duration of subsequent therapeutic antibacterial therapy was 68 days (range, 15–240 days). In dogs not administered postoperative antibiotics, signs of clinical infection became apparent at 18 days (median; range, 7–30 days) and the duration of subsequent antibiotic treatment was 33 days (median; range, 15–79 days). A Mann–Whitney test confirmed that the time of infection occurrence subsequent to surgical intervention, was statistically significantly different between dogs treated with postoperative antibacterial therapy (Mann–Whitney $P = .024$) by comparison with those not administered antibiotic therapy. The difference in the duration of treatment was also statistically significantly different between the 2 groups (Mann–Whitney $P = .013$).

Implants were removed in 30.3% of dogs with infection (Tables 8 and 9) because resolution of heat, pain or swelling on palpation and manipulation of the affected joint was not forthcoming or lameness was not resolving. After plate removal, lameness resolved in a median of 38 days (range 15–45 days). Median duration of antibacterial

Table 3 Univariable χ^2 Test

	Complications		Infections		Primary Meniscal Injury		Subsequent Meniscal Injury		Bilateral CCL Rupture	
Variable	*P*-Value	OR (95% CI)	*P*-Value	OR (95% CI)	*P*-Value	OR (95% CI)	*P*-Value	OR (95% CI)	*P*-Value	OR (95% CI)
Bandage	.10	0.74 (0.52, 1.1)	.78	0.93 (0.57, 1.52)			.75	0.88 (0.41, 1.81)		
Partial/complete CCL rupture	.07*	0.64 (0.39, 1.0)	.23	0.66 (0.33, 1.30)	.04*	1.97 (1.23, 3.16)	.08	0.45 (0.18, 1.14)		
Meniscal injury	.44	0.86 (0.59, 1.25)	.26	1.32 (0.80, 2.19)			.01*	0.23 (0.07, 0.78)		
Postoperative Antibiotics	.69	0.92 (0.62, 1.37)	.06*	0.61 (0.39, 1.03)						
Bilateral CCL rupture					.565	1.16 (0.68, 1.98)	.16	0.97 (0.95, 0.98)		
Bilateral simultaneous surgery	.54	1.23 (0.627, 2.42)	.68	1.21 (0.47, 3.14)						
Bilateral staged surgery	.78	1.12 (0.49, 2.5)	.98	0.99 (0.28, 3.2)						
Intact Male	.05*	1.58 (1, 2.6)	.02*	1.94 (1.1, 3.56)	.715	1.07 (0.73, 1.57)	.87	1.08 (0.37, 3.18)	.362	0.67 (0.28, 1.58)
Male castrated	.88	0.97 (0.68, 1.39)	.99	0.99 (0.6, 1.4)	.729	1.04 (0.8, 1.37)	.17	1.85 (0.86, 3.91)	.237	1.36 (0.8, 2.2)
Intact Female	.85	1 (0.61, 1.8)	.96	1.01 (0.47, 2.18)	.198	1.2 (0.87, 1.93)	.17	0.27 (0.03, 2.08)	.337	0.6 (0.2, 1.6)
Female spayed	.18	0.77 (0.53, 1.12)	.11	0.65 (0.37, 1.12)	.141	0.81 (0.65, 1.2)	.40	0.70 (0.30, 1.61)	.931	1 (0.6, 1.7)
Doberman	.15	2.33 (0.722, 7.54)	.28	2.22 (0.49, 10.19)	.440	1.5 (0.4, 5.5)	.52	0.97 (0.96, 0.98)	.890	1.1 (0.1, 8.9)
Dalmatian	.75	0.71 (0.08, 5.76)	.63	1.6 (0.20, 13.4)	.993	1.0 (0.4, 4.0)	.60	0.97 (0.96, 0.98)	.435	0.93 (0.91, 0.97)
Dogue Bordeaux	.31	1.93 (0.57, 7.22)	.19	2.6 (0.59, 12.59)	.221	0.39 (0.08, 1.8)	.55	0.97 (0.96, 0.98)	.136	3 (0.6, 14)
Bernese Mt Dog	.90	1.07 (0.3, 3.74)	.76	0.73 (0.09, 5.54)	.734	1.17 (0.45, 3.09)	.45	0.97 (0.96, 0.98)	.254	0.93 (0.91, 0.97)
Golden Retriever	.72	1.21 (0.58, 2.13)	.30	0.53 (0.16, 1.75)	.912	1.02 (0.6, 1.6)	.95	0.96 (0.22, 4.12)	.400	0.6 (0.1, 1.9)
Jack Russell Terrier	.13	0.24 (0.03, 1.82)	.08	0.67 (0.32, 1.08)	.989	1.01 (0.4, 2.3)	.40	0.97 (0.96, 0.98)	.660	0.6 (0.08, 4.8)
German Shepherd	.20	1.67 (0.74, 3.75)	.75	1.20 (0.36, 4.04)	.272	1.4 (0.7, 2.8)	.30	2.12 (0.48, 9.29)	.113	0.93 (0.91, 0.97)
Labrador	.03*	0.56 (0.32, 0.97)	.01	0.29 (0.105, 0.87)	.535	0.89 (0.6, 1.2)	.49	1.37 (0.58, 3.4)	.379	0.7 (0.3, 1.7)
Newfoundland	.07*	2.35 (0.89, 6.16)	.19	2.25 (0.64, 7.85)	.990	1 (0.4, 2.5)	.43	0.97 (0.96, 0.98)	.301	0.93 (0.91, 0.97)
Rottweiler	.56	0.84 (0.47, 1.5)	.45	0.72 (0.30, 1.71)	.151	1.3 (0.8, 1.9)	.64	1.2 (0.44, 3.7)	.611	0.8 (0.3, 1.8)
Spaniel	.72	0.85 (0.35, 2.0)	.65	1.27 (0.44, 3.66)	.072	1.73 (0.9, 3.1)	.50	1.62 (0.3, 7.02)	.941	1 (0.3, 3.4)
Great Dane	.11	2.91 (0.72, 11.76)	.63	1.66 (0.20, 13.4)	.472	1.6 (0.4, 6.06)	.61	0.97 (0.96, 0.98)	.400	0.93 (0.91, 0.97)
Bull Mastiff	.46	1.45 (0.53, 3.92)	.09	2.48 (0.83, 7.43)	.310	1.4 (0.6, 3.2)	.74	1.4 (0.18, 10.7)	.76	1.2 (0.2, 5.4)
Boxer	.91	0.95 (0.42, 2.16)	.72	1.21 (0.43, 3.48)	.300	0.7 (0.3, 1.3)	.14	2.41 (0.70, 8.28)	.08	2.1 (0.9, 5.3)
West Highland Whit Terrier	.04*	0.25 (0.06, 0.98)	.19	0.29 (0.03, 2.1)	.171	0.61 (0.31, 1.2)	.79	0.76 (0.1, 5.7)	.494	1.4 (0.5, 4.1)
Staffordshire	.69	0.88 (0.19, 3.94)	.85	0.94 (0.12, 7.27)	.991	1 (0.3, 2.9)	.5	0.97 (0.96, 0.98)	.312	0.93 (0.91, 0.97)

Variables with * were Included in the Binary Logistic Regression Model.

Table 4 Variables Associated with ''complications'' in Logistic Regression Model

Variable	Estimate	*P*-Value	OR	95% CI Lower	95% CI Upper
Constant*	−2.56	.01	0.11		
Weight*	0.021	.01	1.02	1.01	1.03
Partial/complete CCL rupture* (Partial)	−0.50	.04	0.60	0.36	0.99
Preoperative TPA	−0.033	.26	0.96	0.89	1.03
Mm rotation	0.077	.29	1.08	0.93	1.26
Intact Male	−0.34	.15	0.70	0.43	1.13
Newfoundland	−0.16	.76	0.84	0.29	2.48
Labrador	0.55	.06	1.74	1.00	3.04
West Highland White Terrier	0.61	.43	1.86	0.39	8.83

OR = odds ratio; 95% CI = confidence interval with 95%; Estimate = value of the predictor in the model.
*Statistically significant results $P < .05$.

therapy for dogs requiring plate removal was statistically higher (90 days) compared with those where plate removal was not considered necessary on the basis of reduction of heat, pain or swelling or lameness resolution (54 days; Mann–Whitney $P = .01$).

For the general multivariable model, weight, breed: Labrador, sex: intact male, administration of postoperative antibiotics and mm magnitude CCL rupture of proximal segment rotation, were introduced to assess association with the incidence of infection. Weight, Labrador breed dogs, intact males, and administration of postoperative antibiotics were statistically significant predictors of occurrence or non-occurrence of infection (Table 10). Heavier dogs (OR = 1.02; 95% CI = 1.01, 1.04) and intact males (OR = 1.85; 95% CI = 0.99, 3.57) were associated with greater incidence of infection, whereas being a Labrador (OR = 0.31; 95% CI = 0.11, 0.87) and the administration of postoperative antibiotics (OR = 0.54; 95% CI = 0.31, 0.92) were associated with lower incidence of infection. Seven hundred and fifty TPLO (75%) had postoperative antibacterial therapy for 14 days whereas 25% (250) did not. There was no difference in infection frequency recorded for dogs bandaged with a padded dressing versus a light adhesive dressing (Table 3) and no statistical association between infection and duration of anesthesia (median, 180 min) or duration of surgery (median, 30 min; Table 2). The model fitted the data well (Hosmer–Lemeshow χ^2 $P = .49$; Fig 2).

DISCUSSION

To our knowledge, this is the largest reported sequential case series of TPLO procedures performed by a single surgeon after the procedural learning curve. Our objective was to examine risk factor variables influencing complications after TPLO treatment of Cr CL deficient stifles.

Study Limitations

We acknowledge a number of important limitations to our study design. The retrospective nature of our study is a significant limitation that introduces various potential sources of bias, particularly with regard to clinical selection criteria, surgeon/clinic specific factors and reporting inaccuracies, although the large number of cases recruited may go some way to justifying study design. It is relevant that most dogs were not specifically clinically reassessed at ≥ 6 months and the failure of dogs to present for recurrent lameness during this timescale was recorded as an absence of complication. This may be particularly pertinent with regard to SMI. We cannot exclude the possibility that lameness recurred and that owners elected care at a different clinic or did not to seek veterinary advice whatsoever.

However, we consider this to be a relatively modest limitation for several reasons: (A) the referral base of primary care clinicians and the author have a close working relationship, many for more than a decade, and almost without exception, are relatively close geographically; (B) both clients and referring clinicians were instructed and accepted as part of normal protocol that if any case operated developed lameness again on the same leg(s) on any day of the week, we would perform physical examination of the dog free of charge regardless of how long after the initial injury the problem occurred. All owners were briefed both verbally and in written format at the outset that if dogs became lame at any time point after surgery, SMI was a

Table 5 Incidence of Complications and Infection for 65 Bilateral Simultaneous TPLO Compared with 81 Staged TPLO

	Age (years)	Weight (kg)	Total Complications (%)	Total Infections (%)
Staged TPLO	5.7 ± 2.62	33.6 ± 15.79	30/130 (23%)	11/130 (8.4%)
Bilateral simultaneous TPLO	5.1 ± 3.68	29.6 ± 15.09	24/130 (18.4%)	13/130 (10%)
P-value			0.84	0.18
95% CI			0.755 (0.41–1.37)	1.2 (0.5–2.79)

χ^2 test for difference in proportion between simultaneous and staged bilateral TPLO. Null hypothesis: proportions were equal. $P > .05$ for incidence of both complications and infection.

Table 6 Variables Associated with "Primary Meniscal Injury" in a Logistic Regression Model

Variable	Estimate	*P*-value	OR	95% CI Lower	95% CI Upper
Constant	−1.55	.01	0.21		
Age (months)	0.012	.06	1.01	1.00	1.01
Partial CCL rupture (Complete)*	0.65	.01	1.91	1.19	3.07

*Statistically significant results $P < .05$.
OR, odds ratio; 95% CI, confidence interval with 95%; Estimate, value of the predictor in the model.

significant consideration. If SMI were diagnosed, surgical intervention was performed at cost price; (C) the surgeon (N.F.) insisted that all 2 and 6 week re-check appointments and radiography were performed at his clinic and to encourage compliance, no ancillary charges were levied for these services; (D) every dog still lame at 6 weeks postoperatively was seen every 2–4 weeks until lameness resolution; and (E) the national licensing authority recommends that if a dog is operated at a 2nd facility after previous surgical intervention, that clinic should request clinical history from the initial surgeon. This did not occur for any dog in this series. Thus, we submit that it is likely that if lameness, SMI or other significant complications were present at 6 weeks or occurred at any time-point during the study, we would be made aware with few exceptions.

The nature of our statistical analyses represents a further potential limitation. Binary Logistic regression is not as restrictive regarding assumptions as least squares regression (does not require normally distributed variables, does not assume homoscedasticity). While there is no assumption of linearity between the binary dependent variable and categorical "independent" variables, there is absolutely an assumption of linearity between the log odds (logit) of the binary dependent variable and continuous independent variables. Trying to minimize the likelihood of multicollinearity and the independency of the errors, we elected to reduce the number of independent variables in the model (avoiding redundant information) and in animals that underwent bilateral procedures a single stifle was randomly selected as representative to assure independence of the results.

The lack of pertinent control groups for each variable assessed represents another potential limitation, and is particularly relevant to the effects of MMR on incidence of SMI, so conclusions regarding such effects cannot be made. Similarly, the relatively narrow ranges for such surgeon-dependent factors as surgical and anesthetic time, and the restriction of the study to a single anesthetic protocol, primary surgeon, and surgical technique, and to a limited range of postoperative management protocols is a further potential limitation (albeit also one of the strengths of this study). As a result, comparison with the results of other surgeons in other facilities should be cautiously interpreted.

Table 7 Types of Primary and Secondary Meniscal Injury (PMI and SMI) Diagnosed by Instrumented Systematic Inspection of the Medial Meniscus by Arthrotomy with Cranial Traction of the Tibia in 1000 Dogs

Type of Meniscal Injury	PMI (%)	SMI (%)
Displaced bucket handle tear of caudal pole medial meniscus	44.6	46.2
Peripheral detachment caudal pole medial meniscus	25.2	3.8
Displaced bucket handle tear of axial margin of medial meniscus	10.6	3.8
Non-displaced bucket handle tear of axial margin of medial meniscus	8.7	18.2
Radial fibrillation of axial margin of medial meniscus	8.7	15.4
Multiple bucket handle tears of the caudal pole of medial meniscus	2.1	8.7

Overview of Complications

Previously reported complication rates for TPLO are 18–34%[15–17]; tibial tuberosity advancement 31%[35]; fibular head transposition 16.5–27%[36,37]; lateral fabello-tibial suture 17.4%.[38] Therefore this case series presents the lowest complication rate published to date for any technique described for treatment of CCL rupture in dogs. Major (44.6%) and minor (55.4%) complication rates were similar to Pacchiana et al[16] (major 37%, minor 63%); however in our case series most complications (44.5%) were infection-associated whereas in previous reports mechanical failure constituted most complications.[16,17] Omission of dogs operated during the procedural learning curve may influence type and incidence of complications.[39] All complications in our dogs resolved after secondary intervention.

Binary logistic regression illustrated that body weight and complete CCL rupture were significantly associated with complications. Body weight has been reported as a risk factor for complication in fabello-tibial suture treatment of CCL rupture.[38] No other variable, including breed, was found to have a statistically significant influence on incidence of overall complications. This concurred with a report of complications associated with fabello-tibial suture for treatment of CCL rupture[38] but was contrary to the findings reported for another TPLO case series[16] where

Table 8 Bacteria Isolated in 36 Dogs that had TPLO by Whether or Not Plate Removal was Considered Necessary for Resolution

Bacterium Isolated	Without Plate Removal	With Plate Removal
Staphylococcus aureus	16 (3 MRSA)	5 (1 MRSA)
Staphylococcus intermedius	5	1
Streptococcus spp. *Coagulase negative*	5	1
Pseudomonas aeruginosa	7	0
Actinobacter spp.	2	1
Escherichia coli	1	0

MRSA, Methicillin-resistant *Staphylococcus aureus*.

Table 9 Antibiotic Susceptibility Results for 24 Dogs

Antibiotic	*S. aureus* n = 13	*S. aureus* MRSA n = 3	*P. aeruginosa* n = 6	*S. intermedius* n = 2
Methicillin	20%R 80%S	100%R	66%R 33%S	50%R 50%S
Amoxycillin/clavulamic acid	20%R 80%S	100%R	66%R 33%S	100%R
Cephalexin	20%R 80%S	100%R	66%R 33%S	
Cephalozin	20%R 80%S	100%R	66%R 33%S	
Enrofloxacin	20%R 80%S	100%R	33%R 66%S	
Trimethoprim—Sulphamethoxazole	100%S	100%S	50%R 50%S	
Tetracycline	100%S	100%S	50%R 50%S	
Gentamicin	100%S	100%S		
Marbofloxacin	20%R 80%S	100%R	100%S	
Clindamycin	100%S	100%S	100%S	100%R

R, resistance; S, susceptible.

higher complication rates were associated with Rottweilers compared with Labrador Retrievers. There was no association between preoperative TPA and complication rate, in agreement with previous reports.[16]

Technique and Implants

It has been suggested that locking plate technology may have salient advantages for use in TPLO[40]; however, use of conventional plating technique in our dogs did not result in significant complications. Leaving the "stick pin" in position after rotation of the proximal segment resulted in 2 complications, 1 of which required pin removal. However, we rationalized that the "stick pin" may contribute to maintenance of osteotomy apposition when torsional corrections are indicated or where only 2 mm screws are accommodated because of paucity of bone stock.

Delayed bony union occurred in 3 dogs, without clinical consequence. There is some debate about whether elective plate removal is advisable.[41] We did not remove implants where lameness resolved by week 6, but implants were removed in 6 dogs where microbial culture was negative, and lameness subsequently resolved. Potential explanations include infection where we failed to identify a causative organism or mechanical irritation or inflammation associated with the implants. Whether lameness would have resolved without plate removal in these dogs remains unknown, and because removal could be considered elective, these dogs may have artifactually elevated our major complication rate.

Table 10 Variables Associated with "Infection" in a Logistic Regression Model

Variable	Estimate	*P*-value	OR	95% CI Lower	95% CI Upper
Constant	− 3.53	.01*	0.02		
Weight (Kg)	0.024	.01*	1.02	1.01	1.04
Mm rotation.	0.039	.46	1.04	0.92	1.19
Intact Male	0.61	.05*	1.85	0.99	3.57
Postoperative antibacterial therapy	− 0.61	.02*	0.54	0.31	0.92
Labrador	− 1.15	.02*	0.31	0.11	0.87

*Statistically significant results $P < .05$.
OR, odds ratio; 95% CI, confidence interval with 95%; Estimate, value of the predictor in the model.

Medial patellar luxation occurred as a complication in 3 dogs. This could be attributable to instability associated with CCL rupture, suboptimal correction of calcaneopatellar alignment, parapatellar arthrotomy technique, preexisting quadriceps malalignment, or could be coincidental.[42] Tibial tuberosity transposition and trochlear sulcoplasty were performed to address this complication[31] in all 3 dogs and no long term adverse sequelae occurred.

Previously reported incidence of tibial tuberosity fracture/avulsion after TPLO was 3–9%,[15–17] whereas this complication affected only 0.4% dogs in our series. Comparing the relative width of the exposed tibial tuberosity and the craniocaudal width of the proximal tibia as described by Bergh et al,[22] the mean ratio for these 4 dogs was $0.215 \pm .06$ mm, which did not align with the maximum risk group reported.[22] Preoperative TPA $> 34^\circ$ was present for 44 dogs and in 32% of these dogs the proximal segment was rotated distal to the "safe point" described by Talaat et al.[43] We postulate that maximizing tuberosity thickness and minimizing the osteotomy gap may limit incidence of tuberosity fractures.

Recommended postoperative TPA based on in vitro analyses has typically ranged from 5–6.5°.[26,44,45] Median postoperative angle of 6.5° (range, 0–17°) we report is similar to that of Priddy et al[15] (mean, $6.5 \pm 3.9^\circ$; range, − 7.0 to 24.0°). In only 1 dog did lack of adequate neutralization of cranial tibial thrust manifest as a complication and this resolved after physical therapy.

The incidence of patellar tendon thickening in our dogs was low by comparison with other reports.[17] All radiographic follow-up was performed at our facility to ensure standardization of radiographic technique and postoperative leash-only walking was strictly enforced. All cases of stiffness, reduced range of motion or pivot shift

resolved (median, 45 days) with judicious physical therapy and hydrotherapy.[46–48]

CCL Disease

It has been well established that both biologic and biomechanical factors contribute to CCL rupture, and efforts to resolve joint pathology by addressing mechanical factors and osseous geometry in isolation may not provide a comprehensive solution for diseased stifle joints. [3,9–12,49–51] We did not remove grossly intact ligaments because it has been reported that such ligaments may serve a useful role in controlling internal rotation and promoting normalized joint mechanics, which are not addressed by TPLO, and may appear functional on second-look arthroscopy.[41] However, increased inflammatory and apoptotic activity in CCL rupture in dogs by comparison with human ACL rupture suggest different pathogeneses[12,52] and it has been shown that structural degradation of the CCL often precedes rupture in dogs.[49,53] It has been argued that debridement of only diseased fibers of CCL rupture may leave some functional elements whilst decreasing the inflammatory cascade perpetuated by exposed collagen fibrils.[53] We removed all grossly diseased ligaments because it has been shown that there are no detectable microstructural differences between visibly intact and disrupted portions of partially torn ligaments.[12] Furthermore, perpetuation of concomitant degeneration and inflammation has been associated with diseased CCL.[50]

The 2 dogs where lameness did not resolve until resection of the apparently intact CCL are particularly interesting. Pain was elicited on attempts to obtain cranial tibial thrust before resection and there was no pain on such manipulation after resection, and lameness resolved by 6 weeks after delayed CCL resection. Histologic examination of both ligaments revealed diffuse collagen fiber disruption, chondroid metaplasia, fibrosis, edema and lymphocytic inflammation. It is likely that ligament resection was the primary arbiter of resolution of clinical signs and that pain could have been associated with nociceptive feedback from the ligament or degeneration of the ligament and associated inflammatory response. Whether resection of the CCL should be recommended for all dogs operated by TPLO regardless of physical appearance thereof is unknown.

Bilateral Simultaneous versus Staged TPLO

Bilateral CCL rupture was identified on admission in 17% of our dogs, similar to the previously reported incidence of 10–31%.[16,17,20,21] There was no identified breed predisposition for bilateral CCL rupture. It has been suggested that 21–60% of dogs with unilateral CCL rupture may ultimately sustain CCL rupture of the contralateral stifle within 14 months from initial surgery.[10,20,21,54] Our study concurs with this finding showing similar time interval for delayed contralateral CCL rupture, with a median of 11 months. Barnhart et al[21] reported that definitive surgical treatment of bilateral CCL rupture with single-session bilateral TPLO is a safe and effective alternative to staged procedures, whereas other authors have advised against single-session bilateral procedures with a complication rate of up to 40%.[15,55] We did not find any statistically significant difference in complications between bilateral simultaneous TPLO and staged TPLO. Median operative time for bilateral procedures was 58 min which is short compared with a previous report.[17] We submit that shifting body weight onto a diseased contralateral limb may be problematic for some dogs and emphasize assiduous attention to osteotomy position, meniscal inspection, and postoperative care.

Meniscal Injury

PMI. Medial meniscal pathology is a commonly reported sequel of CrCL impairment with reported incidence between 20% and 77%.[56–59] In our dogs, complete CCL rupture was associated with higher incidence of PMI than partial CCL rupture (OR = 1.91; 95% CI = 1.19, 3.07) as previously reported.[57] This may intimate a mechanically protective effect of the remaining portion of CCL in partial tears. The functional role of the medial meniscus has been well established in people and animals[60–63] and most PMIs involve the caudal horn of the medial meniscus, likely as a result of its firm attachment to the tibial plateau.[58,64–69] In our dogs, as in previous reports, most PMIs constitute vertical longitudinal "bucket-handle" tears.[58]

SMI. There was statistically significant increased incidence of SMI in dogs where intact menisci were observed at initial intervention, with OR = 4.24 (95% CI = 1.42, 14) by comparison with those dogs that had undergone MMR. However, because no visibly normal menisci were released, direct comparison of dogs with intact menisci and dogs with intact menisci that had MMR with respect to development of SMI is not possible. Three dogs that had MMR performed still sustained SMI. Meniscal release was not performed for menisci of normal appearance and texture in this case series because it was considered that the relative risk of SMI was more acceptable than potentially subjecting all dogs to more severe focal cartilage wear that might be anticipated after MMR or PMR.[27,70–72]

It has been suggested that a higher likelihood of SMI after TPLO with arthrotomy versus arthroscopically assisted TPLO without MMR may reflect lack of identification of PMI because of difficulty in evaluating the meniscus fully at arthrotomy.[24] The low rate of SMI after IMI and arthrotomy in our study (2.8%) was less than that reported (3.3%) for IMI during arthroscopically assisted TPLO without MMR, and substantially less than that previously reported for TPLO with arthrotomy without MMR (10.5%) or with MMR (5.2%).[24] This may be in part attributable to the shorter follow-up time for some of our dogs than that previously reported,[24] where time to SMI after arthrotomy with MMR was 721.5 ± 808. days and without MMR was 423 ± 295.6 days, although further

investigation is required to confirm this. We submit that assiduous attention to IMI, whether performed by arthrotomy or arthroscopically is likely to reduce incidence of SMI, with the caveat that magnification and ease of inspection is undoubtedly facilitated by arthroscopic evaluation of the stifle, as for other joints.

Infection

Reported postoperative infection rates in dogs are 3.5–5% for all procedure types and 1.6–2.5% for clean procedures.[32,73] The rate of infection after TPLO manifested as septic arthritis, osteomyelitis or superficial wound infection has been reported at 3–7%.[15–17,29,39] It has been suggested that increased infection rate associated with TPLO may be attributed to periosteal dissection, prolonged surgical time, thermal necrosis at the site of the osteotomy or implant characteristics.[39,74] Other factors may include application of plates of large surface area to relatively small bone segments in tight periosteal apposition at a superficial site. Whether this could be alleviated by use of locking plate technology remains unknown. In our dogs, we feel it is unlikely that excessive dissection played a role because our surgical protocol involved no separation of tissues caudal to the proximal segment.

Our infection rate was statistically lower in dogs administered postoperative antibacterial therapy with an odds ratio OR = 0.55 (95%CI = 0.31, 0.92). Administration of perioperative antibacterial therapy may be protective against developing surgical site infections[75] in spite of the general recommendation against prophylactic antibacterial therapy for "clean" orthopedic procedures.[29] This finding is surprising, albeit supported by anecdotal observations by other surgeons and we acknowledge that administration of postoperative antibiotics after clean orthopedic procedures remains contentious. Nonetheless, we feel it is relevant to present this data and feel that all reasonable effort has been expended to remove confounding variables.

More than half of the cases of infection resolved without implant removal in spite of bacteriologic culture results in most dogs revealing gram-positive bacteria (*Staphylococcus aureus* [n = 16], *S. intermedius*,[5] *Streptococcus* spp.[5]) as reported previously[16,38] with 18.7% of *S. aureus* being methicillin-resistant. Gram-positive aerobic bacteria have the capacity to produce polysaccharide biofilm[76–78] that may protect bacteria from phagocytosis and may preclude access of antibacterial therapy for curative effect. It may be that antibacterial therapy was implemented early enough in our dogs that implant removal proved unnecessary. Recalcitrance of clinical signs associated with infection prompted implant removal in 30.3% (20 dogs). It is intuitive therefore that duration of antibacterial therapy for those dogs where plate removal proved necessary was longer than when plate removal was not performed (Mann–Whitney $P = .01$).

It has been proposed that several risk factors may predispose to infection, such as anesthetic agent, length of anesthesia, length of operative procedure, dog age, implant type, body temperature, or bandaging[79–82] None of these variables were identified as significant risk factors in our model. However, binary logistic regression after adjusting for several variables revealed that Labrador retrievers had a lower incidence of infection compared with other breeds, whereas male dogs had higher risk. Increasing body weight was also found to be an important predictor of infection in agreement with a previous report.[75] We could establish no statistical correlation between duration of anesthesia (median, 180 min) or duration of surgery (median, 30 min) and infection rate, in contrast to some previously studies.[75,82,83] The total duration of anesthesia included dog clipping, general preparation, preoperative radiography, transfer to operating theater and draping, postoperative bandaging, and radiographic studies before recovery. Operative time was short compared with previously reported mean surgical times of 45–106 minutes.[15,16] In people, body temperature has a significant effect on rate of postoperative infection of surgical sites and preoperative thermal enhancement is desirable.[84] In our dogs, there was no correlation between rate of infection and body temperature at beginning or end of anesthesia in agreement with a previous study.[85]

Summarily, we concluded that (1) bilateral simultaneous TPLO does not have a higher complication rate than staged TPLO; (2) breed is not a predictive variable for bilateral CCL rupture; (3) PMI occurrence is not influenced by breed, TPA, sex, age, or lameness duration but occurs with increased incidence when CCL rupture is complete (versus partial). Complications generally increase with increased body weight; (4) the incidence of SMI after arthrotomy with visual and palpation inspection of the medial meniscus assisted by cranial tibial traction does not exceed that reported for arthroscopically assisted TPLO; and (5) infection rate is not influenced by age, implant type, type of postoperative bandage, body temperature, operative time or anesthesia time, but infection rate increases with increased body weight or being male and decreases for the Labrador retriever breed and in association with administration of postoperative antibacterial therapy.

We report the lowest complication rate to date for any technique for treatment of CCL rupture. Whereas statistical significance was established for several predictors of complications after TPLO, the major implications are to illustrate epidemiologic trends and to emphasize the importance of concomitant consideration of both biological and biomechanical factors influencing stifle joint disease. Whilst careful attention to geometry and position of the osteotomy and assiduous meniscal inspection undoubtedly contributed to reduced rate of mechanical complications associated with TPLO, attention to biologic factors like debridement of the diseased cranial cruciate ligament, treatment of meniscal pathology and optimization of joint kinematics through appropriate postoperative care, with particular attention to factors potentially predisposing for infection are equally important.

ACKNOWLEDGMENTS

We thank Felix Cabrero for his help in tabulating initial data and Drs. Michael Kowaleski and Russell Yeadon for their advice and constructive comments.

REFERENCES

1. Aiken SW, Kass PH, Toombs JP: Intercondylar notch width in dogs with and without cranial cruciate ligament injuries. *Vet Comp Orthop Traumatol* 1995;8:128–132
2. Johnson JA, Austin C, Breur GJ: Incidence of canine appendicular musculoskeletal disorders in 16 veterinary teaching hospitals from 1980 through 1989. *Vet Comp Orthop Traumatol* 1994;7:56–69
3. Slocum B, Devine T: Cranial tibial wedge osteotomy: a technique for eliminating cranial tibial thrust in cranial cruciate ligament repair. *J Am Vet Med Assoc* 1984;184:564–569
4. Jerram RM, Walker AM, Warman CG: Proximal tibial intra articular ostectomy for treatment of canine cranial cruciate ligament injury. *Vet Surg* 2005;34:196–205
5. Innes JF, Barr AR: Clinical natural history of the postsurgical cruciate deficient canine stifle joint: year 1. *J Small Anim Pract* 1998;39:325–332
6. Innes JF, Bacon D, Lynch C, et al: Long-term outcome of surgery for dogs with cranial cruciate ligament deficiency. *Vet Rec* 2000;147:325–328
7. Galloway RH, Lester SJ: Histopathological evaluation of canine stifle joint synovial membrane collected at the time of cranial cruciate ligament rupture. *J Am Anim Hosp Assoc* 1995;31:289–294
8. Jackson J, Vasseur PB, Griffey S, et al: Pathologic changes in grossly normal menisci in dogs with rupture of the cranial cruciate ligament. *J Am Vet Med Assoc* 2001;218:1281–1284
9. Duval JM, Budsberg SC, Flo GL, et al: Breed, sex, and body weight as risk factors for rupture of the cranial cruciate ligament in young dogs. *J Am Vet Med Assoc* 1999;6:811–814
10. Wilke VL, Robinson DA, Evans RB, et al: Estimate of the annual economic impact of treatment of cranial cruciate ligament injury in dogs in the United States. *J Am Vet Med Assoc* 2005;227:1604–1607
11. Vasseur PB: Stifle joint, in Slatter DH (ed): *Textbook of small animal surgery (ed 2)*, Vol. 2. Philadelphia, PA, Saunders, 1993, pp 1817–1866
12. Krayer M, Rytz U, Oevermann A, et al: Apoptosis of ligamentous cells of the cranial cruciate ligament from stable stifle joints of dogs with partial cranial cruciate ligament rupture. *Am J Vet Res* 2008;69:625–630
13. Slocum B, Slocum TD: Tibial plateau leveling osteotomy for repair of cranial cruciate ligament rupture in the canine. *Vet Clin North Am Small Anim Pract* 1993;23:777–795
14. Kergosien DH, Barnhart MD, Kees CE, et al: Radiographic and clinical changes of the tibial tuberosity after tibial plateau leveling osteotomy. *Vet Surg* 2004;33:468–474
15. Priddy NH, Tomlinson JL, Dodam JR, et al: Complications with and owner assessment of the outcome of tibial plateau leveling osteotomy for treatment of cranial cruciate ligament rupture in dogs: 193 cases (1997–2001). *J Am Vet Med Assoc* 2003;222:1726–1732
16. Pacchiana PD, Morris E, Gillings SL, et al: Surgical and postoperative complications associated with tibial plateau leveling osteotomy in dogs with cranial cruciate ligament rupture: 397 cases (1998–2001). *J Am Vet Med Assoc* 2003;222:184–193
17. Stauffer KD, Tuttle TA, Elkins AD, et al: Complications associated with 696 tibial plateau leveling osteotomies (2001–2003). *J Am Anim Hosp Assoc* 2006;42:44–50
18. Carey K, Aiken SW, DiResta GR, et al: Radiographic and clinical changes of the patellar tendon after tibial plateau leveling osteotomy 94 cases (2000–2003). *Vet Comp Orthop Traumatol* 2005;18:235–242
19. Mattern KL, Berry CR, Peck JN, et al: Radiographic and ultrasonographic evaluation of the patellar ligament following tibial plateau leveling osteotomy. *Vet Radiol Ultrasound* 2006;47:185–191
20. Pond MJ, Campbell JR: The canine stifle joint: I. Rupture of the anterior cruciate ligament: An Assessment of conservative and surgical treatment. *J Small Anim Pract* 1972;13:1
21. Barnhart MD: Results of single-session bilateral tibial plateau leveling osteotomies as a treatment for bilaterally ruptured cranial cruciate ligaments in dogs: 25 cases (2000–2001). *J Am Anim Hosp Assoc* 2003;39:573–578
22. Bergh MS, Rajala-Schultz P, Johnson KA: Risk factors for tibial fracture after tibial plateau leveling osteotomy in dogs. *Vet Surg* 2008;37:374–382
23. Boudrieau RJ, McCarthy RJ, Sisson RD Jr: Sarcoma of the proximal portion of the tibia in a dog 5.5 years after tibial plateau leveling osteotomy. *J Am Vet Med Assoc* 2005;227:1613–1617. Comment in: J Am Vet Med Assoc. 2006 Jan 15;228(2):194–5; author reply 195
24. Thieman KM, Tomlinson JL, Fox DB, et al: Effect of meniscal release on rate of subsequent meniscal tears and owner-assessed outcomes in dogs with cruciate disease treated with tibial plateau leveling osteotomy. *Vet Surg* 2006;35:705–710
25. Pozzi A, Kowaleski MP, Apelt D, et al: Effect of medial meniscal release on tibial translation after tibial plateau leveling osteotomy. *Vet Surg* 2006;35:486–494
26. Slocum B, Devine T: Knee, in Bojrab MJ, Ellison GW, Slocum B (eds): *Current Techniques in Small Animal Surgery*. Philadelphia, PA, Williams & Wilkins, 1998, pp 1187–1244
27. Pozzi A, Hildreth BS, Rajala-Shultz PJ: Comparison of artrhoscopy and arthrotomy for diagnosis of medial meniscal pathology: an ex vivo study. *Vet Surg* 2008;37:749–755
28. Kim SE, Pozzi A, Scott AB, et al: Effect of tibial leveling osteotomy on femorotibial contacts mechanics and stifle kinematics. *Vet Surg* 2009;38:23–32
29. Vasseur PB, Levy J, Dowd E, et al: Surgical wound infection rates in dogs and cats. Data from a teaching hospital. *Vet Surg* 1988;17:60–64
30. Reif U, Dejardin LM, Probst CW, et al: Influence of limb positioning and measurement method on the magnitude of the tibial plateau angle. *VetSurg* 2004;33:368–375
31. Piermattei DL, Flo GL, DeCamp CE: The stifle joint, in Piermattei DL, Flo GL, DeCamp CE (eds): *Brinker, Piermattei, and Flo's Handbook of Small Animal Orthopedics*

and Fracture Repair (ed 4). Philadelphia, PA, Saunders, 2006, pp 562–632

32. Weese JS: A review of post-operative infections in veterinary orthopaedic surgery. *Vet Comp Orthop Traumatol* 2008;21: 99–10
33. Horan TC, Gaynes RP, Martone WJ, et al: CDC definitions of nosocomial surgical site infections, 1992: a modification of CDC definitions of surgical wound infections. *Am J Infect Control;* 1992;20:271–274
34. Pozzi A, Tonks C, Ling H: Tibiofemoral contact mechanics and meniscal strain after serial meniscectomies in the dog stifle. Proceedings, 37th Annual Conference Vet Ortho Soc, Steamboats Spring, CO, February 28-March 6, 2009
35. Lafaver S, Miller NA, Stubbs WP, et al: Tibial tuberosity advancement for stabilization of the canine cranial cruciate ligament-deficient stifle joint: surgical technique, early results, and complications in 101 dogs. *Vet Surg* 2007;36:573–586
36. Mullen HS, Matthiesen DT: Complications of transposition of the fibular head for stabilization of the cranial cruciate-deficient stifle in dogs: 80 cases (1982–1986). *J Am Vet Med Assoc* 1989;195:1267–1271
37. Dupuis J, Harari J, Papageorges M, et al: Evaluation of fibular head transposition for repair of experimental cranial cruciate ligament injury in dogs. *Vet Surg* 1994;23:1–12
38. Casale SA, McCarthy RJ: Complications associated with lateral fabellotibial suture surgery for cranial cruciate ligament injury in dogs: 363 cases (1997–2005). *J Am Vet Med Assoc* 2009;234:229–235
39. Kim SE, Pozzi A, Kowaleski MP, et al: Tibial osteotomies for cranial cruciate ligament insufficiency in dogs. *Vet Surg* 2008;37:111–125
40. Leitner M, Pearce SG, Windolf M, et al: Comparison of locking and conventional screws for maintenance of tibial plateau positioning and biomechanical stability after locking tibial plateau leveling osteotomy plate fixation. *Vet Surg* 2008;37:357–365
41. Beale BS: Second-look arthroscopic of the canine stifle following tibial plateau leveling osteotomy for treatment of partial cranial cruciate ligament tears. BSAVA 48th Annual congress. Birmingham UK, 7–10th April 2005
42. Arthurs GI, Langley-Hobbs SJ: Patellar luxation as a complication of surgical intervention for the management of cranial cruciate ligament rupture in dogs. A retrospective study of 32 cases. *Vet Comp Orthop Traumatol* 2007;20:204–210
43. Talaat MB, Kowaleski MP, Boudrieau RJ: Combination tibial plateau leveling osteotomy and cranial closing wedge osteotomy of the tibia for the treatment of cranial cruciate ligament-deficient stifles with excessive tibial plateau angle. *Vet Surg* 2006;35:729–739
44. Warzee CC, Dejardin LM, Arnoczky SP, et al: Effect of tibial plateau leveling on cranial and caudal tibial thrusts in canine cranial cruciate–deficient stifles: an in vitro experimental study. *Vet Surg* 2001;30:278–286
45. Kowaleski MP, Detlef A, Mattoon JS, et al: The effect of tibial plateau leveling osteotomy position on cranial tibial subluxation: an in vitro study. *Vet Surg* 2005;34:332–336
46. Monk ML, Preston CA, McGowan CM: Effects of early intensive post-operative physiotherapy on limb function after tibial plateau leveling osteotomy in dogs with deficiency of the cranial cruciate ligament. *Am J Vet Res* 2006;67:529–536
47. Marsolais GS, Dvorak G, Conzemius MG: Effects of post-operative rehabilitation on limb function after cranial cruciate ligament repair in dogs. *J Am Vet Med Assoc* 2002;220:1325–1330
48. Marsolais GS, McLean S, Derrick T, et al: Kinematic analysis of the hind limb during swimming and walking in healthy dogs and dogs with surgically corrected cranial cruciate ligament rupture. *J Am Vet Med Assoc* 2003;222:739–743
49. Muir P, Schamberger GM, Manley PA, et al: Localization of cathepsin K and tartrate-resistant acid phosphatase in synovium and cranial cruciate ligament in dogs with cruciate disease. *Vet Surg* 2005;34:239–246
50. Fujita Y, Hara Y, Nezu Y, et al: Proinflammatory cytokine activities, matrix metalloproteinase-3 activity, and sulfated glycosaminoglycan content in synovial fluid of dogs with naturally acquired cranial cruciate ligament rupture. *Vet Surg* 2006;35:369–376
51. Beale BS: Partial cranial curciate ligamanent tears. What are my treatment options and expected outcome? American College of Veterinary Surgeons Symposium, Equine and Small Animal Proceedings, October 23, 2008
52. Barrett JG, Hao Z, Graf BK, et al: Inflammatory changes in ruptured canine cranial and human anterior cruciate ligaments. *Am J Vet Res* 2005;66:2073–2080
53. Heffron LE, Campbell JR: Morphology, histology and functional anatomy of the canine cranial cruciate ligament. *Vet Rec* 1978;102:280–283
54. Boute N, Fusco J, Radasch R: Age, tibial plateau angle, sex, and weight as risk factors for contralateral rupture of the cranial cruciate ligament in labradors. *Vet Surg* 2009;38:481–489
55. Theoret MC, Whitney WO, Beale BS: Complications associated with tibial plateau leveling osteotomy. Proceedings 30th Annual Conference Veterinary Orthopedic Society, Steamboat, CO, 2003
56. Flo GL: Meniscal injuries. *Vet Clin North Am Small Anim Pract* 1993;23:831–843
57. Bennett D, May C: Meniscal damage associated with cruciate disease in the dog. *J Small Anim Pract* 1991;32:111–117
58. Ralphs SC, Whitney WO: Arthroscopic evaluation of menisci in dogs with cranial cruciate ligament injuries: 100 cases (1999–2000). *J Am Vet Med Assoc* 2002;221:1601–1604
59. Jandi A, Kahlon S, Sandhu B: Effect of duration of cranial cruciate ligament pathology on medial meniscal damage-Prospective study of 917 stifle joints surgically treated with tibial plateau leveling osteotomy. 36th Annual Conference Veterinary Orthopedic Society. Steamboat Springs, Colorado. February 28 – March 6, 2009
60. Thompson WO, Fu FH: The meniscus in the cruciate-deficient knee. *Clin Sports Med* 1993;12:771–796
61. Muller W: Menisci and knee stability. *Orthopade* 1994;23: 93–97
62. Muhr G: Meniscus and instability. *Langenbecks Arch Chir* 1987;372:259–261
63. Shoemaker SC, Markolf KL: The role of the meniscus in the anterior-posterior stability of the loaded anterior cruciate

deficient knee. Effects of partial versus total excision. *J Bone Jt Surg Am* 1986;68:71–79

64. Moore KW, Read RA: Cranial cruciate ligament rupture in the dog—a retrospective study comparing surgical techniques. *Aust Vet J* 1995;77:281–285
65. Thompson WO, Thaete FL, Fu FH, et al: Tibial meniscal dynamics using three-dimensional reconstruction of magnetic resonance images. *Am J Sports Med* 1991;19:210–216
66. Briggs KK: The canine meniscus: injury and treatment. *Compend Contin Educ Pract Vet* 2004;26:687–697
67. Timmermann C, Meyer-Lindenberg A, Nolte I: [Meniscus injuries in dogs with rupture of the cruciate ligament]. *Dtsch Tierarztl Wochenschr* 1998;105:374–377 (German)
68. Mahn MM, Cook JL, Cook CR, et al: Arthroscopic verification of ultrasonographic diagnosis of meniscal pathology in dogs. *Vet Surg* 2005;34:318–323
69. Smith GN, Mickler EA, Albrecht ME, et al: Severity of medial meniscus damage in the canine knee after anterior cruciate ligament transection. *Osteoarthr Cartilage* 2002;10: 321–326
70. Cook J: Meniscal repair and regeneration, in 2007 American College of Veterinary Surgeons Symposium, October 19–21. Chicago, IL, 2007, pp 326–327.
71. Matis U, Brahm-Jorda T, Jorda C, et al: Radiographic evaluation of the progression of osteoarthritis after tibial plateau leveling osteotomy in 93 dogs. Proceedings, 12th European Society of Veterinary Orthopaedics and Traumatology, Munich, Germany, p. 250, 2004 (abstract)
72. Pozzi A, Litzky AS, Field J, et al: Pressure distributions on the medial tibial plateau after medial meniscal surgery and tibial plateau levelling osteotomy in dogs. *Vet Comp Orthop Traumatol* 2008;21:8–14
73. Lipowitz AJ: Surgical wounds, in Lipowitz AJ, Caywood DD, Newton CD, et al: (eds): *Complications in Small Animal Surgery: Diagnosis, Management, Prevention*. Philadelphia, PA, Williams & Wilkins, 1996, pp 1–6
74. Papagelopoulos PJ, Partsinevelos AA, Themistocleous GS, et al: Complications after tibial plateau fracture surgery. *Injury* 2006;37:475–484
75. Eugster F, Schawalder P, Gaschen F, et al: A prospective study of post-operative surgical site infections in dogs and cats. *Vet Surg* 2004;33:542–550
76. Johnson AP, Henwood C, Mushtaq S, et al: Susceptibility of gram-positive bacteria from ICU patients in UK hospitals to antibacterial agents. *J Hosp Infect* 2003;54:179–187
77. Vuong C, Otto M: Staphylococcus epidermidis infections. *Microbes Infect* 2002;4:481–489
78. Cramton SE, Gerke C, Schnell NF, et al: The intercellular adhesion (ica) locus is present in *Staphylococcus aureus* and is required for biofilm formation. *Infect Immun* 1999;67:5427–5433
79. Brown D, Conzemius M, Shofer F, et al: Epidemiologic evaluation of post-operative wound infections in dogs and cats. *J Am Vet Med Assoc* 1997;210:1302–1306
80. Nicholson M, Beal M, Shofer F, et al: Epidemiologic evaluation of post-operative wound infection in clean-contaminated wounds: a retrospective study of 239 dogs and cats. *Vet Surg* 2002;31:577–581
81. MacDonald DG, Morley PS, Bailey JV, et al: An examination of the occurrence of surgical wound infection following equine orthopaedic surgery (1981–1990). *Equine Vet J* 1994;26:323–326
82. Garibaldi RA, Cushing D, Lerer T: Risk factors for post-operative infection. *Am J Med* 1991;91(Suppl 3B): 158S–163S
83. Wong ES: Surgical site infections, in Mayhall CG (ed): *Hospital Epidemiology and Infection Control of Nosocomial Infections*. Baltimore, MD, Lippincott, Williams & Wilkins, 1996, pp 155–173
84. Melling AC, Ali B, Scott EM, et al: Effects of peri-operative warming on the incidence of wound infection after clean surgery: a randomized controlled trial. *Lancet* 2001;358:876–880
85. Beal MW, Brown DC, Shofer FS: The effects of perioperative hypothermia and the duration of anesthesia on postoperative wound infection rate in clean wounds: a retrospective study. *Vet Surg* 2004;29:123–127

SURGICAL MANAGEMENT OF RADIAL HEAD LUXATION IN A DOG USING AN EXTERNAL SKELETAL TRACTION DEVICE

Noel Fitzpatrick DUniv MVB CertVR CertSAO MRCVS
Russell Yeadon MA VetMB CertSAS MRCVS
Michael Farrell BVetMed CertVA CertSAS Diplomate ECVS MRCVS

INTRODUCTION

The canine elbow is a composite joint made up of the humero-radial, humero-ulnar, and proximal radio-ulnar articulations (1). Luxation of any of the three bones that form the elbow joint affects two of the component joints (2). Elbow luxation has been classified as traumatic, congenital or developmental (3). The congenital or developmental forms have been sub-classified according to variations in luxation anatomy (2). Humero-radial luxation (Type 1) occurs when the radial head is displaced, and the humero-radial and proximo radio-ulnar articulations are disrupted. Humero-ulnar luxation (Type 2) occurs when ulnar displacement results in disruption of the humero-ulnar and proximal radio-ulnar articulations, and combined humero-radial and humero-ulnar luxation (Type 3) occurs when both the radius and ulna are displaced as a unit, causing disruptions of the humero-radial and humero-ulnar articulations.

Radial head luxation is the commonest form of atraumatic canine elbow luxation (2). Whether radial head luxation is congenital or developmental can be difficult to establish, due to late recognition of the deformity, and the similarity of radiographic findings regardless of aetiology (4). In humans, congenital radial head luxation occurs as a result of failure of normal embryonic elbow joint development, which is under genetic control (5). In contrast, the aetiology of canine radial head luxation remains unclear. A hereditary basis has been suggested, based on the frequency of bilateral involvement, the occurrence of radial head luxation in more than one littermate, and the occurrence of multiple orthopaedic anomalies in some individuals (6-8). Hereditary radial head luxation secondary to premature closure of the distal ulnar physis has been identified in Sky Terriers (9). Whilst controversy exists regarding the aetiology of radial head luxation, most authors accept a pathophysiologic hypothesis involving laxity of the peri-articular elbow ligaments, coincident with

radial and ulnar growth disturbances (2-9). These growth disturbances are most commonly caused by premature closure of the distal ulnar physis (10-11).

Congenital or developmental radial head luxation has been recorded in a wide variety of small and large breed dogs (3, 7, 12). Although radial head luxation has been recognized at birth, minimal impairment in early life often predisposes to late diagnosis, and most owners first notice a problem between three and five months of age (9, 13). There is a poor correlation between the degree of deformity and the amount of lameness or elbow pain (13). In one case series, all but one owner noticed elbow deformity (rather than limping) as the primary abnormality (2). Clinical signs include mild thoracic limb lameness, elbow discomfort, reduced elbow range of motion, carpal valgus, and a palpable radial head on the lateral aspect of the joint (13). Luxation is usually in a caudolateral direction, with the ulna in a relatively normal location (2). Radiographic findings include a convex radial articular fovea, distal humeral angular deformity, medial deviation and distortion of the olecranon, and cranial curvature of the proximal ulna (2). In some cases, ulnar trochlear notch incongruity and hypoplasia or aplasia of the medial coronoid process or anconeal process are additional features (2).

Currently there is no accepted ideal treatment protocol for developmental canine radial head luxation. This may be a consequence of the inconsistent nature of published surgical reports, and the absence of data detailing the long-term natural progression of non-surgically managed radial head luxation. Some authors argue that mild clinical signs justify a conservative approach, with exercise restriction and careful radiographic monitoring until skeletal maturity is reached (13). The development of pain or progressive subluxation of the elbow might prompt a decision for delayed surgical intervention (13). The counter-argument for early surgical intervention focuses on the concept that reduction of the radial head before 5 months of age will result in better remodeling of the articular cartilage than if surgery is delayed (14). Surgical options fall into broad categories of open reduction and stabilization, radial head ostectomy, and arthrodesis (13). The techniques described and the surgical outcomes vary widely, and depend on the chronicity of luxation and the degree of secondary change to articular cartilage, subchondral bone and peri-articular soft tissues (4,

8-9). In this case report, we describe the surgical technique and outcome for a dog managed surgically for developmental radial head luxation using an external skeletal traction device to gradually reduce the luxated radial head.

CASE REPORT

A five-months-old 14-kg female Airedale Terrier presented with a history of right thoracic limb lameness. The dog had been in the owner's possession for two months and had been lame since acquisition. There had been no known trauma during this time or within the first three months of life. Lameness appeared to progress insidiously, and was worse after exercise or after rising from a prone position. No medical or surgical treatments had been undertaken prior to specialist referral.

There was a 2/5 right thoracic limb lameness (using a numerical rating scale without descriptors (10)). The radial head could be palpated in a laterally luxated position. Elbow range of motion was restricted compared to the normal contralateral elbow by approximately 20° in flexion (55° (right) vs 35° (left)) and 15° in extension (145° (right) vs 160° (left)). A severe pain response (vocalizing) was induced by full elbow flexion or extension. The radial head could not be reduced either in the conscious or sedated dog. Orthogonal radiographs of the right elbow joint were obtained (Figure 1A and B). The radial head was luxated caudolaterally, with the proximal radial articular surface positioned ~5mm proximal to the humeral capitular articular surface. The degree of lateral and caudal displacement of the radial head was 11mm and 16mm, respectively. The ulnar coronoid process was absent, and there was humeroulnar incongruity, with a 2-3mm gap between the humeral condyle and the caudoproximal aspect of the ulnar trochlear notch. The subchondral bone of the radial head articular surface appeared moderately convex in profile in both the frontal and sagittal planes. The location and appearance of the distal radial and ulnar growth plates were normal.

Pre-operative planning

Using the normal contralateral elbow as a radiographic template, the intended location of the reduced radial head in the sagittal and frontal planes was traced onto acetate sheets and superimposed onto the radiographs shown in Figure 1. The radiographic centre of the radial articular surface was marked in the luxated and reduced positions and a line was drawn between these two points in both planes (Figure 2). These lines corresponded to the direction of traction in the sagittal and frontal planes that would enable appropriate reduction of the luxated radial head. Lines corresponding to the sagittal plane axis and frontal plane axis of the radial diaphysis were drawn, and

118 the angles intersecting the intended lines of traction were recorded for subsequent intra-operative
119 use in orienting the traction wires and radial osteotomy (Figure 2). Two 1.1mm k-wires were pre-
120 contoured to the angles between the intended lines of traction and the distal radial sagittal and
121 frontal plane axes. These wires were sterilised and used to aid intra-operative aiming of the traction
122 wires.
123
124 *Surgical Technique*
125 With the dog positioned in left lateral recumbency, a ~7-mm longitudinal skin incision was made
126 lateral to and directly over the luxated radial head. A 1.6mm stopper wire (IMEX Veterinary Inc,
127 Longview, TX, USA) was positioned at the osteochondral junction immediately adjacent to the lateral
128 extremity of the radial articular surface. Care was taken to ensure that the orientation of this wire
129 closely matched the intended plane of traction. Orientation of the wire relative to the axis of the
130 radial diaphysis was determined according to the pre-operative plan described above. The pre-
131 contoured k-wires were superimposed over the distal radial diaphysis by a surgical assistant. These
132 wires were used to template the orientation of the first traction wire. After drilling of the wire to a
133 point where the stopper was seated against the radial head, the leading end of the stopper wire was
134 mounted through a cannulated fixation bolt to the first hole on an 8 hole 1/3 spinal arch positioned
135 craniomedially (Figure 3A). The trailing edge of the wire was cut short immediately adjacent to the
136 stopper. A second stopper wire was positioned on the radial head 6mm caudodistal to the first wire.
137 This wire was drilled directly towards hole-3 on the 1/3 spinal arch. The intentional slight divergence
138 of the two traction wires in the frontal plane was intended to reduce the potential for stopper wire
139 cutout through the soft bone of the radial head. Care was taken to avoid locating the distal traction
140 wire either through the proximal radial physis or distal to it because traction applied distal to the
141 physis might increase the risk of iatrogenic detachment of the proximal radial epiphysis. The leading
142 and trailing ends of wire 2 were treated in the same way as those of wire 1. Two 70mm linear
143 distraction motors were attached to holes 2 and 5 of the 1/3 spinal arch on its caudal aspect, using 2-
144 hole (from spinal arch hole-2) and 1-hole (from spinal arch hole-5) posts to offset the linear motors
145 from the spinal arch. The linear motors were oriented parallel to the traction wires, and their free
146 ends were mounted on an 84mm internal diameter 19 hole stretch ring positioned caudoproximal to

147 the olecranon process of the ulna (Figure 3B). Three partially end threaded 3mm (Ellis) pins were
148 mounted off the stretch ring using one hole posts coupled with two hole posts to allow freedom of
149 Ellis pin alignment in multiple planes. Two Ellis pins converged onto the olecranon process of the ulna
150 from caudomedial to craniolateral. The third pin (mounted off a 7cm threaded connecting bar
151 coupled with a 2 hole post) was drilled into the proximal ulnar metaphysis from caudolateral to
152 craniomedial (Figures 3A and B).
153
154 A craniolateral approach was made to the proximal radial metaphysis (16). An oblique radial
155 osteotomy was made in a plane parallel to traction wire 1, approximately 8mm distal to wire 2, using
156 a pneumatic microsagittal saw (Microaire, Charlottesville, VA, USA). Acute traction was applied via the
157 linear motors. Tension within the periarticular ligamentous and capsular tissues (in particular the
158 lateral collateral ligament) precluded acute reduction beyond 4mm of craniomedial displacement of
159 the radial head. The surgical incision used to approach the radial osteotomy was closed routinely. No
160 attempt was made to close the skin overlying the stopper ends of the traction wires (Figure 3D).
161 Postoperative radiographs documented appropriate traction wire and osteotomy alignment and
162 satisfactory implant positioning.
163
164 *Post-operative Management*
165 Postoperative analgesia consisted of methadone (0.3 mg/kg intramuscular every 4 hours; Martindale
166 Pharma, Romford, UK) for 24 hours, followed by buprenorphine (0.02 mg/kg intramuscular every 8
167 hours; Reckitt Benckiser Healthcare, Hull, UK) for 48 hours. Carprofen was administered
168 postoperatively at 2 mg/kg orally twice daily for one week, reducing to 2 mg/kg orally once daily for 2
169 weeks thereafter. The pin-skin interface was allowed to form a cutaneous scab, and no pin-skin
170 interface cleaning was adopted. Cage rest and lead-only walking (10 minutes four times daily) were
171 recommended until complete radial head reduction and consolidation of the radial osteotomy was
172 documented. The dog was hospitalized until radial head traction had been discontinued.
173

A 48 hours lag phase was allowed following the 4mm acute intraoperative reduction. This was followed by daily traction at a rate and rhythm of 0.25mm four times per day for 12 days. All external skeletal tractions were performed without chemical restraint and no painful response was noted. Lameness was graded as 8/10 to 10/10 while the external skeletal traction device was in place. After nine days of traction, increasing torque was noted when turning the linear motors. Orthogonal radiographs demonstrated incomplete radial head reduction. The total expected translation distance was 13mm, but actual translation (calculated as the vector of frontal plane translation and sagittal plane translation) approximated 9mm. Premature union of the radial osteotomy was the suspected cause of this discrepancy. Routine general anaesthesia was induced ten days post-operatively and the craniomedial approach to the proximal radius was repeated. A fibro-osseous callus cuff was elevated from the radial ostoetomy site using a sharp periosteal elevator. The radial osteotomy was revised using a sharp osteotome and mallet. The traction wires were acutely tensioned to produce a further 2mm reduction and the surgical wound was closed routinely. Traction was reapplied at a rate of 0.5mm three times daily.

Orthogonal radiographs were obtained every three days after the second surgery. Radiographs obtained six days after the second surgery (16 days after the first surgery) confirmed appropriate reduction of the radial head in both planes. Medial traction was discontinued. The leading end of the most distal of the two stopper wires was detached from the arch and a medial crook was fashioned so that reversal of the direction of traction caused the crook to engage the medial aspect of the radial head (Figure 4). The stopper end of this wire was tensioned by hand in a caudolateral direction and was attached to the caudolateral aspect of the ulnar stretch ring using an Imex SK™ small clamp (IMEX Veterinary Inc, Longview, TX, USA) connected to the ring via a short threaded rod (Figure 5). The proximal stopper wire was tensioned by hand in the opposite direction (the original craniomedial direction of traction) so that the radial head was fixed in position via paired wires tensioned in opposite directions. A consolidation phase of eight days followed, with removal of the traction device under deep sedation a total of 25 days post-operatively. Radiographs taken immediately before implant removal confirmed complete osseous union.

Physical therapy prior to traction frame removal consisted of passive range of elbow motion exercises performed four times daily. This protocol continued for until two weeks after traction frame removal. Hydrotherapy was started one week following traction frame removal, with 10-20 minutes swimming sessions performed three times per week for a further six weeks.

Lameness grade improved rapidly after traction frame removal from 8/10 immediately after ESF removal to 4/10 after two weeks. Lameness continued to improve and was graded as 1/10 at the 3 months reassessment. Comfortable range of elbow motion was equivalent to the contralateral elbow at this time. Radiographs documented maintenance of optimal radial head reduction and remodeling of the radial head towards a more concave appearance (Figure 6). Exercise restriction was relaxed and the dog was allowed unrestricted exercise from four months after surgery. Clinical and radiographic reassessments were performed two years after surgery, and final clinical reassessment was performed three years after surgery. At both assessments, exercise remained unrestricted, and lameness was not reported. Gait exam failed to demonstrate any lameness, although force plate analysis three years post-operatively demonstrated asymmetry in thoracic limb peak vertical force (left 92% of body weight, right 105% of body weight). Mild progression of periarticular osteophytosis was documented radiographically at this time (Figure 7).

DISCUSSION

Developmental canine radial head luxation is a rare condition that lacks a well-defined treatment method with a consistently successful outcome (14). To date, there are only 16 documented cases of the surgical management of congenital or developmental canine radial head luxation (14, 17-19). Although these reports share a surgical goal of restoration of normal elbow joint anatomy, there is considerable variation in surgical technique. To our knowledge, this is the first report describing the

230 gradual reduction of a luxated radial head. In contrast to the majority of affected dogs, there was
231 severe lameness and elbow pain on presentation. Although the severity of clinical signs in this case
232 warranted prompt surgical intervention, the decision-making process for canine radial head luxation
233 is not always straightforward (13). For dogs with mild clinical signs, the primary goal of surgical
234 intervention is essentially prophylactic, and is based on an assumption that the natural history of
235 persistent dislocation will not be benign, and might involve long-term lameness, restricted range of
236 elbow motion, persistent deformity, and progressive osteoarthrosis. Based on a lack of long-term
237 follow up for dogs managed without surgical intervention, the predicted natural progression for radial
238 head luxation remains speculative. Thus, owners should be made aware that there is currently no
239 clear evidence for a beneficial effect of surgical intervention in mildly affected dogs. If surgical
240 intervention is chosen, there is a clear rationale for early intervention (14, 17-19). Chronic radial head
241 luxation leads to changes in the proximal joint surface of the radius (2). This surface, which is normally
242 concave, becomes progressively more convex over time as a result of a lack of contact with an
243 apposing articular cartilage surface. In children managed surgically for chronic posttraumatic radial
244 head luxation, a good prognosis depends upon the presence of a normal concave radial head articular
245 surface, and is not dependent on the age of the patient and duration of the dislocation *per se* (20). In
246 contrast, the case described demonstrated a remarkable capacity for radial head remodeling, a
247 phenomenon which has been documented previously in dogs, and which is reportedly significantly
248 obtunded if treatment is delayed until after 5-6 months of age (21).
249
250 Traction external skeletal fixation management of radial head luxation differs from acute surgical
251 reduction not only in the concept of gradual reduction itself, but also in the principles for
252 maintenance of reduction. Acute surgical radial head reduction requires multiple stages completed
253 within a single procedure; namely, (1) mobilization of the radial head; (2) transposition of the radial
254 head into the appropriate weight-bearing axis; (3) proximal radio-ulnar stabilization, and/or (4)
255 temporary humero-radial stabilization. Mobilization of the radial head involves oblique proximal
256 radial osteotomy as described, or partial (closing wedge) ostectomy (14, 17, 18), with or without
257 partial transection of the interosseous ligament (9). In cases of radial head *sub*-luxation, proximal
258 ulnar osteotomy and partial interosseous ligament transection may be sufficient to allow acute radial

head reduction (9). Transposition of the radial head must be performed with extreme care to avoid iatrogenic detachment of the proximal radial epiphysis, regardless of whether reduction is acute or gradual (13). During traction ESF placement, meticulous attention to detail is required when positioning the stopper wires to avoid distal placement and subsequent bone cutout into the physis. This is best achieved as described by positioning the first traction wire as proximal as possible at the junction between the radial head articular cartilage and the epiphysis. This maximizes the available epiphyseal bone stock so that the distal wire can also be inserted sufficiently proximal to the physis. In normal elbow joints, the medial and lateral collateral ligaments and elbow joint capsule contribute to the functional integrity of the humero-radial joint compartment, and the annular and interosseous ligaments contribute to the integrity of the radio-ulnar joint (1). These structures are usually stretched or torn when radial head luxation occurs, although pathological tension within the interosseous and lateral collateral ligaments can impede radial head reduction (4). In some cases, acute radial head mobilization and reduction may only be possible after transection of the interosseous ligament, leaving a radial head segment that is very unstable after reduction (9). Consequently, the radial head segment must be stabilized internally (or externally as reported herein). This has been most commonly achieved via induced radio-ulnar synostosis using positional screws (17), or via temporary humero-radial stabilization using a trans-articular pin (14, 18). The traction fixator enables gradual plastic deformation of the periarticular ligamentous support, followed by a consolidation phase during which the external fixator maintains radial head reduction whilst periarticular ligamentous remodeling occurs. There are obvious potential advantages to this approach in comparison to either induced radio-ulnar synostosis or the use of a trans-articular pin. Induced synostosis of the radius and ulna is associated with a high risk of progressive elbow incongruity in the rapidly growing dog and should be avoided whenever possible (14). Concerns with trans-articular pin include disruption of the physes, implant fracture or migration, articular cartilage trauma, delayed physiotherapy, and impaired limb growth due to prolonged external coaptation (14). Postoperative physiotherapy is possible during the traction and consolidation phases of traction external fixation, and regular radiographic assessment can prompt subtle adjustments in radial head positioning, neither of which is possible after acute reduction and trans-articular stabilization.

Meticulous pre-operative planning, precise surgical technique and careful post-operative monitoring are critical to the success of gradual radial head traction. In particular, correct alignment of the paired stopper pins is important to ensure an appropriate traction direction. Although sequential postoperative radiographs allow traction frame adjustment in the event of traction malalignment, this complication should be avoidable with proper attention to detail. Optimal rate and rhythm for traction were chosen empirically, with acute traction being applied to the limit of radial head reduction allowed by the periarticular soft-tissues. In this case, premature fibro-osseous union of the radial osteotomy implied underestimation of the ideal traction rate and rhythm. The recommended maximum distraction rate for distraction osteogenesis of 1-1.5mm per day (22) may be inappropriately low when applied to this form of traction fixation. The long oblique osteotomy and distraction plane oriented parallel to the osteotomy plane should produce a large surface area of osseous apposition allowing relatively fast traction rates. It is noteworthy that the calculated and actual traction rates were dissimilar in this case. Many factors may have contributed to this error, including limitations in the accuracy of orthogonal radiography in calculating the traction vector, flexibility of the traction fixator construct itself, and bone cutout of the stopper wires in the soft bone of the radial head. Whilst every case should be approached on an individual basis, based on our experience, we recommend initial acute intraoperative traction to the limits imposed by the periarticular soft tissue envelope. This should be followed by a traction rate and rhythm of 0.5mm four times daily with or without a 48 hours lag period. Although a lag period has been demonstrated to induce more prolific osseous healing when employed prior to distraction osteogenesis (23), it is not an essential precaution (24). Thus, based on our experience of premature osseous union, there may be a potential benefit to avoiding any delays in distraction. Orthogonal radiographs should be obtained every 3 days until optimal radial head reduction is confirmed. While not applied in this case, confirmation of the best possible elbow congruity could be confirmed after implant removal using computed tomography.

In the case described, significant remodeling of the radial head occurred over two months, and excellent pain free elbow function was maintained for three years. Nevertheless, it is important to recognize that obvious coexistent anatomic anomalies were present, including ulnar notch

incongruity and ulnar coronoid process aplasia. Although we agree with previous authors that good results can be achieved with careful assessment of each case and an individualized treatment approach (13-14, 17-19), further study is required to definitively establish the aetiopathogenesis of congenital radial head luxation, and to design an appropriate treatment algorithm for canine radial head luxation. The method described represents a surgical option that allows stabilization of the radial head without compromise of the elbow joint articular cartilage or creation of a radio-ulnar synostosis. Thus, a realistic expectation of this procedure should be the long-term improvement of limb function with reduced pain, rather than the full restoration of athletic function in every operated dog.

336 **REFERENCES**

337 1. Evans HE, Christiensen GC. In: Miller's Anatomy of the Dog 2nd ed. Evans HE, Christiensen GC
338 (eds). Philadelphia: W.B. Saunders Company 1979; 499.
339 2. Kene ROC, Lee R, Bennett D: The radiological features of congenital elbow
340 luxation/subluxation in the dog. J Small Anim Pract 1982; 23: 621-630.
341 3. Campbell JR: Nonfracture injuries to the canine elbow. J Am Vet Med Assoc 1969; 155: 735-
342 744.
343 4. Milton JL, Montgomery RD. Congenital elbow dislocations. Vet Clin N Am 1987; 17: 873-888.
344 5. Miura T: Congenital dislocation of the radial head. J Hand Surg (Br) 1990; 15: 477-481.
345 6. Grondalen J: Malformation of the elbow joint in an Afghan hound litter. J Small Anim Pract
346 1973; 14: 83-89.
347 7. Stevens DR, Sande RD: An elbow dysplasia syndrome in the dog. J Am Vet Med Assoc 1974;
348 165: 1065-1069.
349 8. Bingel SA, Riser WH. Congenital elbow luxation in the dog. J Small Anim Pract 1977; 18: 445-
350 456.
351 9. Gurevitch R, Hohn BR: Surgical management of lateral luxation and subluxation of the canine
352 radial head. Vet Surg 1980; 9: 49-57.
353 10. Skaggs S, DeAngelis MP, Rosen H: Deformities due to premature closure of the distal ulna in
354 fourteen dogs. J Am Anim Hosp Assoc 1973; 9: 496-500.
355 11. Ramadan RO, Vaughan LC: Premature closure of the distal ulnar growth plate in dogs – a
356 review of 58 cases. J Small Anim Pract 1978; 19:647-667.
357 12. Pass MA, Ferguson JG: A review of elbow dislocation in the dog. J Small Anim Pract 1971; 12:
358 327-332.
359 13. Dassler C, Vasseur PB: Elbow luxation. In: Textbook of Small Animal Surgery, 3rd ed. Slatter
360 DG (ed). Philadelphia: W.B. Saunders Company 2003; 1919-1927.
361 14. Clark KJ, Jerram RM, Walker AM: Surgical management of suspected congenital luxation of
362 the radial head in three dogs. New Zealand Vet J 2010; 58: 103-109.
363 15. Impellizeri JA, Tetrick MA, Muir P: Effect of weight reduction on clinical signs of lameness in
364 dogs with hip osteoarthritis. J Am Vet Med Assoc 2000; 216: 1089–1091

16. Piermattei DL, Johnson KA: Approach to the head and proximal metaphysis of the radius. In: An atlas of surgical approaches to the bones and joints of the dog and cat, 4th ed. Piermattei DL, Johnson KA (eds). Philadelphia: W.B. Saunders Company 2004; 242-245.
17. Campbell JR: Congenital luxation of the elbow of the dog. Vet Ann 1979; 19: 229-236.
18. Spadari A, Romagnoli N, Venturini A: A modified Bell-Tawse procedure for surgical correction of congenital elbow luxation in a Dalmatian puppy. Vet Comp Orthop Traumatol 2001; 14: 210-213.
19. Fafard AR: Unilateral congenital elbow luxation in a Dachshund. Can Vet J 2006; 47: 909-912.
20. Seel MJ, Peterson HA: Management of chronic radial head dislocation in children. J Ped Orthop 1999; 19: 306-312.
21. Piermattei DL, Flo GL, DeCamp CE: Congenital lxation of the radial head. In: Brinker, Piermattei and Flo's Handbook of Small Animal Orthopedics and Fracture Repair, 4th ed. Piermattei DL, Flo GL, DeCamp CE (eds). Missouri: Saunders Elselvier 2006; 336-339.
22. Stallings JT, Lewis DD, Welch RD, et al: An introduction to distraction osteogenesis and the principles of the Ilizarov method. Vet Comp Orthop Traumatol 1998; 11: 59-67.
23. Rahal SC, Volpi RS, Vulcano LC: Treatment of segmental tibial defects using acute bone shortening followed by gradual lengthening with circular external fixator. J Vet Med A Physiol Pathol Clin Med 2005; 52: 180-185.
24. McCartney WT: Limb lengthening in three dogs using distraction rates without a latency period. Vet Comp Orthop Traumatol 2008; 21: 446-450.

FIGURE LEGENDS

Figure 1: Orthogonal radiographs of the right elbow joint, including the entire antebrachium. Note the caudolateral luxation of the radial head. Other abnormalities include absence of the coronoid process of the ulna and overt humeroulnar (notch) incongruity. The location and appearance of the distal radial and ulnar growth plates were normal.

Figure 2: Pre-operative planning: The blue lines represent the radial sagittal plane axis (A) and frontal plane axis (B). These axes are plotted through circles centred in the morphologically normal distal half of the radius. The actual and intended locations of the radiographic centre of the radial head are marked in the sagittal (A) and frontal (B) planes using red circles. The red arrows represent the intended lines of traction in the sagittal and frontal planes. It was necessary to estimate the resultant vector intraoperatively to ensure the appropriate direction of traction in three dimensions.

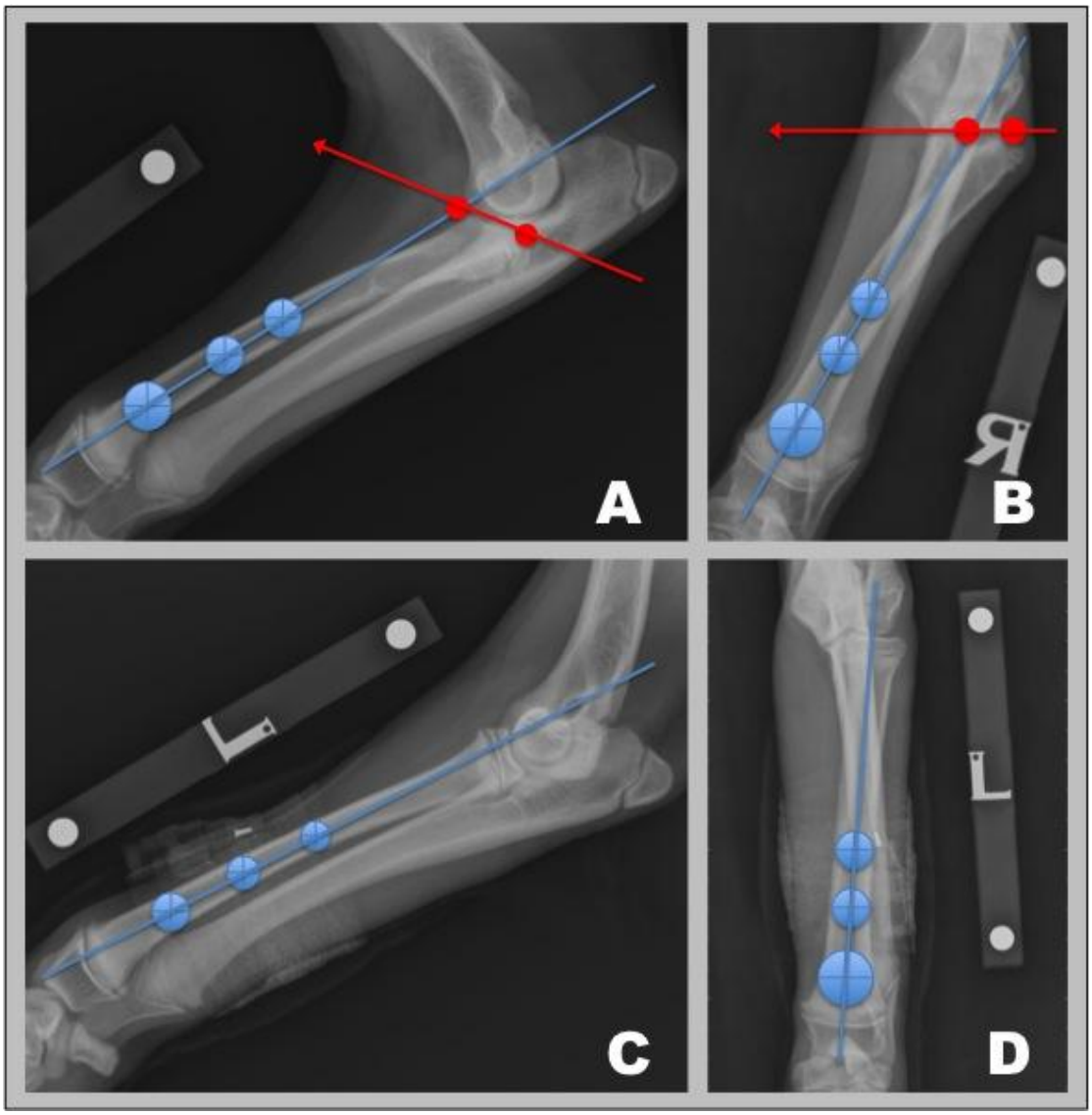

Figure 3: Immediate post-operative radiographs (A, B), schematic image (C) and photograph (D) showing the oblique proximal radial osteotomy and traction ESF. Note the position of the proximal stopper wire at the level of the osteochondral junction. Avoidance of a distal traction wire location either through the physis or distal to it is considered important. Traction applied distal to the physis might increase the risk of iatrogenic detachment of the proximal radial epiphysis. The distal stopper wire was positioned approximately 6mm distal to the proximal wire and proximal to the physis.

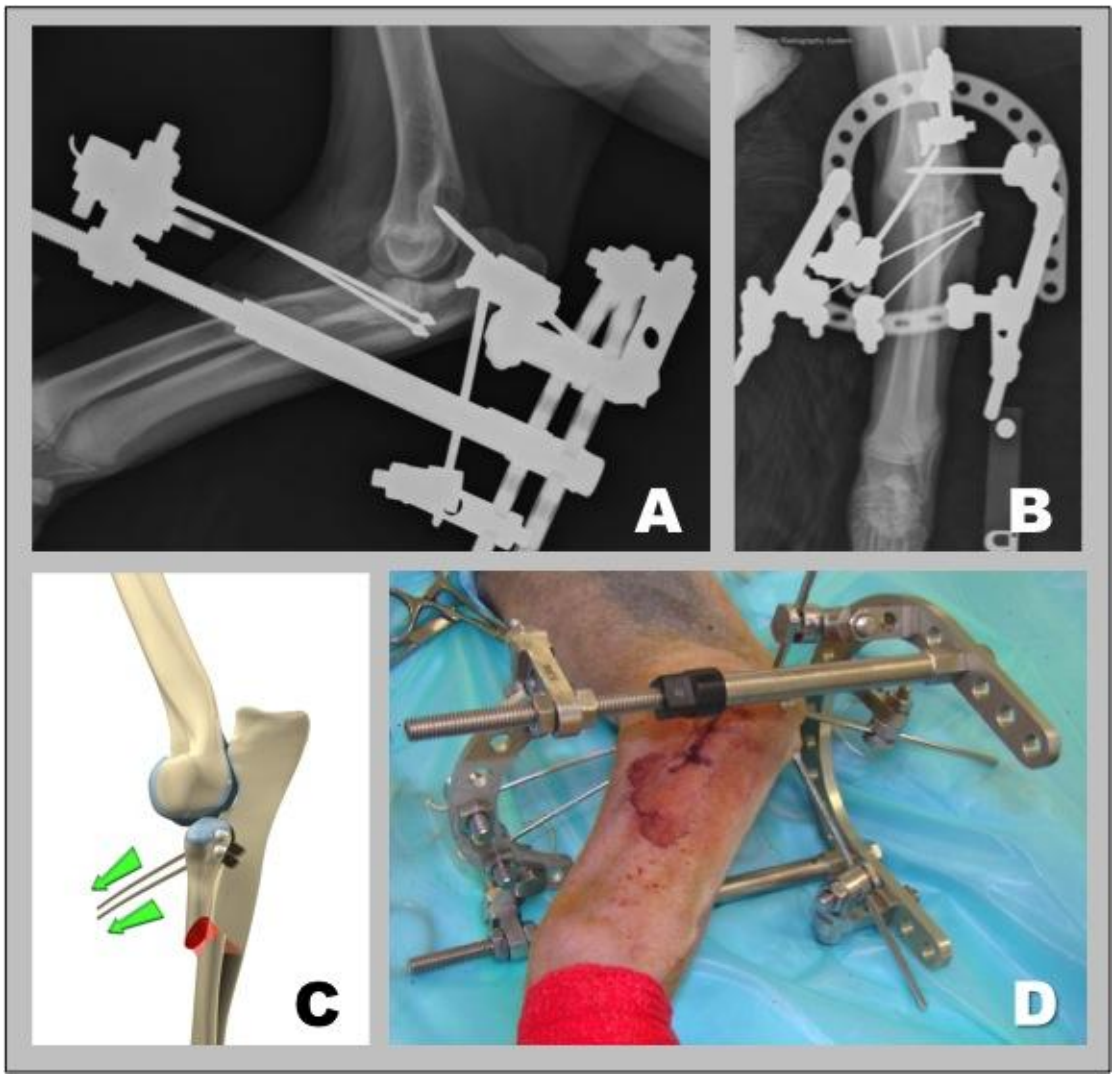

Figure 4: Schematic image demonstrating preparation of the traction wires immediately before the consolidation phase. Radiographs taken 16 days after the initial surgery confirmed appropriate positioning of the radial head. Note that the distal traction wire has been modified by application of a medial crook and reversal of the direction of tension to the wire. The resultant force on the radial head is tension applied in opposite directions in order to provide increased stability of fixation of the radial heal and facilitate rapid consolidation of the fibro-osseous callus.

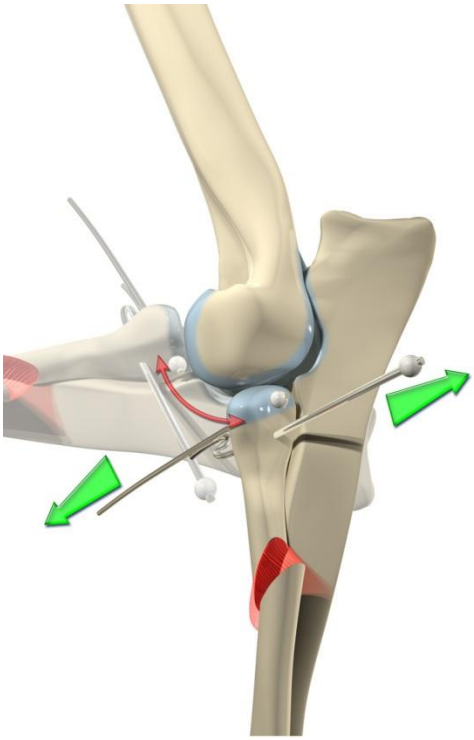

Figure 5: Orthogonal radiographs taken immediately prior to removal of the traction ESF (day 25 after the original surgery): Note that the distal traction wire has a medial crook, which engages the medial cortex when tension is applied to the wire in the opposite direction to tension from the proximal stopper wire.

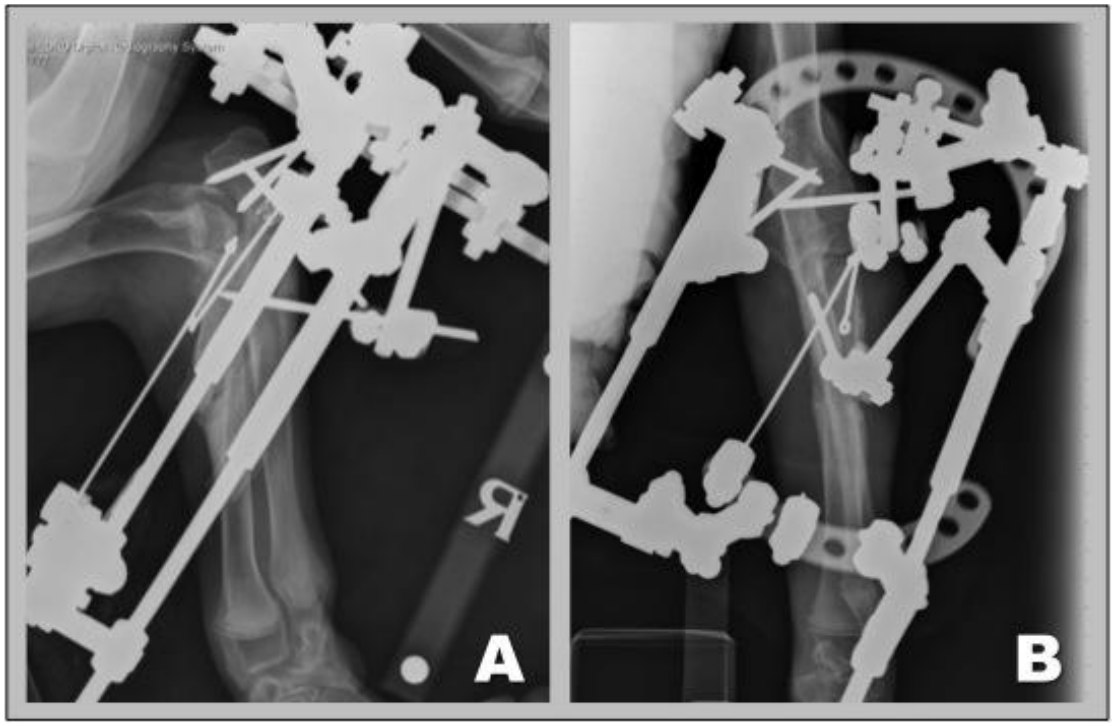

Figure 6: Orthogonal radiographs of the operated right elbow taken four months post-operatively. There has been limited remodeling of the radial head towards a more concave appearance. Humero-ulnar incongruity can still be appreciated, and there is marked subtrochlear sclerosis and moderate periarticular osteophytosis.

Figure 7: Orthogonal radiographs of the operated right elbow taken three years post-operatively. There is mild progression of periarticular osteophytosis.

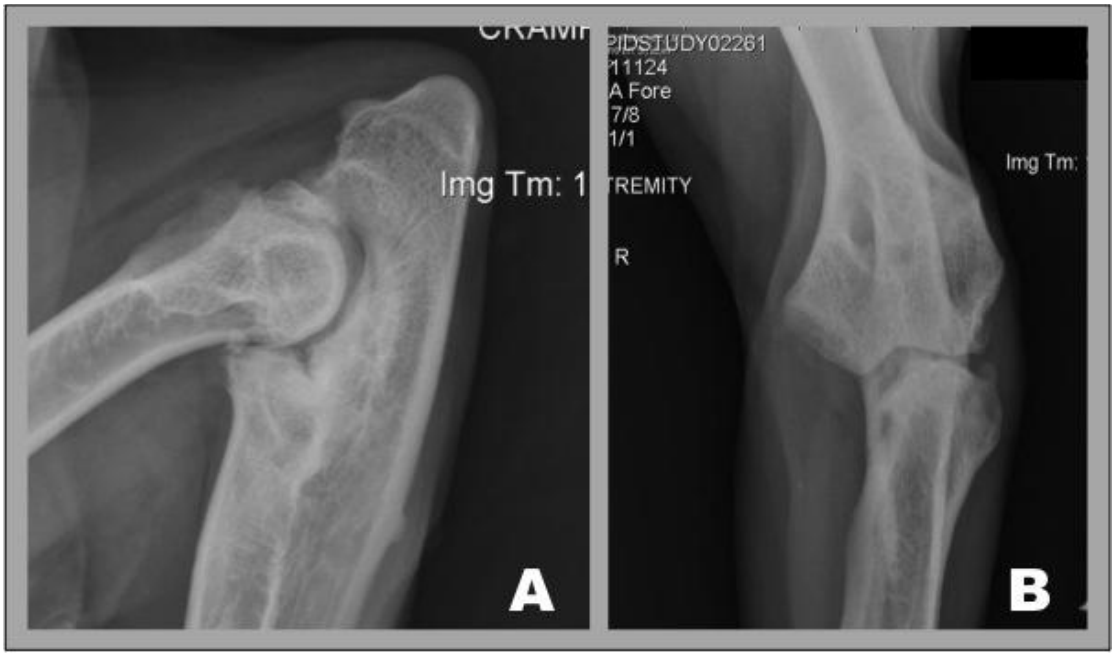

Fitzpatrick Referrals Equipment and Facilities

Anaesthesia & Critical Care

- Piped Anaesthetic Gases – O2 / N20
- Active Scavenge System
- Medical Suction – Piped
- Isoflurane / Sevoflurane Vaporisers
- Surgivet Patient Monitor x 3
- Thames Medical VM-2500 Mainstream Capnograph / Pulse Oximeter
- Graseby 500 Infusion Pump x 6
- Aquapharm Infusion Pump x 10
- Anaesthetic Circuits - Humphrey ADE, T-piece & Circle
- Oxygen Tent
- Patient Thermoregulation – Bair Hugger / 'Hot-Dog'
- Fresh Frozen Plasma – onsite
- Blood transfusion Equipment + donor list
- Thoracostomy tubes
- Feeding tubes

Surgical Equipment of Facillities

- 3 Dedicated orthopaedic theatres
- Karl Storz HD Arthroscopy System
- Sony HD Arthroscopy System
- Microsagittal saw
- High speed burr
- Synthes Collibri Surgical Drill
- Synthes Trauma Reconstruction System Drill
- Mectron Piezosurgery System
- SonicWeld Bone Welding System
- Imex SK ESF Kit
- Mini / Small Kirschner -Ehmer ESF kit
- Cortical/cancellous non self tapping screws
- Plate kits - 1.5/2.0/2.7/3.5mm
- Synthes LCP – 2.0/2.4/2.7/3.5mm
- Synthes TPLO
- Synthes Mini Fragment Set
- Synthes Small Fragment Set
- Orthomed SOP Kit
- Kyon TTA Kit
- NGD Locking System
- NGD Sliding Humeral Osteotomy System
- Range of additional surgical equipment including IM pins, cerclage wire, retractors

Total joint replacement

- Biomedtrix Hybrid Total Hip System
- Biomedtrix Micro Hip Kit
- Biomedtrix Total Stifle Replacement Kit
- Biomedtrix TATE Total Elbow Replacement Kit
- Biomedtrix IOWA Total Elbow Replacement Kit

Post surgical care facilities

- 24 hour nursing
- 24 hour veterinary support
- Dedicated critical care kennels x 2

Rehabilitation

- ACPAT Registered Physiotherapist x 3
- Range of physiotherapy ancillary devices
- Trained Hydrotherapists x 4
- 12m Heated Swimming Pool
- K-Laser (Class 4) Laser Therapy Machine
- Versatron Shock Wave Machine
    - 5mm Probe
    - 20mm Probe

Publications

Fitzpatrick, N,. Yeadon, R., Farrell, M. (2012) Surgical Management of radial head luxation in a dog using an external skeletal traction device. Veterinary and Comparative Orthopaedics and Traumatology, IN PRESS.

Belch, A., Fitzpatrick, N. Farrell, M. (2012) Stifle Arthrodesis in two Cats. Veterinary and Comparative Orthopaedics and Traumatology, 5: 421-426.

Ash, K., Rosselli, D., Danielski, A., Farrell, M., Hamilton, M., Fitzpatrick, N. (2012) Correction of craniodorsal coxofemoral luxation in cats and small breed dogs using a modified Knowles technique with the braided polyblend TightRope™ systems. Veterinary and Comparative Orthopaedics and Traumatology, 1: 54-60.

Fitzpatrick, N., Yeadon, Y., van Terheijden, C., Smith T., (2012) Osteochondral autograft transfer for the treatment of osteochondritis dissecans of the medial femoral condyle in dogs. Veterinary and Comparative Orthopaedics and Traumatology, 1: 135-143.

Silva, H. R., Clements, D., Yeadon, R., Fitzpatrick, N., (2012) Linear-circular external skeletal fixation of intra-condylar humeral fractures with supracondylar comminution in four cats. Veterinary and Comparative Orthopaedics and Traumatology, 1: 61-66.

Fitzpatrick, N., Nikolaou, C., Yeadon, R. and Hamilton, M. (2012), String-Of-Pearls Locking Plate and Cerclage Wire Stabilization of Periprosthetic Femoral Fractures after Total Hip Replacement in Six Dogs. Veterinary Surgery, 41: 180–188.

Fitzpatrick, N., Bielecki, M., Yeadon, R. and Hamilton, M. (2012), Total Hip Replacement with Dorsal Acetabular Rim Augmentation Using the SOP™ Implant and Polymethylmethacrylate Cement in Seven Dogs with Dorsal Acetabular Rim Deficiency. Veterinary Surgery, 41: 168–179.

Fitzpatrick, N., Pratola, L., Yeadon, R., Nikolaou, C., Hamilton, M. and Farrell, M. (2012), Total Hip Replacement after Failed Femoral Head and Neck Excision in Two Dogs and Two Cats. Veterinary Surgery, 41: 136–142

Fitzpatrick, N., Smith, T. J., Pendegrass, C. J., Yeadon, R., Ring, M., Goodship, A. E. and Blunn, G. W. (2011), Intraosseous Transcutaneous Amputation Prosthesis (ITAP) for Limb Salvage in 4 Dogs. Veterinary Surgery, 40: 909–925.

Fitzpatrick N, Nikolaou C, Farrell M, Perry K, Girling S, Smith T, Yeadon R (2011) The double arch modified type 1b external skeletal fixator: technique description and functional outcome for surgical management of canine antebrachial growth deformities. Veterinary Comparative Orthopaedics and Traumatology, 5: 374-382.

Fitzpatrick, N., Riordan, J. O., Smith, T. J., Modlinska, J. H., Tucker, R. and Yeadon, R. (2011), Combined Intramedullary and External Skeletal Fixation of Metatarsal and Metacarpal Fractures in 12 Dogs and 19 Cats. Veterinary Surgery, 40: 1015–1022.

Fitzpatrick, N., Van Terheijden, C., Yeadon, R. and Smith, T. J. (2010), Osteochondral Autograft Transfer for Treatment of Osteochondritis Dissecans of the Caudocentral Humeral Head in Dogs. Veterinary Surgery, 39: 925–935.

Perry K, Fitzpatrick N, Johnson J, Yeadon R (2010) Headless Self-Compressing Cannulated Screw Fixation for Treatment of Radial Carpal Bone Fracture/Fissure in dogs. Veterinary Comparative Orthopedics and Traumatology, 2: 94-101.

Fitzpatrick, N. and Solano, M. A. (2010), Predictive Variables for Complications after TPLO with Stifle Inspection by Arthrotomy in 1000 Consecutive Dogs. Veterinary Surgery, 39: 460–474

Fitzpatrick, N., Johnson, J., Hayashi, K., Girling, S. and Yeadon, R. (2010), Tibial Plateau Leveling and Medial Opening Crescentic Osteotomy for Treatment of Cranial Cruciate Ligament Rupture in Dogs with Tibia Vara. Veterinary Surgery, 39: 444–453

Burton NJ, Perry MJ, Fitzpatrick N, Owen MR: Comparison of bone mineral density in medial coronoid processes of dogs with and without medial coronoid process fragmentation. AJVR (71) 1: January 2010.

Fitzpatrick, N. and Yeadon, R. (2009), Working Algorithm for Treatment Decision Making for Developmental Disease of the Medial Compartment of the Elbow in Dogs. Veterinary Surgery, 38: 285–300.

Fitzpatrick, N., Yeadon, R., Smith, T. and Schulz, K. (2009), Techniques of Application and Initial Clinical Experience with Sliding Humeral Osteotomy for Treatment of Medial Compartment Disease of the Canine Elbow. Veterinary Surgery, 38: 261–278.

Smith TJ, Fitzpatrick N. (2009) Tibial Plateau Levelling Osteotomy in an alpaca. Veterinary Comparative Orthopedics and Traumatology, 4: 332-335.

Fitzpatrick, N., Smith, T. J., Evans, R. B., O'Riordan, J. and Yeadon, R. (2009), Subtotal Coronoid Ostectomy for Treatment of Medial Coronoid Disease in 263 Dogs. Veterinary Surgery, 38: 233–245

Fitzpatrick, N., Smith, T. J., Evans, R. B. and Yeadon, R. (2009), Radiographic and Arthroscopic Findings in the Elbow Joints of 263 Dogs with Medial Coronoid Disease. Veterinary Surgery, 38: 213–223

Fitzpatrick, N., Yeadon, R. and Smith, T. J. (2009), Early Clinical Experience with Osteochondral Autograft Transfer for Treatment of Osteochondritis Dissecans of the Medial Humeral Condyle in Dogs. Veterinary Surgery, 38: 246–260

Smith, T. J., Fitzpatrick, N., Evans, R. B. and Pead, M. J. (2009), Measurement of Ulnar Subtrochlear Sclerosis Using a Percentage Scale in Labrador Retrievers with Minimal Radiographic Signs of Periarticular Osteophytosis. Veterinary Surgery, 38: 199–208

Fitzpatrick, N., Smith, T. J., O'Riordan, J. and Yeadon, R. (2009), Treatment of Incomplete Ossification of the Humeral Condyle with Autogenous Bone Grafting Techniques. Veterinary Surgery, 38: 173–184.

Smith TJ, Fitzpatrick N: Surgical removal of a microchip from a puppy's spinal canal. Veterinary Comparative Orthopedics and Traumatology 22(1): 63-65, 2009

Fitzpatrick N, Lewis D, Cross A: A biomechanical comparison of external skeletal fixation and plating for the stabilization of ilial osteotomies in dogs. Veterinary Comparative Orthopedics and Traumatology 21(4): 349-357, 2008

Clements DN, Fitzpatrick N, Carter SD, Day PJ: Cartilage gene expression correlates with radiographic severity of canine elbow osteoarthritis. Veterinary Journal 179(2):211-218, 2009

Kirkby KA, Lewis DD, Lafuente MP, Radasch RM, Fitzpatrick N, Farese JP, Wheeler JL, Hernandez JA: Management of humeral and femoral fractures in dogs and cats with linear- circular hybrid external skeletal fixators. Journal of the American Animal Hospital Association 44(4): 180-197, 2008

Fitzpatrick N and Yeadon R: Algorithm for treatment of developmental diseases of the medial elbow in dogs. Irish Veterinary Journal 61(6): 398-401, 2008

Innes J, Pettitt R, Comerford E, Fitzpatrick N (2007) Total knee replacement for dogs (Letter to the editor). Veterinary Record 160(9): 312.

Danielson, K. C., Fitzpatrick, N., Muir, P.,Manley, P. A. (2006), Histomorphometry of Fragmented Medial Coronoid Process in Dogs: A Comparison of Affected and Normal Coronoid Processes. Veterinary Surgery, 35: 501–509.

Abstract Presentations

Veterinary Orthopedic Society, Colorado, USA March 2009

Fitzpatrick N, Evans K, Yeadon R: Synthetic Osteochondral Transplant for Treatment of OCD of the Canine Elbow, Stifle, and Shoulder with Arthroscopic and RI Outcome Measures

Fitzpatrick N, Danielski A: Biceps Ulnar Release Procedure for Treatment of Medial Coronoid Disease in 49 elbows

Veterinary Orthopedic Society, Colorado, USA March 2010

Fitzpatrick N; Danielski A: Validation of lumbosacral neuroforaminal distraction in dogs using a novel intervertebral spacer and mri mensuration instruments – a cadaveric pilot study

Fitzpatrick N; Danielski A: Long-term follow-up of lumbosacral distraction-fusion using combined dorsal and ventral fixation including a novel intervertebral spacer device (23 dogs)

Fitzpatrick N, Nikolaou C: True spherical dome osteotomy for acute correction of sagittal and frontal joint axes in dogs with angular and rotational antebrachial deformities (11 limbs)

European College of Veterinary Surgeons symposium, Helsinki, Finland, July 2010

Danielski A, Fitzpatrick N: Validation of Lumbosacral Neuroforaminal Distraction in Dogs Using a Novel Intervertebral Spacer and MRI Mensuration Instruments – A Cadaveric Pilot Study

World Veterinary Orthopaedic Conference Bologna, Italy, September 2010

Fitzpatrick N: Pantarsal arthrodesis in 10 cats using a novel dorsal plate: technique and complications

Fitzpatrick N: Minimally Invasive Plate Osteosynthesis Using Two Perpendicularly Oriented Plates for the Treatment of Tibial Fractures in 23 Cats

American College of Veterinary Surgeons Symposium, USA, 2010

Fitzpatrick N, Ash K: Constrained total knee replacement, a novel prosthesis for salvage arthroplasty in the dog and cat

Fitzpatrick N, Ash K: Novel modular limb salvage endoprostheses for treatment of primary appendicular tumors in dogs

Fitzpatrick N, Yeadon R. Ash K: Synthetic osteochondral transplant for treatment of osteochondritis dissecans of the canine elbow, stifle, and shoulder with arthroscopic and MRI outcome measures

Veterinary Orthopedic Society, USA March 2011

Nikolaou C, Fitzpatrick N, Isaza J, Correa Velez S, Wavreille V, Ash K, Ochoa J, ,: The effect of configuration and radiographic positioning on measurements of deformity magnitude in a dog with a complex antebrachial growth deformity: comparison between radiographic and 3D computer modelling measurements

Fitzpatrick N, Nikolaou C, Ochoa JJ, Isaza JF, Correa Velez S, Wavreille V, Ash K, Wavrielle, Szanto Z,: True spherical dome osteotomy using a novel blade design in a dog with antebrachial growth deformity

Fitzpatrick N, Ash K, Blunn GW: Application of Novel Endo- and Exo-Prostheses to the Calcaneus of the Dog and Cat following Distal Limb Amputation.

European College of Veterinary Surgeons symposium, Ghent, Belgium, July 2011

Nikolaou C, Fitzpatrick N, Wavreille V, Ash K, Ochoa J, Isaza J, Correa Velez S: The effect of configuration and radiographic positioning on measurements of deformity magnitude in a dog with a complex antebrachial growth deformity: comparison between radiographic and 3D computer modeling measurements

Fitzpatrick N, Bielecki M, Yeadon R, Hamilton M:Total Hip Replacement with Dorsal Acetabular Rim Augmentation using the SOP™ Implant and Polymethylmethacrylate Cement in Seven Dogs with Dorsal Acetabular Rim Deficiency

Fitzpatrick N, Nikolaou C, Isaza J, Correa Velez S, Wavreille V, Ash K, Szanto Z, Ochoa J: True spherical dome osteotomy using a novel blade design in a dog with antebrachial growth deformity: Planning and Execution of Technique

American College of Veterinary Surgeons Symposium, USA, 2011

Abstracts:

Fitzpatrick N, Caron A, Wavrille V: Bi-oblique dynamic proximal ulnar osteotomy: surgical technique, computed tomographic assessment of radio-ulnar congruency over 12 weeks and clinical outcome in 87 dogs

Fitzpatrick N, Garcia-Nolen TC, Daryani A, Watari S, Hayashi K: Structural analysis of canine medial coronoid disease by micro CT: radial incisure versus tip fragmentation

Sajik D, Fitzpatrick N, Nikolaou C: Pantarsal arthrodesis in dogs: a clinical comparison of dorsal vs medial plate techniques without coaptation

Fitzpatrick N, Bertran J: Sliding humeral osteotomy: Reduction of major complication rate to zero and clinical outcome equivalence with or without focal coronoid treatment

Veterinary Orthopedic Society, Colorado, USA March 2012
Fitzpatrick N, Egan P: Treatment of canine talar osteochondritis dissecans using a synthetic osteochondral substitute

Fitzpatrick N, Egan P, Pugliese L: Custom built uniplanar constrained total knee repacement in the canine and feline: clinical applications, design principles, surgical technique and clinical outcome

Wucherer KL, Fitzpatrick N, Conzemius MG: A Prospective, Randomized Clinical Trial Evaluating the effect of Proximal Ulnar osteotomy for the Treatment of a Fragmented Medial Coronoid Process in the Dog.

Fitzpatrick N, Solano M: Application of a novel osteointegration screw for treatment of incomplete ossificaiton of the humeral condyle in four dogs (six elbows) and humeral unicondylar fracture in addition to a locking plate in four elbows.

Sparrow T, Fitzpatrick N: Total shoulder arthroplasty in a canine for treatment of severe glenohumeral arthrosis
Fitzpatrick N, Nikolaou C, Ochoa J, Isaza J, Velez SC: Planning and Executing DOME Osteotomy: Implications for CORA Methodology

Farrell M, Heller J, Kowaleski M, Sparrow T, Solano M: Fitzpatrick N: Does radiographic arthrosis correlate with cartilage disease in Labrador Retrievers affected by medial compartment disease of the elbow joint?

Sparrow T, Fitzpatrick N: Shoulder hemiarthroplasty for treatment of severe osteochondritis dissecans lesion located on the humeral head in a dog

BSAVA Congress Birmingham UK April 2012
Caron A, Fitzpatrick N: Cranial cruciate ligament rupture in dogs: lateral fabello-tibial suture failure and revision by tibial plateau levelling osteotomy, 59 cases

Fitzpatrick N, Caron A: Bioblique dynamic proximal ulnar osteotomy: computed tomographic assesssment of radio-ulnar incongruency over 12 weeks in 29 elbows

Fitzpatrick N, Bertran J: Sliding humeral osteotomy: reduction of major complication rate to zero and clinical outcome equivalence with or without focal coronoid treatment

Caley A, Fitzpatrick N, Caron A: Kinematic gait analysis of the thoracic limb of normal dogs and patients with confirmed medial compartment disease using a six degrees of freedom marker set: 13 cases

Law A, Fitzpatrick N: Total hip replacement in dogs 6 to 10 months of age – case series of 20 dogs

Sajik D, Fitzpatrick N: Canine partial tarsal arthrodesis using a lateral type 1 ESF with a tied-in intramedullary calcaneal pin: 9 cases

Fitzpatrick N, Egan P: Treatment of canine talar osteochondritis dissecans using a synthetic osteochondral substitute

Sajik D, Fitzpatrick N: Pantarsal arthrodesis of the feline hock using a novel dorsal plate design applied according to the principles of minimally invasive plate osteosynthesis: 11 cases

Solano M, Fitzpatrick N: Cervical distraction and stabilization using a novel intervertebral spacer and 3.5mm string-of-pearl (sop™) plates for dogs affected by disc associated wobbler syndrome (daws) in 16 dogs

Diribe O, Fitzpatrick N: Development of rapid Point-of-Care diagnostic tests for the detection of bacteria implicated in surgical site infections and the determination of their antibiotic resistance profile

Fitzpatrick N, Bertran J: Long-term clinical outcome after subtotal coronoid ostectomy (SCO): retrospective study in 68 dogs

Caron A, Fitzpatrick N: Bioblique dynamic proximal ulnar osteotomy: surgical technique and clinical outcome in 98 elbows

De Sousa R, Farrell M, Fitzpatrick N: Simultaneous repair of bilateral medial patellar luxation: Clinical outcome and complications in 21 dogs and 5 cats

Fitzpatrick N, Egan P: Use of a prosthetic trochlear groove for the surgical management of patellar luxation in 3 dogs

Hamilton M, Belch A, Fitzpatrick N: Three cases of patellar tendon repair using canine fascia allograft

Caley A, Fitzpatrick N, Caron A: Kinematic gait analysis of the thoracic limbs of normal dogs using a six degrees of freedom marker set

Fitzpatrick N, Kovach K: Pedicle screw-rod construct with multi-directional clamps for stabilisation of vertebral instability in discospondylitis

European College of Veterinary Surgeons symposium, Barcelona, Spain, July 2012
Fitzpatrick N, Solano M: Application of a novel osteintegration screw for treatment of incomplete ossification of the humeral condyle in four dogs (six elbows) and humeral unicondylar fracture in addition to a locking plate in four elbows

American College of Veterinary Surgeons Symposium, USA, November 2012
Bertran J, Knapik GG, Marras WS, Fitzpatrick N, Allen MJ : Comparison of optical white light scanning and computed tomography for the generation of 3d models of the canine cervical spine

Bertran J, Fitzpatrick N, Allen MJ: Non-invasive measure of bone density to predict mechanical properties of the vertebral endplate in the canine cervical spine

Invited Lectures

VA3 Conference, Naples, Florida, USA, August 2009

Osteochondral Autograft Transfer System (OATS) and Synthetic Osteochondral Core (SOC) for treatment of OCD
Biceps Ulnar Release Procedure – technique and application

American College of Veterinary Surgeons Symposium, USA, 2009
Algorithm for Management of Medial Compartment Disorders of the Canine Elbow
Algorithm for Management of Antebrachial Growth Deformity in Dogs

American College of Veterinary Surgeons Symposium, USA, 2010
New Horizons for Feline Appendicular Trauma
New Horizons for Feline Joint Surgery
Distraction – Fusion for Canine Lumbo-sacral Disease

Norwegian Small Animal Veterinary Association, Tromso, Norway, April 2010
Antebrachial growth deformities
Caudal cervical spondylomyelopathy and lumbosacral disease
Algorithm of treatment for elbow dysplasia
Advances in external skeletal fixation
Feline trauma – new insights
Hip Dysplasia
Disease of the canine stifle

Australian Surgery Chapter Gold Coast Australia June 2010
Pelvic fractures – is a cat like a small dog?
New horizons – Feline coxofemoral, stifle and elbow joint including the feline hip – from medical management to surgical salvage and beyond
Elbow and stifle disease – from disruption to salvation and everything in between
SPIDER for metacarpal and metatarsal fractures and luxations. Are pins better than plates?
Overview of algorithm for management of antebrachial growth deformity in dogs. Including the DRAPPER frame and DOME osteotomy
Application of a variably pitched cannulated screw and bioblique dynamic ulnar osteotomy for treatment of ununited anconeal process in Dogs
Treatment of ossification of the humeral condyle and recalcitrant elbow fractures
New thoughts on repair and salvage of the capus and metacarpus – Acutrak, DCOI, PAWS
New thoughts on repair and salvage of the tarsus and metatarsus
Algorithm for management of medial compartment disorders of the canine elbow

- Aetiopathogenic postulates of developmental elbow disease
- Treatment algorithm for DED – SCO, BURP, PUO
- Treatment algorithm for DED – OC implants, autogenous and synthetic
- Current concepts in management of DED – SHO
- Experiences with TATE and Iowa TER

VA3 Conference, Naples, Florida, USA, August 2010
Biceps Ulnar Release Procedure – Clinical Update

World Veterinary Orthopaedic Conference Bologna, Italy, September 2010
How would I treat MCD?
Sliding Humeral Osteotomy: current status and complications
Novel modular limb salvage endoprosthesis for treatment of primary appendicular tumours in dogs: short term outcome
Constrained Total Knee Replacement, a novel prosthesis for salvage arthroplasty in the dog and cat
Long term follow-up of lumbosacral distraction-fusion using combined dorsal and ventral fixation including a novel intervertebral spacer device
Challenging elbow fractures
Developmental elbow disease – algorithm of decision making
Endoprostheses for limb salvage
Sliding humeral osteotomy
Lumbosacral distraction fusion for lumbosacral disease in dogs
Constrained total knee replacement
Wierd fracture treatment

British Veterinary Association, Glasgow, Scotland, September 2010
Treatment too far – a challenge for the veterinary profession

American College of Veterinary Surgeons Symposium, USA, October 2010
External Skeletal Fixation for Pelvic Fractures
New Horizons for feline joint surgery
New horizons for feline appendicular trauma

BSAVA Congress, Birmingham, UK, March 2011
Canine bone tumours – the ethics of limb sparing

Southern European Veterinary Congress, Barcelona, Spain, April 2011
Complex elbow fractures
Hip dysplasia
Developmental elbow disease
Complex fracture repair

British Small Animal Veterinary Association, Belfast, Northern Ireland, May 2011
Hip dysplasia
Lumbosacral disease and cervical spondylomyelopathy

Canine stifle disease
Limb salvage with ensoprostheses
Feline joint disease
Feline appendicular trauma
Algorithm for treatment of developmental elbow disease
Pelvic fractures in cats and dogs

British Veterinary Nursing Association, Belfast, Northern Ireland, May 2011
Nursing Frustrations of orthopaedics and neurosurgery

Polish Small Animal Veterinary Association, Warsaw, Poland, June 2011
Feline Appendicular Trauma
Developmental Elbow Disease
Hip Dysplasia – to cut or not to cut
Cruciate Disease, an overview

Royal Society of Medicine, London UK, June 2011
Medical Innovations – Bionics

VA3 Conference, Naples, Florida, USA, August 2011
Biceps Ulnar Release Procedure – Arthroscopic Technique
Synthetic Osteochondral Substitute: Technique and Outcome

British Veterinary Nursing Association, Chester, UK, October 2011
Nursing Frustrations of orthopaedics and neurosurgery

University College Dublin Student Annual Lecture, Dublin, Ireland October 2011
New Horizons in Orthopaedics and Neurosurgery

American College of Veterinary Surgeons Symposium, USA, 2011
Subtotal coronoid ostectomy: Indications and Outcome
Cervical, Thoracolumbar and Lumbosacral Spine: Novel Internal Fixation Devices
Spinal Fractures and Lumbosacral Disease in Cats: Pins and PMMA
The FITS – Fitz Intervertebral Traction Screw
Bone and Tendon –Ingrowth prosthesis
Decision making in Cranial Cruciate Ligament Disease

London Veterinary Show, London, UK, November 2011
Osteoarthritis – medical and surgical management

University of Surrey, UK, January 2012
Where is your career going?

University of Leipzig sponsored German Small Animal Veterinary Congress, January 2012
Endo and exo-prostheses for limb salvage

Total joint replacement vs arthrodesis

Royal College of Veterinary Surgeons Students forum, Hatfield, UK, February 2012
Conventional and Bionic options for Joint surgery

The Ohio State University Grand Rounds, Columbus Ohio, March 2012
Going Out on a Limb – New Concepts for Joint and Limb Surgery

Wentworth Medical Memorial lecture March 2012
Knee Surgery – a veterinary perspective

Technology and Innovation in Medical Sciences, Imperial College, London, UK, March 2012
One Life One Medicine: A New Paradigm: Cross-species innovation and translation

British Veterinary Orthopaedic Association, Birmingham, UK, April 2012
Sliding humeral osteotomy

Royal College of Veterinary Surgeons Students forum, Hatfield, UK, May 2012
Innovation in Clinical Veterinary Practice: what is the cost of change?

Orthofun Conference, Rome, Italy May 2012
Antebrachial growth deformities including DOME osteotomy
Arthrodesis vs Joint Replacement
Complex Elbow Fractures and IOHC
Complex Total Hip replacement
Developmental Elbow Disease
Endo- and Exo- prostheses for limb salvage
Trauma to the feline appendicular skeleton
Feline Joint disease – Trauma and arthroplasty
Fitz intervertebral spacer screw for lumbar and cervical spinal fusion

University of Surrey, UK, May 2012
Innovations Forum **-** A Reason Big enough

British Small Animal Veterinary Association, Devon, UK, June 2012
Spinal disease – myths and misconceptions

UKRad Annual Conference, Manchester, UK, June 2012
What Man can learn from a dog: Cross-species innovation and translation
Advanced imaging of the Canine Skeleton

University of Surrey, UK, July 2012
The Art of Science

European College of Veterinary Surgeons symposium, Barcelona, Spain, July 2012

TTA/MMT in cats
Multiligamentous Stifle Injuries
Bone, tendon and skin ingrowth prostheses for limb salvage

European Society of Veterinary Orthopaedics and Traumatology, Bologna, Italy, September 2012
Introduction of a novel osteo-inductive tubular fixation device for treatment of IOHC and HIF; elbow fractures in cats
Algorithm of treatment for severe elbow dysplasia
Arthrodesis versus novel joint replacement of the shoulder, elbow, stifle and hock in cats and dogs
New approaches to old problems in feline joint, long bone and spinal trauma
Challenging fractures, non-unions and revision surgeries including elbow and pelvis in cats and small dogs
THR for trauma – innovative strategies
THR in small breed dogs and cats
Application of CT and computer assisted planning for growth deformity correction using true spherical dome osteotomy
Arthrodesis or repair versus limb salvage with endo and exo-prostheses for distal limb injuries in cats and dogs
The development of novel rapid DNA based diagnostic microbiology tools to study the epidemiology of bacterial infections in referral practice

VA3 Conference, Naples, Florida, USA, August 2012
Application of a novel osteointegration screw for treatment of humeral intracondylar fissure and humeral unicondylar fracture in dogs
Medial Compartment disease of the canine elbow – classification
Synthetic osteochondral resurfacing (SOCR) in canine OCD

Paley Institute Lecture, West Palm Beach, Florida, USA August 2012
Amputation and prostheses in dogs and cats

Italian Companion Animal Veterinary Association, Bologna, Italy, September 2012
Arthrodesis, repair and prostheses for distal limb trauma
New approaches to feline joint, bone and spinal problems

NHS Educational Trust. Advancements in Medical Training Conference . Bristol, UK, Sept 2012
Translation of Veterinary Surgery to Human Practice

American College of Veterinary Surgeons Symposium, USA, November 2012
Lower Extremity Trauma - Novel Solutions
Limb Sparing – expert panel

CPD Courses at Fitzpatrick Referrals

Diseases of the canine stifle – Oct 2009
Diseases of the canine and feline spine – Sept 2011
Joint Replacement – June 2011

Advanced veterinary imaging – how can ADI help your practice? – July 2011
Medivet Regional Conference – Developmental Elbow Disease - Jan 2012
Limb salvage – Mar 2012

Instructional Courses

American College of Veterinary Surgeons Symposium
Sliding Humeral Osteotomy 2008, 2009, 2010, 2011

Fitzpatrick Referrals, Surrey UK
Sliding Humeral Osteotomy 2009, 2010, 2011

British Veterinary Nursing Association, Edinburgh, Scotland, January 2010
External skeletal fixation – from basic to advanced
Stifle Surgery – from basic to advanced

Animal Medical Centre, Barcelona, Spain, August 2011
Sliding Humeral Osteotomy

European College of Veterinary Surgeons symposium, Barcelona, Spain, July 2012
Tibial Plateau Leveling Osteotomy – complications
Tibial Plateau Leveling Osteotomy – meniscal injuries

Book Chapters

Complication in Small Animal Surgery
(Editor: Dominique Griffon)
Complications associated with autogenous osteochondral repair – Fitzpatrick N & Egan P
Complications of sliding humeral osteotomy – Fitzpatrick N & Bertran J

Advances in Intervertebral Disc Disease in Dogs and Cats
(Editors: James Fingeroth and William Thomas)
Is wobbler disease related to disc disease? – Fitzpatrick N, Farrell M, Fingeroth J & Fauber A
Lumbosacral disease: Is vertebral stabilization indicated? - Farrell M & Fitzpatrick N
Feline intervertebral disc disease - Farrell M & Fitzpatrick N